



Standards and datasets for reporting cancers

Dataset for the histopathological reporting of thyroid cancer

August 2023

Authors: Dr David N Poller, Queen Alexandra Hospital, Portsmouth
Dr Sarah J Johnson, Newcastle upon Tyne Hospitals NHS Foundation Trust
Dr Mufaddal T Moonim, Imperial College Healthcare NHS Trust, London
Dr Louise M Smart, Aberdeen Royal Infirmary

Unique document number	G098
Document name	Dataset for the histopathological reporting of thyroid cancer
Version number	5
Produced by	Dr David N Poller, Dr Sarah J Johnson, Dr Mufaddal T Moonim and Dr Louise M Smart. All the authors are consultant cellular pathologists working at the respective NHS trusts listed above, with experience of national and international leadership in the endocrine pathology subspeciality.
Date active	June 2023 (to be implemented within 3 months)
Date for full review	June 2026
Comments	This document will replace the 3rd edition of the <i>Dataset for Thyroid Cancer Histopathology Reports</i> published in 2014. In accordance with the College's pre-publications policy, this document was placed on The Royal College of Pathologists' website for a consultation from 28 June 2023 to 26 July 2023. Responses and authors' comments are available to view on request. Dr Brian Rous Clinical Lead for Guideline Review

The Royal College of Pathologists
6 Alie Street, London E1 8QT
Tel: 020 7451 6700
Fax: 020 7451 6701
Web: www.rcpath.org

Registered charity in England and Wales, no. 261035
© 2023, The Royal College of Pathologists

This work is copyright. You may download, display, print and reproduce this document for your personal, non-commercial use. Requests and inquiries concerning reproduction and rights should be addressed to The Royal College of Pathologists at the above address. First published: 2023.



Contents

Foreword	3
1 Introduction.....	4
2 Clinical information required for the diagnosis of carcinomas of the thyroid	6
3 Receipt and preparation of specimens before dissection	7
4 Specimen handling and block dissection.....	7
5 Core data items	9
6 Non-core data items.....	28
7 Diagnostic coding and staging	30
8 Reporting of thyroid needle core biopsy specimens	31
9 Frozen section diagnosis	31
10 Molecular testing in thyroid tumours.....	32
11 Support of research and clinical trials	35
12 Criteria for audit	35
13 References	36
Appendix A SNOMED coding	45
Appendix B TNM classification of malignant tumours of the thyroid (UICC TNM 8).....	48
Appendix C Reporting proforma for carcinomas of the thyroid	50
Appendix D Reporting proforma for carcinomas of the thyroid in list format	56
Appendix E Summary table – explanation of grades of evidence	61
Appendix F AGREE II guideline monitoring sheet.....	62



NICE has accredited the process used by The Royal College of Pathologists to produce its cancer datasets. Accreditation is valid for 5 years from 25 July 2017. More information on accreditation can be viewed at www.nice.org.uk/accreditation.

For full details on our accreditation visit: www.nice.org.uk/accreditation.

Foreword

The cancer datasets published by The Royal College of Pathologists (RCPATH) are a combination of textual guidance, educational information, and reporting proformas. The datasets enable pathologists to grade and stage cancers in an accurate, consistent manner in compliance with international standards and provide prognostic information thereby allowing clinicians to provide a high standard of care for patients and appropriate management for specific clinical circumstances. This guideline has been developed to cover most common circumstances. However, we recognise that guidelines cannot anticipate every pathological specimen type and clinical scenario. Occasional variation from the practice recommended in this guideline may therefore be required to report a specimen in a way that maximises benefit to the patient.

Each dataset contains core data items (see Appendices C and D). Core data items are those that are supported by robust published evidence and are required for cancer staging, optimal patient management and prognosis. Core data items meet the requirements of professional standards (as defined by the Information Standards Board for Health and Social Care [ISB]) and it is recommended that at least 95% of reports on cancer resections should record a full set of core data items. Other, non-core, data items are described. These may be included to provide a comprehensive report or to meet local clinical or research requirements. All data items should be clearly defined to allow the unambiguous recording of data.

The following stakeholders were contacted to consult on this document:

- The British Association of Endocrine and Thyroid Surgeons (BAETS)
- The British Thyroid Association
- ENT-UK
- The UK Endocrine Pathology Society
- The UK and Ireland Association of Cancer Registries
- National Cancer Registration and Analysis Service.

Comments from specialists and general histopathologists on the draft document that was published on the Royal College of Pathologists website have been considered as part of the review of the dataset.

The information used by the authors to develop this dataset was obtained by undertaking a 5-year search of the PubMed database for relevant primary research evidence and systematic reviews including the search terms 'thyroid', 'cancer' and 'pathology' from 9 November 2016 to 5 September 2022 (inclusive). The recommendations incorporate the core data items and commentary from the International Collaboration on Cancer Reporting (ICCR),¹ with relevant edits as required by the updated 5th edition of the WHO Classification of Endocrine and Neuroendocrine Tumours, published in April 2022.² The level of evidence for the recommendations has been summarised according to modified SIGN guidance (see Appendix E) and the grade of evidence is indicated in the text. No major conflicts in the evidence have been identified and minor discrepancies between studies have been resolved by expert consensus. Any gaps in the evidence were identified by College members via feedback received during consultation.

No major organisational changes or cost implications have been identified that would hinder the implementation of the dataset.

All cancer datasets are formally revised every 3 years. However, each year, the College will ask the author of the dataset, in conjunction with the relevant sub-specialty adviser to the College to consider whether, or not the dataset needs to be updated or revised. A full consultation process will be undertaken if major revisions are required. Revisions to core data items, required by changes to international tumour grading and staging schemes that have been approved by the Specialty Advisory Committee on Cellular Pathology and affiliated professional bodies, will be

implemented without further consultation. If minor revisions or changes to non-core data items are required, an abridged consultation process will be undertaken whereby a short note of the proposed changes will be placed on the College website for 2 weeks for members' attention. If members do not object to the changes, the short notice of change will be incorporated into the dataset and the full revised version (incorporating the changes) will replace the existing version on the College website.

The dataset has been reviewed by the Professional Guidelines team, Working Group on Cancer Services and the Lay Advisory Group and was placed on the College website for consultation with the membership from 28 June 2023 to 26 July 2023. All comments received from the Working Group and membership were addressed by the authors to the satisfaction of the Chair of the Working Group and the Clinical Lead for Guideline Review.

This dataset was developed without external funding to the writing group. The College requires the authors of datasets to provide a list of potential conflicts of interest; these are monitored by the Professional Guidelines team and are available on request. The authors have declared no conflicts of interest.

1 Introduction

The dataset has been developed for the reporting of biopsy and resection specimens of the thyroid gland. The dataset applies to all cancers of the thyroid apart from lymphomas, sarcomas, malignant struma ovarii and tumours in the thyroglossal tract which are excluded. Brief explanatory notes regarding non-invasive follicular thyroid tumour with papillary like nuclear features (NIFTP) and the thyroid tumours of uncertain malignant potential (UMP) as defined in WHO 2022 are included but as these lesions are not regarded as carcinoma completion of a thyroid cancer dataset is not required.² Neck dissections and nodal excisions are dealt with in a separate dataset³ and this should be used in conjunction, where applicable.

The primary purpose of this document is twofold:

- to define the set of data necessary for the uniform recording and staging of the core pathological features in cancers of the thyroid gland
- to describe its application in sufficient detail and clarity that reports from different departments will contain equivalent information, allowing comparison of clinical practice and outcomes.

Optimal reporting of specimens from the thyroid requires a partnership between the pathologist, radiologist, and surgeon/oncologist. The surgeon can help the pathologist to provide the information necessary for patient management by providing all required clinical, radiological, and intra-operative information and by the appropriate handling and labelling of the specimen in the operating theatre. The regular discussion of cases at multidisciplinary team (MDT) (and other clinico-pathological) meetings and correlation with pre-operative imaging studies are important in maintaining and developing this partnership.

The core pathological data are summarised as proformas that may be used as the main reporting format or may be combined with free text as required. A common proforma is utilised in keeping with the ICCR dataset. Individual centres may wish to expand the detail in some sections, for example, for sites and subsites, to facilitate the recording of data for particular tumour types.

The guidelines within this dataset should be implemented for the following reasons.

The pathological assessment of thyroid tumours has evolved since the 2014 thyroid cancer dataset. Revisions to existing terminology have been introduced for borderline follicular patterned tumours, specifically NIFTP, well-differentiated tumour of uncertain malignant

potential (WDTUMP) and follicular tumour of uncertain malignant potential (FTUMP) as described in the *2022 World Health Organization (WHO) Classification of Endocrine and Neuroendocrine Tumours*.² Changes have also occurred in other tumour type classifications, and grading of follicular derived and medullary carcinomas is now required.

A list of the major changes is given below:²

- thyroid tumours are now sub-divided into several new categories based on cell of origin, pathological and molecular features, and biological behaviour
- follicular cell-derived tumours are divided into benign, low-risk and malignant neoplasms
- the term thyroid follicular nodular disease (FND) is used for multifocal hyperplastic/neoplastic lesions occurring in multinodular goitre
- a low-risk follicular cell-derived neoplasm category now includes non-invasive follicular thyroid neoplasm with papillary-like nuclear features (NIFTP), thyroid tumours of uncertain malignant potential and hyalinising trabecular tumour (HTT)
- malignant follicular cell-derived neoplasms are risk stratified based on molecular profile and aggressiveness
- subtyping of papillary thyroid carcinoma (PTC) lesions less than 10mm in size is now required; the term papillary microcarcinoma is no longer used
- criteria for the tall cell subtype of PTC have been clarified
- cribriform-morular thyroid carcinoma is no longer classified as a subtype of PTC
- the term Hürthle cell is no longer recommended
- oncocytic carcinoma is recognised as a distinct entity; an oncocytic follicular cell-derived neoplasm, comprising of >75% oncocytic cells without either characteristic nuclear features of PTC or high-grade features
- an expanded high-grade follicular cell-derived malignancy category that includes high-grade differentiated thyroid carcinoma as well as the poorly differentiated thyroid carcinoma; both are characterised by increased mitotic activity and tumour necrosis without anaplastic histology and both show similar disease specific survival
- squamous cell carcinoma of the thyroid is now considered a subtype of anaplastic carcinoma
- medullary thyroid carcinomas composed of both C cells and any follicular cell-derived malignancy are placed in a mixed tumour subcategory
- grading of medullary thyroid carcinomas based on mitotic count, tumour necrosis, and Ki67 labelling index is recommended
- mucoepidermoid carcinoma and secretory carcinoma of the salivary gland type are now included in a section classified as salivary gland-type carcinomas of the thyroid
- thymomas, thymic carcinomas and spindle epithelial tumour with thymus-like elements (SETTLE) are classified as thymic tumours within the thyroid
- several tumours of unclear cell lineage are listed as such, including sclerosing mucoepidermoid carcinoma with eosinophilia, cribriform-morular thyroid carcinoma and thyroblastoma.

The treatment of thyroid cancer requires pathology input to multidisciplinary management, which is crucial because of the relative subjectivity of some pathological diagnostic criteria. These dataset items are important for prognostic purposes and clinical decision making. Examples include:

- deciding on the most appropriate treatment for particular patients, for example, extent of surgery, use and choice of adjuvant radio-iodine ablation, radiotherapy, chemotherapy, or targeted therapies
- providing accurate pathological information that can be used, together with clinical data, for patients to be given both a diagnosis and prognosis
- correlation of resection specimens with preoperative imaging and operative findings, including the surgical assessment of thyroid resection margin status
- identifying good pathological and oncological practice and the selection and assessment of patients in clinical trials
- major advances in the treatment of thyroid tumours now include a requirement for molecular pathology in many cases, usually undertaken on biopsy or surgically resected thyroid material
- monitoring changing patterns of disease, particularly by cancer registries.

1.1 Design of this guideline

The College recognises the authority of internationally accepted guidance documents (WHO, AJCC/UICC, TNM and ICCR) and, to promote consistent reporting practice, adopts the recommendations of these organisations.^{1,2,4,5} This RCPATH dataset has been developed using the framework and data items specified in the 2nd edition of the ICCR thyroid carcinoma dataset (published in 2020).¹ This RCPATH dataset includes all of the ICCR cancer dataset elements as well as additional information, elements and commentary pertinent to UK practice. Most of the ICCR text has been used verbatim, except where it has been necessary to modify the text of ICCR 2020 to ensure that the recommendations of this dataset align with the updated 5th edition of the *WHO Classification of Endocrine and Neuroendocrine Tumours* published in April 2022.²

ICCR core and non-core dataset elements for these cancers have been included verbatim where these do not conflict with WHO 2022 and are indicated by the blue ICCR logo. ICCR core elements are mandatory and are therefore represented as standards in this document. ICCR (and RCPATH) non-core elements are recommended and may be included as guidelines or used routinely according to local practice.

1.2 Target users and health benefits of this guideline

The dataset is primarily intended for use by consultant and trainee pathologists when reporting biopsies and resection specimens of thyroid gland tumours and has been developed to aid a consistent approach to the reporting of these cancers. Surgeons and oncologists may refer to the dataset when interpreting histopathology reports and core data should be available at MDT meetings to inform discussions on the management of thyroid cancer patients. The core data items incorporated are collected for epidemiological analysis by cancer registries on behalf of the National Cancer Registration and Analysis Service (NCRAS).

2 Clinical information required for the diagnosis of carcinomas of the thyroid

The request form should include patient demographic data, which includes:

- the patient's name, date of birth, gender, hospital of surgery, NHS number (where appropriate), or other patient identification number.

The provision of relevant clinical information (see below) is vital to the correct assessment and interpretation of pathology specimens. Clinical information should include any information relevant to thyroid disease, for example:

- the indication for performing the surgery should be recorded as many thyroid cancers are found incidentally in thyroid specimens removed for a purpose other than for suspected cancer
- if a pre-operative fine needle aspiration (FNA) or biopsy has been performed, this should be recorded, and the results of that biopsy briefly stated. Details of previous pathology reports should be included
- if imaging has been performed, this should be recorded, and the results briefly stated
- clinical presentation including biochemical evidence of hyperthyroidism or hypothyroidism with the duration of symptoms and autoantibody status
- any previous history of thyroid tumour
- previous thyroid surgery or medical treatments such as anti-thyroid drugs or radioactive iodine should be noted
- a history of previous resection, radiotherapy or chemotherapy should be included as this may influence the interpretation of the histological changes and should prompt a comment on the extent of any response to treatment
- previous exposure of the neck to radiotherapy (for example, for treatment of Hodgkin's lymphoma) should be noted
- family history of thyroid cancers or features of other endocrine tumours or syndromes should be recorded. It is worth noting that gastrointestinal manifestations of an endocrine syndrome may present before identification of an endocrine tumour
- the core operative data items (see section 5).

The request form should provide the opportunity for surgeons to provide annotated diagrams of specimens, either as free-hand drawings or on standard diagrams. Copies of reports that are sent to the cancer registries should include the patient's address if possible.

The following should also be recorded:

- the name of the clinician requesting the investigation
- the date and time of the operation
- the date and time at which the specimen was fixed
- the date and time the specimen was received in the laboratory.

3 Receipt and preparation of specimens before dissection

Thyroid resection specimens are usually sent in formalin, which should be of adequate volume to ensure proper fixation. If received fresh, formalin must be added. Larger specimens should be sliced to aid fixation.

4 Specimen handling and block dissection

Core biopsies of thyroid tumours should be embedded in their entirety and preferably in separate blocks to prevent tissue depletion during workup and to retain tissue for molecular testing if required.

The nature of the specimen and laterality (in lobectomy/hemithyroidectomy specimens) should be noted and, if possible, the specimen orientated either by sutures or by pinning to a board. The specimen should be inspected for attached parathyroid glands and lymph nodes. If the

thyroidectomy is submitted with a more extensive lymph node dissection, the specimen should be submitted with orientation as per College guidance for neck dissections.³ The thyroid capsule should be examined to assess whether or not it appears intact and the resection margins inked if there is suspicion of neoplasia. Anterior, posterior and isthmic margins should be inked in different colours. If the thyroid or lobectomy specimen is grossly enlarged, the specimen can be weighed; however, it should be described and the dimensions of each lobe recorded. The specimen should be serially sliced into 5 mm thick slices preferably in the horizontal (axial) plane. Any possible parathyroid glands or lymph nodes or other associated surrounding tissues identified should be sampled and processed. Specimen photography is invaluable to correlate with clinical, surgical and radiological findings and to record sites of blocks. The intra-operative findings noted by the surgeon should be correlated with the pathological assessment of the gross pathology specimen.

An encapsulated nodule should be treated as a potential follicular tumour and sampled as below. Any unusual foci should be also processed. Resection specimens identified as a biohazard risk (for example, HIV, tuberculosis) should be fixed for at least 48 hours. If tissue is sent fresh from theatres, this should reach the pathology laboratory promptly. Refer to the [COVID-19 Resources Hub](#) for the latest COVID-19 related guidance for specimen handling.

The pathological evaluation of specimens containing encapsulated follicular lesions, which are typically diagnosed pre-operatively on FNA cytology as 'follicular neoplasm Thy 3f', requires special attention to confirm or exclude the presence of a malignant follicular neoplasm.⁶ Conventionally, the distinction between a hyperplastic nodule and a follicular adenoma is based on the encapsulation and solitary nature of the latter. The distinction between a follicular adenoma and a follicular carcinoma will rest on the pathological identification of invasion through this capsule and/or the presence of vascular invasion within capsular or extracapsular smooth muscle lined vessels. This dataset follows an approach similar to that taken in the 2014 edition of this dataset, recommending that smaller encapsulated thyroid lesions, nodules ≤ 40 mm in diameter, should be sampled in their entirety. If the lesion is larger than 40 mm as a minimum it should be sampled widely (with at least 2 blocks per 1 cm diameter of the lesion) although some pathologists would recommend complete examination of the whole capsule.²

If histologically the capsule is thickened, irregular, or foci concerning for capsular or vascular invasion are identified, the whole lesion capsule should be sampled. Similarly, before a diagnosis of NIFTP, FTUMP or WDTUMP is made, the whole lesional capsule should be sampled.⁷

4.1 Methods for capsular sampling

There are various cut-up methods describing how the entire capsule can be sampled, including serial transverse slicing of the lesion in the axial plane, the most commonly undertaken method, quadratic sectioning of the capsule, or 'coring' the lesion following transverse slicing to try and sample the entire periphery of the lesion (Figure 1). These methods are often difficult to perform in routine practice and do not allow easy visualisation of the capsule at the poles of the lesion which can be difficult to interpret in axial sections.

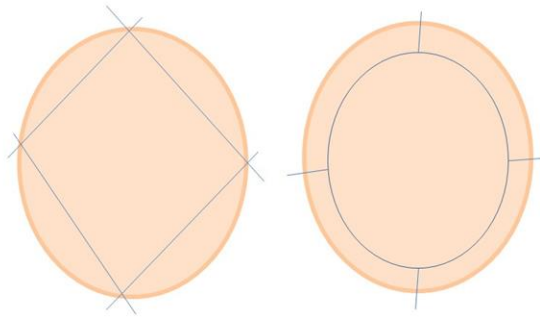


Figure 1: Illustration of two methods for examining the capsule of a thyroid nodule.

Another technique that is simple and allows complete sampling of the lesional capsule is described below⁸ (Figure 2):

- during external examination of the diagnostic lobectomy specimen, palpate and identify the superior and inferior poles of the lesion
- make a transverse cut across the specimen, about 1 cm (less for small lesions) below and above the superior and inferior poles respectively to separate them from the central portion of the lesion. These polar fragments can then be sliced perpendicularly/as cruciates to sample the entire convexity of the capsule at the poles of the lesion.
- for the remaining central portion of the lesion, transversely slice through the lesion and embed entirely. Depending on the size of the lesion, this could either be in the form of multiple standard blocks or as entire slices within mega blocks, to enable evaluation of the entire circumference of the capsule.

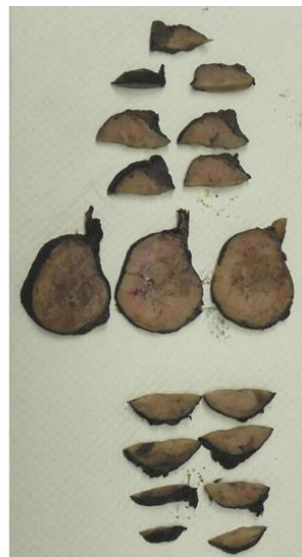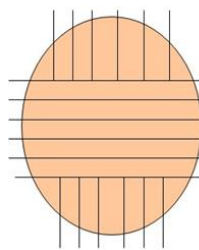


Figure 2: Third method for examining the capsule of a thyroid nodule.⁸


5 Core data items


We have set out to use the ICCR dataset in its current form, with appropriate qualifications and clarifications for implementation in UK clinical practice. In addition to the main dataset items, as outlined below, demographic and clinical data should be collected, as per the ICCR dataset and as outlined in section 2 above.


Core 1	Descriptor	Responses
ICCR	Operative procedure	Not specified Total thyroidectomy Near total thyroidectomy Hemithyroidectomy Lobectomy Isthmusectomy Partial excision (specify type if possible) Lymph node dissection Other (specify)
<p>Operative procedure ICCR commentary: The thyroid gland ordinarily is composed of a right and a left lobe lying adjacent and lateral to the upper trachea and oesophagus. An isthmus connects both lobes, and in some cases a pyramidal lobe is present extending cephalad anterior to the thyroid cartilage. Surgical management of thyroid tumours consists of either a lobectomy (removal of a lobe), a hemithyroidectomy (resection of lobe and isthmus), subtotal thyroidectomy or total thyroidectomy. Cases with lobectomy followed by completion thyroidectomy in the same operative procedure should be classified as total thyroidectomies. Other procedures include completion thyroidectomy, central compartment, or lateral neck node dissection.</p> <p>RCPATH additional comments: If a neck dissection specimen is submitted, please also refer to the separate neck dissection dataset if appropriate.³</p> <p><i>[Level of evidence C – The basis in evidence for inclusion is well-conducted case-control or cohort studies.]</i></p>		

Core 2	Descriptor	Responses
ICCR	Operative findings	Not specified Intra-operative macroscopic evidence of extrathyroidal extension (ETE) Yes, specify location and tissue invaded No Information not available Intra-operative impression of completeness of excision R0/R1 R2, specify location Information not available Other, specify
<p>Operative findings ICCR commentary: It is expected that the surgeon provides information with regards to the presence or absence of gross ETE at the time of the surgical procedure, in particular involvement of strap muscles as well as to the completeness of excision. Gross ETE is a crucial element in most recent staging systems.^{4,5} The pathologist should indicate if the intraoperative data on gross ETE or margin completeness is not available at the time of pathology reporting.</p> <p><i>[Level of evidence C – The basis in evidence for inclusion is well-conducted case-control or cohort studies.]</i></p>		

	Descriptor	Responses
--	------------	-----------

Core 3 	Specimens submitted	Not specified Thyroid gland Left Right Isthmus Parathyroid gland(s) Lymph node(s), specify site(s) and laterality Other, specify site(s) and laterality
	<p>Specimens submitted ICCR commentary: The nature of the specimen and laterality (in lobectomy specimens and node dissection) must be reported.</p> <p><i>[Level of evidence C – The basis in evidence for inclusion is well-conducted case-control or cohort studies.]</i></p>	

Core 4 	Descriptor	Responses
	Tumour focality	Unifocal Multifocal Cannot be assessed, specify
<p>Tumour focality commentary: Multifocality (defined as more than 1 tumour focus) is not uncommon in patients with papillary carcinoma and medullary carcinoma and should be reported.</p> <p><i>[Level of evidence C – The basis in evidence for inclusion is well-conducted case-control or cohort studies.]</i></p>		

Core 5 	Descriptor	Responses
	Tumour site	Not specified Left lobe Right lobe Isthmus Pyramidal lobe Soft tissue or muscle, specify site(s) and laterality Other, specify site(s) and laterality
<p>Tumour site ICCR commentary: The thyroid may give rise to multiple foci of carcinoma in the same gland, designated as per the American Joint Committee on Cancer (AJCC) and Union for International Cancer Control (UICC) guidelines with the descriptor (m).^{4,5} The designation of the tumour site and this dataset are applicable to the dominant excised carcinoma. The dominant tumour is defined as the most clinically relevant tumour because of its aggressiveness and/or its higher T stage. As such, it is often but not necessarily, the largest tumour. In cases of multiple lesions, the tumour characteristics of a second focus may be relevant and contribute to patient management, particularly if they are of a different histologic type (i.e. tumour 1 is papillary carcinoma and tumour 2 is medullary carcinoma). A second dataset should be generated for these instances. For additional tumour foci that do not alter management, only basic histopathological features (such as size and location) may be reported at the pathologist's discretion.</p> <p><i>[Level of evidence C – The basis in evidence for inclusion is well-conducted case-control or cohort studies.]</i></p>		

	Descriptor	Responses
--	-------------------	------------------

Core 6 ICCR	Tumour maximum dimension	Size (mm) of largest tumour Cannot be assessed, specify
<p>Tumour dimensions ICCR commentary: The dimension is that of the microscopically proven dominant tumour, based upon a reconciliation of the imaging, macroscopic and microscopic findings. The dominant tumour is defined as the most clinically relevant tumour because of its aggressiveness and/or its higher T stage. As such, it is often, but not necessarily, the largest tumour. Tumour size has an impact on prognosis and is a component of TNM staging. For example, papillary carcinomas measuring 1 cm or less are associated with an excellent prognosis, while tumours measuring over 4 cm are associated with a worse prognosis.⁹ If the exact tumour size cannot be measured, the report should mention the reason such as specimen fragmentation or a grossly positive margin.</p> <p><i>[Level of evidence C – The basis in evidence for inclusion is well-conducted case-control or cohort studies.]</i></p>		

Core 7 ICCR	Descriptor	Responses
	Histological tumour type	<ul style="list-style-type: none"> Papillary thyroid carcinoma <ul style="list-style-type: none"> Classic (usual, conventional) Encapsulated classic subtype Infiltrative follicular subtype Clear cell subtype Columnar cell subtype Diffuse sclerosing subtype Hobnail subtype Oncocytic subtype PTC with fibromatosis/fasciitis-like/desmoid stroma Solid/trabecular subtype Spindle cell subtype Tall cell subtype Warthin-like subtype Other subtype, specify Invasive encapsulated follicular variant papillary carcinoma (IEFVPTC) <ul style="list-style-type: none"> IEFVPTC, minimally invasive IEFVPTC, encapsulated angioinvasive IEFVPTC, widely invasive Follicular thyroid carcinoma (FTC) <ul style="list-style-type: none"> FTC, minimally invasive FTC, encapsulated angioinvasive FTC, widely invasive Oncocytic (Hürthle cell) carcinoma <ul style="list-style-type: none"> Oncocytic carcinoma, minimally invasive Oncocytic carcinoma, encapsulated angioinvasive Oncocytic carcinoma, widely invasive Follicular-derived carcinoma, high-grade <ul style="list-style-type: none"> Differentiated high grade thyroid carcinoma (DHGTC) Poorly differentiated thyroid carcinoma (PDTC) Anaplastic thyroid carcinoma

		Medullary thyroid carcinoma Mixed medullary and follicular cell derived thyroid carcinoma Mucoepidermoid carcinoma Secretory carcinoma of salivary gland type Sclerosing mucoepidermoid carcinoma with eosinophilia Cribriform morular thyroid carcinoma Spindle epithelial tumour with thymus-like elements Intrathyroid thymic carcinoma Thyroblastoma Other, specify
--	--	--

Histological tumour type ICCR commentary with edits to update for WHO: All tumours of the thyroid should be given a type based on the most recent edition of the WHO Classification of Tumours of Endocrine Organs.²

Papillary carcinoma: Papillary carcinoma is the most common carcinoma type and consists of numerous, named subtypes, though only a few of these currently have sufficient evidence to be considered clinically and biologically relevant. Therefore, efforts should be made to flag or document the following subtypes when present:

- Classic (usual, conventional)
- Tall cell subtype
- Diffuse sclerosing subtype
- Encapsulated subtype
- Invasive follicular subtype
- Invasive encapsulated follicular variant of PTC (IEFVPTC)

Classical papillary thyroid carcinoma (PTC), and tall cell subtype: Classic (usual, conventional) papillary carcinoma is the most common and default subtype of papillary carcinoma. Tall cell subtype of papillary carcinoma is a more aggressive subtype that has a higher prevalence of *BRAF V600E* mutations and is more frequently refractory to radioactive iodine therapy.¹⁰⁻¹²

Infiltrative follicular subtype (IFVPTC), IEFVPTC and related lesions: Follicular subtype of papillary carcinoma is important to document because it has recently been substratified based on outcome into IFVPTC or a completely encapsulated/well demarcated subtype, which can be either non-invasive or show invasion. The encapsulated/well demarcated subtype is termed IEFVPTC. IFVPTC, which is rare, has a behaviour similar to classic papillary carcinoma, particularly in terms of propensity for nodal metastasis, while the behaviour of encapsulated/well circumscribed follicular subtype is more indolent, especially if non-invasive.^{13,14} IEFVPTC has a molecular profile similar to follicular adenoma and follicular thyroid carcinoma, and is a RAS driven lesion. IEFVPTC requires capsular and/or vascular invasion and is classified into 3 groups: minimally invasive (capsular invasion only), encapsulated angioinvasive (venous invasion with or without capsular invasion) and widely invasive. It is recognised that there are interobserver reproducibility issues with IEFVPTC related to definitions of capsular or vascular invasion, as well as differing thresholds for assessment of nuclear features of PTC.² IEFVPTC and follicular thyroid carcinoma are both encapsulated tumours with follicular architecture and growth so their distinction relies on the presence of nuclear features of PTC in IEFVPTC. The nuclear features of IEFVPTC tend to be more subtle than those seen in the infiltrative variant of PTC. Nuclear pseudo-inclusions are uncommon in IEFVPTC and PTC features are often variable throughout the tumour. IEFVPTC may show microfollicular, normofollicular, or macrofollicular growth. Solid or trabecular growth may occur although nuclear features of PTC should be maintained with <3 mitoses per 2 mm² to exclude a diagnosis of poorly differentiated thyroid carcinoma.²

There is a quite rare macrofollicular or diffuse follicular subtype with diffuse involvement of the thyroid without formation of grossly discernible nodules.

Many, but not all, non-invasive encapsulated/well circumscribed follicular subtypes of papillary thyroid carcinoma can now be reclassified under the new designation NIFTP. This shift in nomenclature arose as an effort to encourage conservative management of these lesions given their extremely low risk of structural recurrence.¹⁵ It is noteworthy that the impact of this change worldwide varies according to countries. For example, many cases designated as NIFTP today were labelled in parts of Asia (including Australia) as follicular adenomas and thus this new designation will have little effect on the practice of these pathologists. NIFTP remains an actionable surgical disease, albeit with a more conservative approach. As NIFTP is not overtly malignant, technically there is no need to report these under this cancer protocol. However, inclusion of limited parameters namely size, laterality, margin status and a statement on completeness of excision is encouraged.

It must be noted that not all tumours previously designated as non-invasive follicular subtype of papillary thyroid carcinoma would qualify as NIFTP.¹⁵ Several exclusionary criteria have been put forth in the initial publication of this entity in order to ensure that the NIFTP category remains indolent,¹⁵ which are as follows:

- solid/trabecular or insular growth $\geq 30\%$
- $\geq 1\%$ true papillary growth (for more explanation see below)
- presence of psammoma bodies
- tumour necrosis
- ≥ 3 mitosis/10 high power fields (HPFs) at 400x magnification
- tall cell, columnar, or cribriform morular morphology.

A key requirement for a NIFTP diagnosis is that the entire lesional border has been submitted for histologic evaluation. When a tumour fulfils these inclusion and exclusion criteria, NIFTP designation is appropriate. Of note, sub-centimetre NIFTP and NIFTP with oncocytic features have been shown to have an outcome similar to NIFTP.^{16,17}

Multifocal NIFTP has not been well validated yet. In view of the small number of articles on these NIFTP scenarios, some pathologists do not label these unusual forms of this entity as NIFTP. In these situations, our opinion is that the designation, NIFTP, is not absolutely contraindicated. NIFTP is still an evolving diagnosis, and certain problematic areas have already been noted such as the quantification of true papillae. Because the initial criterion of $< 1\%$ papillae was noted to be subjective and difficult to apply, there was a suggestion that even 1 well-formed papilla as defined above should be considered exclusionary.^{15,18} The 2022 *WHO Classification of Endocrine Tumours* confirms the NIFTP exclusion threshold of 1% or more true papillae. Oncocytic lesions with $> 75\%$ oncocytic cells that meet the NIFTP criteria and lesions less than 10mm in size meeting the NIFTP criteria are also now regarded as NIFTPs.² Encapsulated classic PTC is defined in the most recent WHO as an architecturally and cytologically typical PTC that is totally encapsulated. If an encapsulated follicular patterned tumour has questionable capsular/vascular invasion, the term UMP is used as a qualifier. These tumours are not required to be reported using this thyroid cancer protocol since their malignant potential has not been demonstrated yet. When the nuclear features of PTC are absent, these lesions are labelled as FTUMP while if PTC nuclei are questionable or present the designation WTUMP is used.²

Diffuse sclerosing subtype: Diffuse sclerosing subtype is a locoregionally aggressive subtype with a high rate of nodal metastasis and locoregional recurrence, though overall survival is good possibly because of the young age of the patients. Nonetheless, this subtype appears to

necessitate more aggressive initial surgical management including more extensive node dissection.¹⁹

Other subtypes that may have prognostic and therapeutic value but are rare and not well validated include:

- clear cell
- hobnail
- oncocytic or oxyphilic
- solid/trabecular
- spindle cell
- papillary thyroid carcinoma with fibromatosis/fasciitis-like/desmoid stroma
- Warthin-like.

Follicular and oncocytic (Hürthle cell) carcinomas: Follicular carcinoma is a well-differentiated thyroid carcinoma type defined by invasiveness in the absence of diagnostic nuclear features of papillary thyroid carcinoma. The diagnosis of follicular carcinoma and its distinction from follicular adenoma primarily depends on the identification of invasion of the tumour capsule and/or vascular spaces.

The most recent WHO classification subdivides these carcinomas into minimally invasive (capsular invasion only), encapsulated angioinvasive (any focus of vascular invasion) and widely invasive. The latter is defined as grossly apparent extensive invasion of the thyroid and/or extra-thyroid tissue with often prominent vascular invasion.² These widely invasive carcinomas are often characterised by loss of encapsulation and multiple invasive fronts radiating from the epicentre of the tumour. Oncocytic carcinoma is defined as a tumour composed of at least 75% oncocytes lacking the nuclear features of papillary carcinoma and demonstrating capsular and/or vascular invasion.² In the WHO classification of endocrine tumours oncocytic carcinoma is no longer considered a subtype of follicular carcinoma because of different (overall more aggressive) behaviour, different molecular profile and lower radioactive iodine avidity.² The definition of minimally invasive, angioinvasive and widely invasive oncocytic carcinoma mirrors those of follicular carcinoma.

Although pathologists can diagnose benign from malignant thyroid tumours with very high accuracy, there are extremely rare cases with distant metastasis in a setting of non-invasive follicular and oncocytic carcinoma even after complete sampling of the tumour capsule.²⁰ There are also very rare instances of regional nodal metastases without primary thyroid carcinoma found.²¹

While the majority of thyroid cancers are well differentiated, a subset is of high histological grade or poorly differentiated (many of these were historically known as insular, or trabecular carcinoma) or undifferentiated (anaplastic). These tumour types represent progression to a more aggressive phenotype and are often seen with co-existent or antecedent well-differentiated carcinoma. While detailed histomorphological review is beyond the scope of this protocol, salient features of both tumour types are listed below.

High grade follicular derived carcinomas: In the *2022 WHO Classification of Endocrine Tumours*, follicular derived tumours with either increased mitotic activity and/or necrosis but without anaplastic thyroid cancer histology are designated high grade follicular derived carcinomas if invasive.² These tumours either retain the distinctive morphology of well differentiated carcinomas of follicular cell derivation, in which case they are then referred to as DHGTC or, if not, they are referred to as PDTC; see Table 1 below.

DHGTC: These are tumours which retain distinctive follicular or papillary carcinoma morphology with increased mitotic counts and/or tumour necrosis. The mitotic count is by definition ≥ 5 mitoses per 2 mm^2 after evaluation of the most mitotically active areas (hot spot counting).² Tumour necrosis is defined by karyorrhectic nuclear debris or ghost contours of dead tumour cells and should be distinguished from infarct type changes caused by fine needle aspiration or regressive changes as may occur in oncocytic tumours. Tumour necrosis may be readily visible, sometimes comedo-like, but can also be very focal. DHGTC should be classified according to the dominant histology type; e.g. high grade papillary thyroid carcinomas often are tall cell, hobnail, or columnar cell, but DHGTC may be conventional type papillary thyroid carcinomas or follicular subtype papillary thyroid carcinomas.² High grade follicular thyroid carcinomas are less common and are usually widely invasive. Oncocytic thyroid carcinomas if mitotically active usually have a solid or trabecular growth pattern and therefore usually fulfil the criteria for poorly differentiated thyroid carcinoma as described below.

PDTC: PDTCs have a prognosis in between the well differentiated indolent papillary thyroid carcinoma and the often-fatal anaplastic carcinoma. PDTCs are tumours that display a solid, trabecular and/or insular growth pattern, and show 1 or more of the following: ≥ 3 mitoses per 2 mm^2 , tumour necrosis, and nuclear convolution (without other nuclear features seen in papillary carcinoma).^{22,23} Of note, encapsulated poorly differentiated thyroid carcinomas or DHGTC appear to have a more favourable prognosis than unencapsulated tumours.^{24,25} Encapsulated non-invasive follicular derived tumours with high grade features are very rare, usually with an indolent behaviour,²⁵ although one case was shown to develop bone metastasis.²⁶

Table 1: Tumour grade, differentiation, histological type, and outcome.

Grade (mitoses, tumour necrosis)	Histological differentiation (architecture: papillae, follicles, solid/trabecular/insular patterns)	Histological type	Outcome
Low	Present, good	Papillary carcinoma	Favourable
		Follicular carcinoma	
		Oncocytic carcinoma	
High	Present, poor	DHGTC: papillary, follicular, oncocytic Criteria: mitotic count ≥ 5 per 2 mm^2 and/or tumour necrosis)	Intermediate
		PDTC Criteria: at least 1 of the 3 following features; mitotic count ≥ 3 per 2 mm^2 and/or tumour necrosis and/or convoluted nuclei	
	Absent	Anaplastic thyroid carcinoma (ATC)	Poor

(Tumors with mixed histological features should be typed according to the component of highest grade and least differentiation)

Anaplastic (undifferentiated) carcinoma: Undifferentiated carcinoma represents the most extreme form of tumour progression and consists of a high-grade malignancy with spindled, pleomorphic, squamoid, or even rhabdoid morphology.²⁷ Undifferentiated carcinoma is almost invariably rapidly lethal. A better differentiated component such as PTC or oncocytic (Hürthle cell) carcinoma may be found and its presence should be mentioned.

Cribriform morular thyroid carcinoma: This is a biologically distinct tumour characterised by *Adenomatous polyposis coli (APC)* or beta-catenin mutations which shows an association with familial adenomatous polyposis coli, in some cases preceding recognition of colon polyps or other extracolonic manifestations.²⁸

Medullary carcinoma (MTC): These tumours may show a variety of morphologies; papillary, pseudopapillary, follicular, spindle cell, angiosarcoma like, plasmacytoid, squamous cells, giant cells, clear cells, oncocytic, melanotic, amphicrine, paraganglioma like, or encapsulated/cystic or may be mixed medullary and follicular derived lesions, for example medullary-follicular or medullary-papillary and so on. The latest WHO classification of endocrine tumours advocates grading of MTC2, 29 using the two category international grading system. High grade MTC are defined as tumours with any one or more of the following: mitotic index $\geq 5/2\text{mm}^2$, Ki67 index $\geq 5\%$ (counting 500–2,000 cells) or tumour necrosis. It is recommended that all MTC tumours are graded using this scheme.

RCPATH additional comments for NIFTP, UMP and HTT: These lesions are now classified in WHO 2022 as low risk neoplasms.²

NIFTP: As described above, the term NIFTP relates to a very tightly defined subset of **non-invasive** encapsulated/well circumscribed FVPTCs.^{2,15,30} NIFTP can only be diagnosed on histology, not cytology, although suspicion of NIFTP may be raised on a combination of the cytological and radiological features. The histological diagnostic criteria must be strictly adhered to, and all thyroid pathologists should be aware of these criteria. Any potential case of NIFTP should fulfil **all** the criteria, and these should all be documented in the report. The lesion should be embedded fully, and additional levels or sections examined (with relevant immunostains) if there are any foci raising the possibility of capsular or vascular invasion. *BRAF V600E* mutation (assessed by immunohistochemical or molecular testing) argues against a diagnosis of NIFTP.^{30–32} Other immunostains such as CK19, HBME1, CD56 and galectin-3 show significant overlap in staining between different follicular-patterned lesions and are regarded as of limited value in an individual case, especially to distinguish NIFTP from PTC/FVPTC, in particular non-invasive encapsulated FVPTC.^{33–37} The minimum threshold for nuclear features for a diagnosis of NIFTP remains subjective and this fact needs to be recognised by the clinical team because the diagnosis has relatively moderate to poor interobserver reproducibility in the few published studies so far.³⁸ If there is diagnostic uncertainty, further opinions should be sought. Comment should be made on completeness of excision. TNM staging is not required. NIFTP cases should be listed for discussion at the local thyroid MDT meeting.

UMP: Invasiveness is an important criterion of malignancy in encapsulated follicular-patterned tumours. The term 'uncertain malignant potential' (UMP) is used when this invasion is 'questionable', i.e. neither clearly present nor clearly absent.³⁹ Unfortunately, histological interpretation of invasion can be subjective.^{40–44} Tumours of UMP can be regarded as 'borderline',⁴¹ 'precursor'⁴² or 'intermediate' between benign and malignant.⁴⁵ In contrast, the terms 'adenoma' and 'NIFTP' are used for tumours that clearly have no invasion and the term 'carcinoma' when invasion is clearly present.

FTUMP: This is indeterminate between a well differentiated minimally invasive follicular carcinoma and a follicular adenoma. All by definition lack PTC-like nuclei, (nuclear score 0–1)² but FTUMP has questionable capsular invasion and/or questionable vascular invasion around the edge of the tumour.

WDTUMP: The diagnostic decision is between either IEFVPTC or well differentiated carcinoma not otherwise specified (NOS), or NIFTP. Similarly, there is questionable capsular invasion and/or questionable vascular invasion but the nuclei are either PTC-like or questionably so, with a nuclear score of 2–3.²

All thyroid pathologists should be aware of the diagnostic criteria for FTUMP and WDTUMP. Making the histological diagnosis of a thyroid tumour of UMP should be a last resort after extensive examination of the pathological specimen, embedding all the material, examination of multiple levels for possible invasion (with relevant immunostains),^{40,41} and including seeking a second opinion if required. The term ‘UMP’ should never be a substitute for adequate sampling and pathological interpretation and should be used as a last resort. The latest WHO classification of endocrine tumours confirms this approach, stating as described above that FTUMP are lesions where invasion remains questionable despite thorough examination and exhaustive sampling.² *BRAF* V600E mutation (assessed by immunohistochemically or molecular testing) argues against a diagnosis of FTUMP or WDTUMP. Other immunohistochemistry (for example, CK19, HBME1, CD56, galectin-3, p63) is of limited value, showing heterogeneity and overlap with both benign and malignant lesions.^{45–49} Comment should be made on completeness of excision. TNM staging is not required. Cases of FTUMP or WDTUMP should be listed for discussion at the local thyroid MDT meeting.

HTT: This is a follicular derived neoplasm comprising large trabeculae of elongated/polygonal cells with prominent nuclear grooves, vacuoles and membrane irregularities, and hyaline cytoplasm, admixed with intra-trabecular hyaline material. It is characterised by *GLIS* rearrangements, and it has a unique immunohistochemical staining pattern showing membrane staining with the MIB1 Ki67 antibody at room temperature. The majority of lesions behave in a benign fashion on long term follow-up. Rare cases with lymph node or distant metastases usually show invasive growth or vascular invasion.²

[Level of evidence C – The basis in evidence for inclusion is well-conducted case-control or cohort studies.]

Core 8	Descriptor	Responses
ICCR	Histological tumour grade (follicular derived tumours)	Well differentiated Differentiated high grade Poorly differentiated Undifferentiated/anaplastic
	Histological tumour grade (medullary thyroid carcinoma)	High grade Low grade

Histological tumour grade ICCR commentary with edits to update for WHO: The grade in thyroid carcinomas of follicular cell origin (including both papillary and follicular carcinoma) impacts outcome significantly. It can be deduced from the histologic type along with increased mitotic activity and tumour necrosis.

RCPATH additional commentary: DHGTC and PDTC are now recognised in the 2022 WHO classification of endocrine tumours.² Tumour grade is now a core data item. Tumour type and mitotic count are also core data items that should be recorded. Please also refer to core data items 7 and 9.^{2,29}

[Level of evidence C/D – The basis in evidence for inclusion is case-control or cohort studies.]

Core 9	Descriptor	Responses
ICCR	Mitotic Activity	Not identified/low (<3 mitoses / 2mm ²) High (either ≥3 [PDTTC] or ≥5 mitoses/2mm ² [DHGTC, MTC]) Number of mitoses per 2mm ² Cannot be assessed
<p>Mitotic activity ICCR commentary with edits to update for WHO: The mitotic status should be reported in every thyroid carcinoma since it now an essential defining criterion for PDTTC,^{23,24} and for DHGTC. Mitotic count is also required for grading of medullary thyroid carcinomas.² The vast majority of thyroid carcinomas have a very low mitotic rate and a mitotic count is required only in those cases with elevated mitotic activity (≥3 mitoses/2 mm²). Mitotic count should be performed in the area of highest mitotic activity in 10 consecutive HPFs.^{25,50} The Ki-67 proliferation rate has been shown to correlate with outcome.^{51,52} It has not been utilised in the commonly used definitions of poorly differentiated thyroid carcinomas and DHGTC thus is not a required element. It can however guide the pathologist to the area of highest mitotic activity.</p> <p>RCPATH additional commentary: Although mitotic count is a core data item its principal importance is in the diagnosis of PDTTC and in identifying another higher risk lesion, i.e. DHGTC. Mitotic count is crucial in tumours which show either solid/trabecular/insular architecture, or cytological pleomorphism, or evidence of necrosis (focal/diffuse). The HPF mitotic count should be derived from a standardised field calibration (per 2 mm²).</p> <p><i>[Level of evidence C – The basis in evidence for inclusion is well-conducted case-control or cohort studies.]</i></p>		

Core 10	Descriptor	Responses
ICCR	Tumour encapsulation/ circumscription	Encapsulated Infiltrative Other, specify
<p>Tumour encapsulation/circumscription ICCR commentary: The presence of a fibrous capsule or a well demarcated tumour border (i.e., well circumscribed tumour edge directly adjacent to benign thyroid parenchyma with no intervening capsule) is a crucial element in thyroid carcinomas. In follicular and oncocytic (Hürthle cell) tumours, invasion of the capsule and its vessels define malignancy.²² Even in high grade tumours such as poorly differentiated carcinoma, the presence of a capsule was shown to convey a better outcome.²⁴ When a tumour infiltrates the surrounding non-neoplastic parenchyma and is not completely encapsulated/well demarcated, it should be labelled as infiltrative. The infiltrative papillary carcinomas are usually different from their encapsulated counterparts in regard to metastatic spread (propensity for nodal rather than distant metastasis) and genetic mutations (<i>BRAFV600E</i> rather than <i>RAS</i> mutations).⁵³</p> <p><i>[Level of evidence C/D – The basis in evidence for inclusion is case-control or cohort studies.]</i></p>		

Core 11	Descriptor	Responses
ICCR	Capsular invasion	Not applicable Uncertain Not identified Present Cannot be assessed, specify
<p>Capsular invasion ICCR commentary: There is no consensus as to the definition of capsular invasion (CI). While there is universal agreement that complete transgression of the capsule constitutes CI,⁵⁴ other authorities do not require complete transgression of the capsule.⁵⁵ Figure 3</p>		

depicts the various histologic appearances associated with the presence or absence of CI. According to Chan,⁵⁴ a given neoplasm should not be diagnosed as carcinoma if complete capsular penetration cannot be proven after extensive sampling except in the following circumstance. This situation occurs when a satellite tumour nodule, morphologically similar to the main tumour, is lying just outside the tumour capsule (Figure 3E). This appearance results from failure to identify the point of capsular penetration. It is noteworthy that not all authors agree that these satellite nodules represent CI.⁵⁶ In equivocal cases of CI, the entire capsule, irrespective of tumour size, should be processed in the attempt to clarify whether CI is present. Deeper sections of the representative paraffin block(s) should be performed in the areas of concern in order to exclude CI.⁵⁴ Despite enhanced histologic examination, there are cases where the presence of CI is questionable. In this instance the term uncertain CI should be used. There is no need to report on the number of foci of CI since it has not been shown to have clinical value.

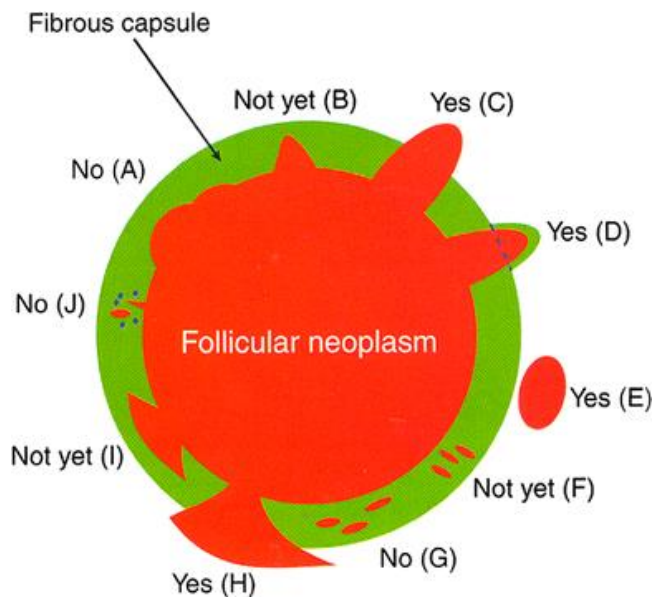


Figure 3: Capsular invasion (CI). Schematic drawing for the interpretation of the presence or absence of CI. The diagram depicts a follicular neoplasm (orange) surrounded by a fibrous capsule (green).

- A** Bosselation on the inner aspect of the capsule does not represent CI.
- B** Sharp tumour bud invades into but not through the capsule suggesting CI requiring deeper sections to exclude or confirm the presence of CI.
- C** Tumour totally transgresses the capsule invading beyond the outer contour of the capsule qualifying as CI.
- D** Tumour clothed by thin (probably new) fibrous capsule but already extending beyond an imaginary (dotted) line drawn through the outer contour of the capsule qualifying as CI.
- E** Satellite tumour nodule with similar features (architecture, cytomorphology) to the main tumour lying outside the capsule qualifying as CI.
- F** Follicles aligned perpendicular to the capsule suggesting invasion requiring deeper sections to exclude or confirm the presence of CI.
- G** Follicles aligned parallel to the capsule do not represent CI.
- H** Mushroom-shaped tumour with total transgression of the capsule qualifies as CI.
- I** Mushroom-shaped tumour within but not through the capsule suggests invasion requiring deeper sections to exclude or confirm the presence of CI.
- J** Neoplastic follicles in the fibrous capsule with a degenerated appearance accompanied by lymphocytes and siderophages does not represent CI but rather capsular rupture related to prior FNA.

Reproduced with permission from Chan J. Tumours of the thyroid and parathyroid glands *In: Fletcher CDM (ed.). Diagnostic Histopathology of Tumours (5th edition)*. London, UK: Elsevier, 997–1098.⁵⁴

[Level of evidence C – The basis in evidence for inclusion is well-conducted case-control or cohort studies.]

*Not applicable for nasopharynx

Core 12	Descriptor	Responses
<div style="background-color: #0070C0; color: white; padding: 2px; text-align: center; font-weight: bold;">ICCR</div>	Lymphatic and blood vessel invasion	Not identified Present Type of vessel(s) involved blood vessel, for encapsulated neoplasms specify focal, 1–3 foci extensive, ≥4 foci lymphatic small vessel, not otherwise classifiable Cannot be assessed, specify

Lymphatic and blood vessel invasion ICCR commentary: All follicular carcinomas and the vast majority of oncocytic (Hürthle cell) carcinomas spread hematogenously to distant sites bypassing lymph nodes while most papillary carcinomas (with the notable exception of encapsulated papillary carcinoma follicular subtype) preferentially spread to lymph nodes. It is therefore assumed that the vessels invaded by tumour in follicular and oncocytic (Hürthle cell) carcinoma are usually blood vessels while those in papillary carcinoma are usually lymphatic spaces. Invasion of the latter is however difficult to identify except in the rare diffuse sclerosing subtype.²² Lymphatic invasion can be undetected in many primary papillary carcinomas despite the patients having a large volume of nodal metastasis. Therefore, in contrast to blood vessel invasion, the presence of lymphatic space permeation has not been shown to date to have any prognostic value. Of note, blood vessel invasion can occur in papillary carcinomas (including classic) and the vessels involved are often readily identified as blood vessels because of their size and the presence of smooth muscle in their walls. Based on the type of carcinomas and the histologic appearance of the vessel, the pathologist can in most instances indicate the type of vessel involved by tumour. There are however, a few instances where this is not possible in small vessels. Since blood vessel invasion (BVI) is a crucial diagnostic and prognostic feature, the criteria for its identification should be well delineated. The majority of authors agree that BVI should involve capsular or extra-capsular vessels in encapsulated tumours (Figure 4). In infiltrative tumours partially encapsulated or totally lacking a capsule, BVI can be present within the tumour nodule. These images (Figure 4) depict intracapsular BVI with tumour thrombus attached to the vessel wall, covered by endothelium or associated with fibrin. Tumour thrombus covered by endothelial cells qualifies as BVI (Figure 4B). However, endothelialisation is not a requirement if the tumour is attached to the vessel wall (Figure 4C) or admixed with a fibrin thrombus (Figure 4D). If the tumour is encapsulated, intra-tumoural or subcapsular vessels do not qualify for BVI and should not be interpreted as such (Figure 4A). One study has raised the caveat that tumour cells within vascular lumina unassociated with thrombus, and tumour cells underlying intact endothelium could represent ‘pseudoinvasion’ given the fenestrated, endothelial network of endocrine organs.⁵⁷ When this more stringent criterion of BVI is applied, the incidence of BVI in differentiated thyroid carcinoma decreased drastically from 7–62%^{58–62} to 3%,⁵⁷ while the risk of distant metastasis in association with the mere existence of BVI becomes 35%. This latter approach has not been validated by additional studies and may fail to identify a significant proportion of thyroid tumours with BVI, focal or extensive, that should be classified as carcinoma based on the presence of invasion, and that may benefit from appropriate risk stratification and/or additional therapies.

The consensus opinion is that the criteria used in Figure 4 to define BVI should be utilised. With regards to the extent of BVI, several papers have shown that the presence of 4–5 foci of BVI in encapsulated follicular/oncocytic (Hürthle cell) carcinoma confers a much worse outcome than lower number of BVI foci.^{63–65} The most recent American Thyroid Association (ATA) guidelines classify a patient in a high risk category, if having 4 foci or more of BVI, while focal BVI (<4 foci) in an intrathyroidal follicular carcinoma will put the patient in low risk group.³⁹ More importantly, the National Comprehensive Cancer Network (NCCN) guidelines have defined minimal vascular invasion as a few foci (1–4) of vascular invasion, and does not mandate radioiodine (RAI) administration in an intrathyroidal, well defined, follicular or oncocytic (Hürthle cell) carcinoma, with minimal vascular invasion.⁶⁶ Consequently, it is important to report the extent of BVI in encapsulated thyroid carcinoma by counting the foci of BVI. It is noteworthy that most papers that validated the importance of BVI cut-offs have counted individual vessel sections invaded by tumour separately, as different foci. In regard to papillary thyroid carcinoma (PTC), the presence of BVI was shown to impart poorer outcome.⁶¹ Furthermore any focus of BVI in PTC will put the patient in an intermediate risk category according to the most recent ATA guidelines.³⁹ It is therefore mandatory to report on the status of BVI in PTC (i.e. core data item). There is no evidence that the number of BVI foci impact on prognosis in non-encapsulated PTC. Counting the BVI foci in non-encapsulated PTC is therefore not a core data item. It is however a core data item in those PTC who are completely encapsulated. In a small proportion of surgically operable, but locally aggressive differentiated thyroid carcinomas, tumour is identified within perithyroidal large veins or the internal jugular vein as large plugs of tumour thrombus. These patients often have synchronous distant metastases or are at higher risk to develop these subsequently. While the presence of extrathyroidal blood vessel invasion is not considered a separate core data item in addition to blood vessel invasion, there may be benefit in noting this finding if present. See Figure 4.

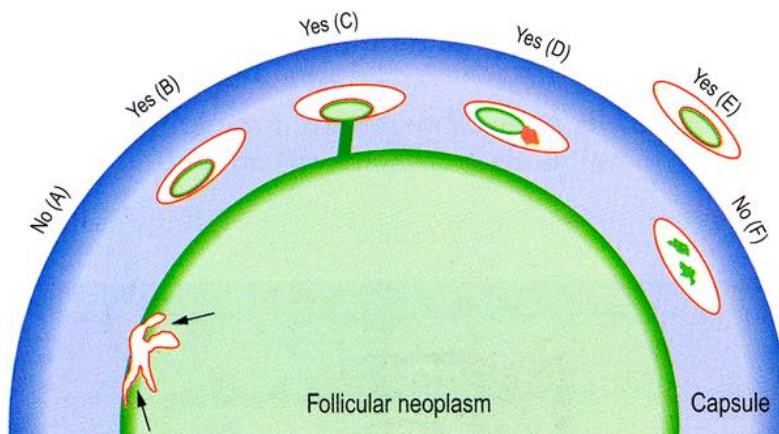


Figure 4: Blood vessel invasion (BVI). Schematic drawing for the interpretation of the presence or absence of BVI, the diagram depicts a follicular neoplasm (green) surrounded by a fibrous capsule (blue).

- A** Bulging of tumour into vessels within the tumour proper does not constitute BVI.
- B** Tumour thrombus covered by endothelial cells in intracapsular vessel qualifies as BVI.
- C** Tumour thrombus in intracapsular vessel considered as BVI since it is attached to the vessel wall.
- D** Although not endothelialised, this tumour thrombus qualifies for BVI because it is accompanied by a fibrin thrombus.
- E** Endothelialised tumour thrombus in vessel outside the tumour capsule represents BVI.

F Artefactual dislodgement of tumour manifesting as irregular tumour fragments into vascular lumen unaccompanied by endothelial covering or fibrin thrombus.

Modified version of original reproduced with permission from Chan J. Tumours of the thyroid and parathyroid glands *In: Fletcher CDM (ed.). Diagnostic Histopathology of Tumours (5th edition)*. London, UK: Elsevier, 997–1098.⁵⁴

[Level of evidence C – The basis in evidence for inclusion is well-conducted case-control or cohort studies.]

Core 13	Descriptor	Responses
ICCR	Necrosis	Not identified Present
<p>Necrosis ICCR commentary with edits to update for WHO: Tumour necrosis should be reported in every thyroid carcinoma since it is one defining criterion for DHGTC and PDTC regardless of the definitions used.^{2,23,24} Tumour necrosis is defined as coagulative or comedo-necrosis and should be differentiated from infarct-like necrosis related to previous fine needle aspiration (FNA) or ischemic changes within the tumour. Reactive changes seen in infarct-like necrosis such as hyalinization or fibrosis, haemorrhage, hemosiderin laden macrophages, cholesterol clefts or calcification, should be separated from comedo-necrosis or coagulative necrosis.</p> <p>RCPATH additional commentary: Oncocytic thyroid neoplasms are particularly prone to undergo infarction, either spontaneously or post FNA or needle core biopsy, which can create diagnostic difficulties, for example mimicking foci of capsular invasion. The presence or absence of tumour necrosis is now also required for grading medullary thyroid carcinomas, see sections 7 and 8 above.^{2,29}</p> <p><i>[Level of evidence D – The basis in evidence for inclusion is expert opinion.]</i></p>		

Core 14	Descriptor	Responses
ICCR	Extrathyroidal extension	Cannot be assessed Not identified Invasion into -perithyroid fibroadipose tissue -skeletal muscle -subcutaneous soft tissue, larynx, trachea, oesophagus, or recurrent laryngeal nerve -prevertebral fascia or encasing the carotid artery or mediastinal vessel
<p>Extrathyroidal extension (ETE) ICCR commentary: ETE, defined as tumour extension beyond the thyroid capsule into the adjacent soft tissue, is a common pathologic finding detected in 23.5% of all papillary thyroid carcinomas.⁶⁷ ETE has long been considered as an adverse prognostic factor with an increased risk of recurrence and mortality.⁶⁷⁻⁷⁰ It can be further subdivided into two categories: 1) minimal (or microscopic) ETE, which is invasion into the immediate perithyroidal soft tissue, detected solely at microscopic level and not appreciated clinically or grossly at the time of surgery; and 2) extensive (or gross) ETE that is defined as gross direct extension of the carcinoma into strap muscles (e.g. sternohyoid, sternothyroid, thyrohyoid, and omohyoid muscles), subcutaneous tissue, adjacent viscera (e.g. larynx, trachea, and oesophagus), or recurrent laryngeal nerve, and is typically established clinically by imaging or during the operation. These two categories of ETE bear different prognostic values: the risk of recurrence associated with minor ETE is approximately 3 to 9%,⁷¹⁻⁷⁷ compared with 23 to 40% risk of recurrence in patients with gross ETE.^{71-73,75,76,78,79} Furthermore, several recent studies have shown that microscopic ETE is not an independent predictor for persistent disease, recurrence free survival and disease specific survival.^{74,75,77,79-81} The National Comprehensive Cancer Network (NCCN) guidelines recommend completion thyroidectomy and post-operative radioactive iodine (RAI) for lesions with gross ETE, while the administration of 30 mCi of iodine 131 is considered optional for patients with a primary tumour of <4 cm, clinical M0 and minor ETE.⁶⁶ Histologically, the thyroid gland is devoid of a well-defined capsule in many areas along its periphery, and the follicles are often intermingled with adipose tissue or even skeletal muscle.⁸² Therefore, the very definition of microscopic ETE is problematic and subjective, and a universally accepted pathologic criterion for ETE is lacking. The fact that microscopic ETE is associated with poor interobserver agreement⁸² and does not affect recurrence and survival raises concerns of whether microscopic ETE alone is</p>		

sufficient to upstage a patient. Because of all the above, in the most recent AJCC and UICC 8th editions, microscopic ETE has been removed entirely from the staging system of differentiated thyroid carcinoma.^{4,5} Gross ETE invading strap muscles only, by a tumour of any size, will be staged as pT3b, while gross ETE with invasion into subcutaneous soft tissue, larynx, trachea, oesophagus or recurrent laryngeal nerve will be staged as pT4a. In view of the above, the pathologists' role is 1) to mention in their report the ETE seen histologically (whether microscopic or gross) and 2) communicate with the surgeon in regard to staging since the determination of gross ETE is done intra-operatively.

[Level of evidence C – The basis in evidence for inclusion is well-conducted case-control or cohort studies.]

RCPATH additional commentary: In the absence of macroscopic tumour involvement either surgically or pathologically, UICC and AJCC staging does not regard microscopic involvement of strap muscles as stage pT3b, or microscopic involvement of subcutaneous soft tissue, larynx, trachea, oesophagus, or recurrent laryngeal nerve as stage pT4a.^{4,5} However, in clinical practice, anecdotal evidence so far from the UK suggests that at least some thyroid MDTs might opt to alter clinical management of patients based on non-macroscopically confirmed microscopic involvement of strap muscles or microscopic involvement of other tissues (e.g. subcutaneous soft tissue, larynx, trachea, oesophagus, or recurrent laryngeal nerve).

Core 15	Descriptor	Responses
ICCR	Margin status	Not involved Involved, specify anterior or posterior Cannot be assessed, specify

Margin status ICCR commentary: The margin status of a surgical resection for thyroid carcinoma is a core element and can be divided into 3 categories: a R0 resection (microscopically negative margin), a R1 resection (grossly complete resection with microscopically positive margin), and a R2 resection (grossly positive margin or incomplete resection).⁵ The macroscopic status of the margins should be communicated to the pathologist by the operating surgeon. Histologically, a positive margin is defined by the presence of tumour cells at the inked tissue border and/or the outer aspect of the thyroid gland.^{83–86} Several recent studies have shown that a microscopically positive margin is not an independent predictor for recurrence and disease free survival, especially after adjusting for tumour stage and extrathyroidal extension (ETE).^{84–86} Taking this into consideration, the current American Thyroid Association (ATA) guideline has only included incomplete R2 resection into the risk stratification as a feature of high risk lesions.³⁹ In contrast, the National Comprehensive Cancer Network (NCCN) guideline has included any positive resection margin as one of the criteria to recommend completion thyroidectomy.⁶⁶ Lang et al. have shown that a microscopic positive posterior margin is an independent predictor for recurrence free survival with a 23-fold risk of recurrence, while a positive anterior margin did not pose a significant risk for recurrence.⁸⁵ However, studies are scant on the prognostic effect of the positive margin location, hence, this is non-core. Nevertheless, we encourage pathologists to ink the anterior and posterior margins differently when processing thyroid specimens and document the status of anterior and posterior margins separately in the pathology report. There is no data to date on the prognostic value of close margins as an independent or co-variable. Therefore, reporting distance of tumour to margin is non-core.

[Level of evidence C – The basis in evidence for inclusion is well-conducted case-control or cohort studies.]

Core 16	Descriptor	Responses
<div style="background-color: #0070C0; color: white; padding: 2px; text-align: center; font-weight: bold;">ICCR</div>	Lymph node status	No nodes submitted or found Number of nodes examined Not involved Involved Number of positive lymph nodes Number cannot be determined Location of involved lymph nodes, specify Greatest dimension of largest lymph node with metastasis (mm) Greatest dimension of largest metastatic focus in lymph node (mm) Extranodal extension Not identified Present Cannot be determined

Lymph node ICCR status commentary: Increasing evidence has shown that various characteristics of nodal metastases, e.g. number, size, and extranodal extension (ENE), may provide additional prognostic information. Thus, detailed features of nodal disease ought to be included in the pathology report, and be considered in risk stratification and staging systems.^{80,87–94} A recent meta-analysis by Randolph et al has shown that small volume subclinical microscopic pathologic N1 disease, i.e. 5 or fewer subcentimetre metastatic lymph nodes, conveys little prognostic impact on recurrence free survival and disease specific survival in papillary thyroid carcinoma (PTC), compared with clinically evident macroscopic nodal disease involving more than 5 lymph nodes, especially those with ENE.⁹² The greatest dimension of the largest metastatic deposit in a lymph node should be measured. It is accepted it can be difficult to distinguish multiple small metastases in one large deposit. Many authors recommend measuring the greatest dimension end to end in a single slide including discontinuous deposits.⁹⁵ Taking this data into consideration, the National Comprehensive Cancer Network (NCCN) guidelines no longer recommend completion thyroidectomy and post-operative RAI in small volume pN1a disease, i.e. <5 involved nodes with metastasis <2 mm in largest dimension.⁶⁶ Histologic features of the nodal metastasis that have been incorporated in the American Thyroid Association (ATA) initial risk stratifications included number of involved lymph nodes (>5 is considered as intermediate risk) and size of the metastatic lymph nodes (≥ 3 cm as high risk). The presence of psammoma bodies alone in a node is subject to controversy. While some practicing pathologists do not consider these as metastasis, we are in agreement with the College of American Pathologists in considering these lymph nodes as positive for metastatic carcinoma.⁵⁰

ENE is not an uncommon finding, being reported in up to 12% of PTC overall and 33% of nodal metastatic PTC.^{80,90} Similar to ETE, a well-defined, consensus, histologic diagnostic criterion for ENE is currently lacking.^{50,96} A recent study by Du et al. has shown that involvement of perinodal adipose tissue appears to be the most consistent diagnostic criteria of ENE, being considered by eleven participating endocrine pathologists as ENE.⁹⁶ However, the overall agreement in diagnosing ENE is only fair among expert pathologists.⁹⁶ Nevertheless, studies have repeatedly demonstrated the association between ENE and persistent and/or recurrence disease.^{80,87–92,94} Hence, it is important to document ENE in the pathology report of a differentiated thyroid carcinoma.

A 7 compartment nomenclature is used to define anatomic lymph nodes compartments. Central neck refers to level VI (peri-thyroidal, paralaryngeal, paratracheal, and prelaryngeal [Delphian]) and VII (upper mediastinal). Lateral neck refers to level I (submental/submandibular), II (upper jugular), III (mid jugular), IV (lower jugular) and V (posterior triangle).⁹⁷

At the current time, no additional special techniques should be used other than routine histology for the assessment of nodal metastases (i.e. sentinel lymph node-type protocols are not advocated). However, confirmation by immunohistochemical staining, including thyroglobulin for papillary carcinoma and calcitonin and neuroendocrine markers (e.g. chromogranins, synaptophysin) for medullary carcinoma, may be required.

RCPath additional commentary: The presence of psammoma-like calcifications in regional lymph nodes when thyroid carcinoma is known or suspected indicates a need to undertake additional levels and/or immunohistochemistry to confirm or exclude the presence of carcinoma (usually papillary) metastatic to lymph node, especially if psammoma bodies are the only form of lymph node involvement in a lymph node dissection.

Care needs to be taken when assessing lymph node metastases to ensure that these are not confused with benign mimics, e.g. parasitic nodules of Hashimoto's thyroiditis or thymic remnants.

[Level of evidence C – The basis in evidence for inclusion is well-conducted case-control or cohort studies.]

Core 17	Descriptor	Responses
ICCR	Co-existent pathology	None identified Follicular nodular disease Diffuse hyperplasia Dys hormonogenetic goitre Chronic lymphocytic thyroiditis Follicular adenoma Oncocytic (Hürthle cell) adenoma Non-invasive follicular thyroid neoplasm with papillary-like nuclear features (NIFTP) Other, specify

Coexistent pathology ICCR commentary with edits to update for WHO: The presence of chronic lymphocytic thyroiditis, follicular adenoma, oncocytic (Hürthle cell) adenoma, non-invasive follicular thyroid neoplasm with papillary-like nuclear features (NIFTP) and follicular nodular disease for example can help explain the clinical/imaging/cytologic findings.

[Level of evidence C – The basis in evidence for inclusion is well-conducted case-control or cohort studies.]

Core 18	Descriptor	Responses
ICCR	Parathyroid gland status	Not identified Present Number of parathyroid glands found Normal Involved by carcinoma Hypercellular/enlarged

Parathyroid gland status ICCR commentary: The number and status of the parathyroid glands in the specimen should be mentioned for surgical quality assurance purposes.

RCPath additional commentary: Enlarged parathyroid glands may be an indication of multiple endocrine neoplasia and may be relevant if medullary thyroid carcinoma is suspected. If a parathyroid gland is intrathyroidal this should be mentioned.

[Level of evidence C – The basis in evidence for inclusion is well-conducted case-control or cohort studies.]

Core 19	Descriptor	Responses
ICCR	Histologically confirmed distant metastases	Not identified Not assessed Present, specify site(s)
<p>Histologically confirmed distant metastases ICCR commentary: The presence of histologically confirmed distant metastasis is a key component of staging.⁴</p> <p>[Level of evidence C – The basis in evidence for inclusion is well-conducted case-control or cohort studies.]</p>		

6 Non-core data items

NC1	Descriptor	Responses
ICCR	Clinical information	Information not provided Previous history of thyroid tumour or related abnormality, specify Relevant biopsy/cytology results, specify Imaging findings, specify Previous surgery/therapy, specify Relevant family history, specify Presence of clinical syndrome, specify Other, specify
<p>Clinical information ICCR commentary: Any clinical information relevant to the thyroid disease should be recorded. If a pre-operative fine needle aspiration (FNA) or core biopsy has been performed, this should be recorded, and the results of that biopsy briefly stated. If imaging has been performed, this should be recorded, and the results briefly stated. Previous thyroid surgery or medical treatments like anti-thyroid drug or radioactive iodine should be noted. Previous exposure of the neck to radiotherapy (e.g. for treatment of Hodgkin lymphoma) should be noted. The indication for performing the surgery should be recorded as many thyroid cancers are found incidentally in thyroid specimens removed for a purpose other than cancer. Family history of thyroid cancers or features of other endocrine tumours or syndromes should be recorded. It is worth noting that gastrointestinal manifestations of an endocrine syndrome may present before identification of an endocrine tumour. Clinical or biochemical evidence of hyperthyroidism or hypothyroidism should be noted.</p> <p>RCPATH additional commentary: Please refer to section 2. Provision of relevant clinical information is absolutely essential to good practice.</p> <p>[Level of evidence D – The basis in evidence for inclusion is expert opinion.]</p>		

NC2	Descriptor	Responses
ICCR	Tumour focality	Number of tumours in specimen (if multifocal)
<p>Tumour focality ICCR commentary: Specify number of tumours in a multifocal specimen (if >5 state such but no need to specify the number).</p> <p><i>[Level of evidence C – The basis in evidence for inclusion is well-conducted case-control or cohort studies.]</i></p>		

NC3	Descriptor	Responses
ICCR	Tumour other dimensions	Additional dimensions (largest tumour, mm x mm)
<p><i>[Level of evidence C – The basis in evidence for inclusion is well-conducted case-control or cohort studies.]</i></p>		

NC4	Descriptor	Responses
ICCR	Extrathyroidal blood vessel invasion	Not identified Present
<p>RCPath additional commentary: Please also refer to core data item 12.</p> <p><i>[Level of evidence C – The basis in evidence for inclusion is well-conducted case-control or cohort studies.]</i></p>		

NC5	Descriptor	Responses
ICCR	Distance of tumour to closest margin	If not involved, distance to closest margin If involved, specify anterior or posterior
<p>RCPath additional commentary: Please also refer to core data item 14.</p> <p><i>[Level of evidence C – The basis in evidence for inclusion is well-conducted case-control or cohort studies.]</i></p>		

NC6	Descriptor	Responses
ICCR	C-cell hyperplasia	Not identified Identified Unilateral Bilateral
<p>C-cell hyperplasia ICCR commentary: The presence of C-cell hyperplasia may suggest hereditary disease and should therefore be reported in specimens harbouring medullary thyroid carcinoma.</p> <p>RCPath additional comments: Immunohistochemistry for calcitonin +/- carcinoembryonic antigen (CEA) is useful in identifying foci of C-cell proliferation. Sections used to identify C-cell proliferations should, ideally, be taken well away from the primary tumour(s), preferably at the junction of the upper and middle thirds of the thyroid lobes.</p> <p><i>[Level of evidence C – The basis in evidence for inclusion is well-conducted case-control or cohort studies.]</i></p>		

NC7	Descriptor	Responses
ICCR	Ancillary studies	Not performed Performed, specify
<p>Ancillary studies ICCR commentary: Ancillary studies may be used to determine lineage, disease classification or subclassification; as prognostic biomarkers; or to indicate the likelihood of patient response to specific biological therapies.</p> <p>In cases in which the diagnosis is suspected to be medullary carcinoma, immunostaining for calcitonin, chromogranin, synaptophysin, CEA and thyroglobulin may be performed to confirm the diagnosis. The calcitonin, CEA, chromogranin and synaptophysin immunostains are also helpful to identify C-cell hyperplasia.</p> <p>Thyroglobulin, thyroid transcription factor-1 (TTF-1) and PAX-8 may indicate that a tumour is of follicular cell origin. TTF-1 is more sensitive than thyroglobulin; however, TTF-1 can be positive in other cancers such as lung adenocarcinoma and small cell carcinoma of any primary site. Anaplastic thyroid carcinoma is negative for thyroglobulin, positive focally for TTF-1 in a small percentage of cases, but labels for PAX-8 in a substantial number of cases.⁹⁸</p> <p>It is not possible to differentiate benign and malignant thyroid tumours by using immunohistochemistry. Although cytokeratin 19, other high molecular weight cytokeratins and some other markers have been demonstrated to have stronger positivity in thyroid carcinomas than benign thyroid lesions, there are many exceptions, and the interpretation has to be taken in the context of the morphology of the lesion.</p> <p>Molecular analyses are currently being performed to identify targets in tumour refractory to radioactive iodine therapy. Immunostain for <i>BRAFV600E</i> mutation is an easy to perform, robust and rapid assay to select patients for <i>BRAF</i> inhibitor therapy.</p> <p>RCPATH additional comments: It is anticipated that results of some ancillary studies will be issued as supplementary reports, e.g. the results of molecular profiling, see section 9 below.</p> <p><i>[Level of evidence C – The basis in evidence for inclusion is well-conducted case-control or cohort studies.]</i></p>		

7 Diagnostic coding and staging

7.1 Diagnostic coding

SNOMED (Systematized Nomenclature of Medicine) topography should be recorded for the site of the tumour. SNOMED morphology codes should be recorded for the diagnosis/tumour morphology. See Appendix A.

7.2 Staging

Core 20	Descriptor	Responses
ICCR	Pathological staging (UICC TNM8)	See Appendix B
<p>Pathological staging ICCR comments: The staging applies to all tumour types, including anaplastic carcinoma, which hitherto had automatically been staged as stage 4 irrespective of all other details. The UICC TNM 8th edition staging applies to carcinomas and includes papillary, follicular, poorly differentiated, Hürthle cell (oncocytic), anaplastic, and medullary carcinoma.⁴</p>		

Multifocal tumours (≥ 2 foci) of all histological types should be designated (m), with the largest and/or most invasive focus determining the classification, e.g., pT2(m).

RCPATH additional comments: Please see Appendix B.

[Level of evidence C – The basis in evidence for inclusion is well-conducted case-control or cohort.]

8 Reporting of thyroid needle core biopsy specimens

Thyroid needle core biopsy (NCB) is not recommended as a substitute for FNA cytology for the first line investigation of thyroid nodules. Thyroid NCB does, however, have a role when used selectively, to enable histological assessment in fibrosing diseases of the thyroid, suspected anaplastic carcinoma, metastasis or lymphoma, or to collect tissue for molecular analysis if this is not feasible by FNA.⁹⁹ NCB may also be useful when repeated FNAs show insufficient/non-diagnostic cytological material (Thy1). Ideally, NCBs should only be undertaken after discussion within the multidisciplinary setting. The histological report should consider relevant radiology and previous cytology findings and, when a lesion has been biopsied, should state if there is evidence of a lesion capsule. Terminology systems for reporting thyroid NCB exist, but have not been widely validated in the UK.^{100–102} The report should discuss the certainty of diagnosis (e.g. anaplastic thyroid carcinoma or metastasis to thyroid) or list the extent of differential diagnosis (e.g. follicular lesion, cannot distinguish between benign lesions and follicular neoplasms).

NCB of the thyroid should be used with caution for a variety of reasons. It cannot be used to differentiate between hyperplastic nodule, follicular adenoma and follicular thyroid carcinoma, as these frequently show identical or overlapping histopathological appearances in small core samples. If an NCB has been done, pathologists should be informed of this at the time of receipt of any subsequent surgical resection. Ultrasound (US)-guided NCB should be performed by experienced operators because it is associated with higher rates of complications than FNA. NCB may be technically difficult or impossible in smaller nodules located deep within the thyroid or in proximity to major blood vessels and is more traumatic than FNA. Needle biopsy artefacts are often greater with NCB than with FNA and can produce appearances which mimic minimally invasive follicular carcinoma. Thus, in addition to not being diagnostically useful in follicular thyroid lesions, use of NCB may also compromise the subsequent pathological evaluation of the surgically excised nodule. Therefore, NCB is not advised for evaluation of potential follicular lesions.

9 Frozen section diagnosis

Intraoperative frozen section is occasionally used to confirm the diagnosis of papillary, medullary, or anaplastic carcinoma, to detect lymph node involvement, identify parathyroids for auto-transplantation or to assess shave margins. Frozen section may also occasionally be of value for confirmation of gross extra-thyroidal extension of primary thyroid carcinoma.¹⁰³ Patients undergoing routine surgery will already have undergone relevant investigations including clinical examination and almost always ultrasound guided FNA. A recent meta-analysis of routine frozen section thyroid for nodules classified on FNA as follicular neoplasm showed low overall sensitivity of 43% for malignancy, hence frozen section should not be used to differentiate adenoma from follicular carcinoma.¹⁰⁴

10 Molecular testing in thyroid tumours

This is a rapidly advancing field and the information below reflects a snapshot of knowledge and practice at the time of writing. Representative blocks of tumour should be identified for molecular testing, whether as fresh tissue or formalin fixed paraffin embedded as per local care pathways and protocols. Molecular changes in thyroid cancer have been well characterised as part of the Thyroid Cancer Genome Atlas Study.^{40,105} *BRAF*, *RAS* and *PAX8-PPARG* mutations are considered driver mutations in papillary and follicular carcinoma respectively and underpin the genetic signature of dedifferentiated tumours which arise from these.¹⁰⁶ Mutations of p53 and increasing genetic complexity are hallmarks of anaplastic thyroid carcinoma.¹⁰⁷ Oncocytic (Hürthle cell) thyroid carcinoma has a very different genetic landscape with mutations identified within the mitochondrial DNA genes and genes associated with oxidative phosphorylation pathways.¹⁰⁸ This new understanding explains why oncocytic (Hürthle cell) tumours are often relatively radioactive iodine (RAI)-refractory (RAI-R) and fluorodeoxyglucose (FDG)-positron emission tomography (PET) avid. Medullary carcinomas usually harbour germline or somatic *RET* mutations (insertions/deletions).¹⁰⁹

The genetic abnormalities and their frequency of occurrence in the main types of thyroid cancer are listed in Table 2 below.

Specific molecular tests for thyroid tumours are routinely available in England as part of the [National Genomic Test Directory for Cancer](#).

Information on relevant molecular events (e.g., *BRAF*, *TERT*) should be included in the report if required by local guidance.

Molecular testing is useful in the following contexts.

10.1 Diagnostic

Diagnosis of follicular patterned tumours: *BRAF V600E* mutation would not be expected in NIFTP and hence the presence of this mutation in a tumour where NIFTP is diagnostically considered implies a diagnosis of encapsulated follicular subtype of papillary thyroid carcinoma.^{30–32}

10.2 Therapeutic

Identifying therapeutic targets for systemic therapy particularly in advanced thyroid cancer: Selective therapeutic targets currently include *BRAF* (papillary and anaplastic carcinoma), *RET* and *ALK* (papillary, poorly differentiated, anaplastic and medullary carcinoma) and *NTRK*. Multi-tyrosine kinase inhibitors are now approved for the systemic treatment of advanced thyroid cancer.

10.3 Prognostic

Identifying high risk/aggressive subtypes of differentiated thyroid cancers (papillary and follicular thyroid carcinoma): *TERT* promoter mutations are the commonest identified mutation in this situation followed by *p53* mutations. Two mutually exclusive *TERT* promoter mutations are recurrent in thyroid carcinoma (position 124 (C228T) and position 146 (C250T) and their prevalence increases with de-differentiation [PTC (10%), FTC (20%), PDTC (40%), ATC (70%)]). In well differentiated thyroid carcinoma *TERT* mutations correlate with invasive growth and distant metastasis; prognosis worsens when a *TERT* mutation co-exists with *BRAF/RAS* mutations.^{110,111} In a recent study evaluating aggressive/fatal well differentiated and also poorly differentiated thyroid cancers a few novel mutations were identified (*MED12*, *RBM10*, *EIF1AX*, *DLG5-RET* fusion, *OSBPL1A-BRAF* fusion).¹¹²

Identifying poor outcome in low stage poorly differentiated thyroid cancers: p53 mutations help in predicting inferior outcome in these cancers.¹⁰⁶

10.4 Anaplastic thyroid carcinoma

BRAF mutation is common in anaplastic thyroid carcinoma (ATC). ATC with a squamous carcinoma phenotype is frequently associated with *BRAF V600E* mutation although having similar overall survival to conventional ATC.^{113,114} A similar frequency of nodal and systemic metastasis is noted irrespective of *BRAF/RAS* mutational genotype. ATC in which *TERT* mutations co-exist with *BRAF/RAS* mutations have a worse outcome.^{113,114} A rare but aggressive ATC variant that often shows squamous differentiation has been associated with NUTM 1 rearrangement.¹¹⁵

Table 2: Molecular alterations in thyroid cancer

	Molecular alterations
Papillary carcinoma	<ul style="list-style-type: none"> • <i>BRAF V600E</i> (40–80%) • <i>RET/PTC</i> fusions (5–20%) • <i>TERT</i> (5–15%) • <i>RAS</i> (0–10%) • <i>NTRK</i> rearrangement (0–10%) • Genetically stable, median number of mutations: 1+/-1 • <i>BRAF V600E</i> like TCGA molecular profile • ALK fusions (<i>STRN-ALK/EML4-ALK</i>) • <i>EIF1AX</i> • The prevalence of <i>RET/PTC</i> and <i>NTRK</i> 1 and 3 is higher in children and much higher in radiation-associated papillary thyroid carcinomas
Follicular carcinoma/follicular subtype of papillary carcinoma	<ul style="list-style-type: none"> • <i>RAS</i> (30–50%) [NRAS most common] • <i>PAX8/PPPARG</i> (10–30%) • <i>TERT</i> (10–35%) • <i>PIK3CA</i> (0–10%) • <i>PTEN</i> (0–10%) • <i>DICER1</i> (familial cases) • Can be genetically unstable and aneuploid, median number of mutations up to 5 • <i>RAS</i>-like TCGA molecular profile
Oncocytic (Hürthle cell) carcinoma	<ul style="list-style-type: none"> • Whole chromosomal losses (near haploid genome) • LOH – widespread (>0.6 genome) • Mitochondrial DNA mutations (70%). Mitochondrial complex 1 mutations, ND2 and ND4 are a feature of oncocytic (Hürthle cell) carcinoma. • Genes associated with glycolysis: <i>PI3K/AKT/mTOR</i>, <i>GLUT1</i>

	<ul style="list-style-type: none"> • Protein translation mutations: <i>EIF1AX</i>, <i>MADCAM1</i>, <i>DAXX</i> • Mutations enhancing cell proliferation: <i>RAS</i>, <i>RAF</i>, <i>MEK</i>, <i>ERK</i>, <i>NF1</i>, <i>ATXN1</i>, <i>TP53</i>, <i>TERT</i> • Cytoskeleton mutations: <i>UBXN11</i>, <i>GRIM-19</i> • miR-885-5p up regulation
Differentiated high grade thyroid carcinoma	<ul style="list-style-type: none"> • <i>BRAF V600E</i> • <i>RAS</i> • <i>RET</i> • <i>NTRK</i> • <i>TERT</i> • <i>PIK3CA</i> • <i>TP53</i>
Poorly differentiated thyroid carcinoma	<ul style="list-style-type: none"> • <i>RAS</i> (20–50%) • <i>TERT</i> (20–50%) • <i>TP53</i> (10–35%) • <i>BRAF V600E</i> (1–10%) • <i>PTEN</i> (5–20%) • <i>PIK3CA</i> (0–15%) • <i>EIF1AX</i> (5–15%) • <i>ALK</i> rearrangement (0–10) • Genetically unstable, aneuploid, median number of mutations: 2–3 • Typically have <i>RAS</i>-like TCGA molecular profile • <i>DICER 1</i> in paediatric and adolescent tumours • <i>ETV6-NTRK3</i> fusion
Anaplastic carcinoma	<ul style="list-style-type: none"> • <i>TP53</i> (40–80%) • <i>TERT</i> (30–75%) • <i>RAS</i> (10–50%) • <i>BRAF V600E</i> (10–50%) • <i>PIK3CA</i> (5–25%) • <i>PTEN</i> (10–15%) • <i>EIF1AX</i> (5–15%) • <i>ALK</i> rearrangement (0–10) • Genetically unstable, complex chromosomal alterations, highly aneuploid, median number of mutations: 6–5 • May have <i>RAS</i>-like or <i>BRAF V600E</i>-like TCGA molecular profile

Medullary carcinoma	<ul style="list-style-type: none"> • <i>RET</i> deletions/insertions (germline/somatic), <i>RAS</i>
---------------------	--

11 Support of research and clinical trials

The MDT should be aware of any relevant clinical trials and consider eligibility of patients. It is also important to be aware of local protocols for tissue banking and engagement with national initiatives for the further classification of tumours, (such as was implemented in the [100,000 Genomes Project](#)). Other features, such as assessment of the effects of biological therapy/immunotherapy may be important but are currently beyond the remit of this dataset.

12 Criteria for audit

The following are recommended by the RCPATH as Key assurance indicators (see [Key assurance indicators for pathology services, November 2019](#)) and key performance indicators (see [Key Performance Indicators – Proposals for implementation, July 2013](#)):

- cancer resections should be reported using a template or proforma, including items listed as core data items in RCPATH cancer datasets. Trusts are required to implement the structured recording of core pathology data.
 - standard: 95% of reports must contain structured data
- histopathology cases must be reported, confirmed, and authorised within 7 and 10 calendar days of the procedure
 - standard: 80% of cases must be reported within 7 calendar days and 90% within 10 calendar days.

Additional suggested audit criteria

The following criteria are additional examples of what could be assessed in periodic reviews of histological reports on thyroid cancers:

- completeness of reports for the core data items stated above (the standard being that 95% of reports contain a full set of core data items)
- turnaround times for reporting paraffin sections
- inter- and intra-observer studies in classification of tumours
- correlation of surgical pathology results with pre-operative FNA findings.

13 References

1. Ghossein R, Barletta J, Bullock M, Johnson S, Kakudo K *et al.* *Carcinoma of the Thyroid Histopathology Reporting Guide (2nd edition)*. International Collaboration on Cancer Reporting. Accessed August 2022. Available at: www.iccr-cancer.org/datasets/published-datasets/endocrine/thyroid/
2. WHO Classification of Tumours Editorial Board. *WHO Classification of Tumours Series: Endocrine and Neuroendocrine tumours (5th edition, volume 8)*. Lyon, France: International Agency for Research on Cancer, World Health Organisation, 2022.
3. Helliwell T, Woolgar J. *Dataset for histopathology reporting of nodal excisions and neck dissection specimens associated with head and neck carcinomas (1st edition)*. London, UK: The Royal College of Pathologists, 2013. Accessed September 2022. Available at: www.rcpath.org/uploads/assets/2babb476-472b-4008-997c6a1074fddb23/ataset-for-histopathology-reporting-of-nodal-excisions-and-neck-dissection-specimens-associated-with-head-and-neck-carcinomas.pdf
4. Brierley DJ, Gospodarowicz KM, Wittekind C (eds). *TNM Classification of Malignant Tumours (8th edition)*. Oxford, UK: Wiley-Blackwell, 2016.
5. Amin MB, Edge SB, Greene FL, Byrd DR, Brookland RK, Washington MK *et al.* *AJCC Cancer Staging Manual (8th edition)*. New York: Springer, 2017.
6. Yamashina M. Follicular neoplasms of the thyroid. Total circumferential evaluation of the fibrous capsule. *Am J Surg Pathol* 1992;16:392–400.
7. Hamza A, Khawar S, Alrajjal A, Salehi S. Processing the entire capsule in thyroid follicular lesions improves diagnostic accuracy. *Ann Diagn Pathol* 2019;39:21–24.
8. Oh H-S, Kim SJ, Song E, Lee Y-M, Sung T-Y, Kim WG *et al.* Modified Transverse-Vertical Gross Examination: a Better Method for the Detection of Definite Capsular Invasion in Encapsulated Follicular-Patterned Thyroid Neoplasms. *Endocr Pathol* 2019;30:106–112.
9. Machens A, Holzhausen H-J, Dralle H. The prognostic value of primary tumor size in papillary and follicular thyroid carcinoma. *Cancer* 2005;103:2269–2273.
10. Morris LGT, Shaha AR, Tuttle RM, Sikora AG, Ganly I. Tall-cell variant of papillary thyroid carcinoma: a matched-pair analysis of survival. *Thyroid* 2010;20:153–158.
11. Nikiforov YE, Nikiforova MN. Molecular genetics and diagnosis of thyroid cancer. *Nat Rev Endocrinol* 2011;7:569–580.
12. Rivera M, Ghossein RA, Schoder H, Gomez D, Larson SM, Tuttle RM. Histopathologic characterization of radioactive iodine-refractory fluorodeoxyglucose-positron emission tomography-positive thyroid carcinoma. *Cancer* 2008;113:48–56.
13. Liu J, Singh B, Tallini G, Carlson DL, Katabi N, Shaha A *et al.* Follicular variant of papillary thyroid carcinoma: a clinicopathologic study of a problematic entity. *Cancer* 2006;107:1255–1264.
14. Rivera M, Tuttle RM, Patel S, Shaha A, Shah JP, Ghossein RA. Encapsulated papillary thyroid carcinoma: a clinico-pathologic study of 106 cases with emphasis on its morphologic subtypes (histologic growth pattern). *Thyroid* 2009;19:119–127.

15. Nikiforov YE, Seethala RR, Tallini G, Baloch ZW, Basolo F, Thompson LDR *et al.* Nomenclature revision for encapsulated follicular variant of papillary thyroid carcinoma: A paradigm shift to reduce overtreatment of indolent tumors. *JAMA Oncol* 2016;2:1023–1029.
16. Xu B, Farhat N, Barletta JA, Hung YP, de Biase D, Casadei GP *et al.* Should subcentimeter non-invasive encapsulated, follicular variant of papillary thyroid carcinoma be included in the noninvasive follicular thyroid neoplasm with papillary-like nuclear features category? *Endocrine* 2018;59:143–150.
17. Xu B, Reznik E, Tuttle RM, Knauf J, Fagin JA, Katabi N *et al.* Outcome and molecular characteristics of non-invasive encapsulated follicular variant of papillary thyroid carcinoma with oncocytic features. *Endocrine* 2019;64:97–108.
18. Lloyd RV, Asa SL, LiVolsi VA, Sadow PM, Tischler AS, Ghossein RA *et al.* The evolving diagnosis of noninvasive follicular thyroid neoplasm with papillary-like nuclear features (NIFTP). *Hum Pathol* 2018;74:1–4.
19. Regalbuto C, Malandrino P, Tumminia A, Le Moli R, Vigneri R, Pezzino V. A diffuse sclerosing variant of papillary thyroid carcinoma: clinical and pathologic features and outcomes of 34 consecutive cases. *Thyroid* 2011;21:383–389.
20. Glomski K, Nose V, Faquin WC, Sadow PM. Metastatic follicular thyroid carcinoma and the primary thyroid gross examination: Institutional review of cases from 1990 to 2015. *Endocr Pathol* 2017;28:177–185.
21. Xu B, Scognamiglio T, Cohen PR, Prasad ML, Hasanovic A, Tuttle RM *et al.* Metastatic thyroid carcinoma without identifiable primary tumor within the thyroid gland: a retrospective study of a rare phenomenon. *Hum Pathol* 2017;65:133–139.
22. Lloyd RV, Osamura RY, Kloppel G, Rosai J. *WHO Classification of Tumours of Endocrine Organs (4th edition)*. Lyon, France: International Agency for Research on Cancer, 2017.
23. Volante M, Collini P, Nikiforov YE, Sakamoto A, Katudo K, Katoh R *et al.* Poorly differentiated thyroid carcinoma: The Turin proposal for the use of uniform diagnostic criteria and an algorithmic diagnostic approach. *Am J Surg Pathol* 2007;31:1256–1264.
24. Hiltzik D, Carlson DL, Tuttle RM, Chuai S, Ishill N, Shaha A *et al.* Poorly differentiated thyroid carcinomas defined on the basis of mitosis and necrosis: A clinicopathologic study of 58 patients. *Cancer* 2006;106:1286–1295.
25. Rivera M, Ricarte-Filho J, Patel S, Tuttle M, Shaha A, Shah JP *et al.* Encapsulated thyroid tumors of follicular cell origin with high grade features (high mitotic rate/tumor necrosis): A clinicopathologic and molecular study. *Hum Pathol* 2010;41:172–180.
26. Bongiovanni M, Mazzucchelli L, Giovanella L, Frattini M, Pusztaszeri M. Well-differentiated follicular patterned tumors of the thyroid with high-grade features can metastasize in the absence of capsular or vascular invasion: report of a case. *Int J Surg Pathol* 2014;22:749–756.
27. Nikiforov YE, Seethala RR. Anaplastic (undifferentiated) carcinoma. In: Nikiforov YE, Biddinger, PW Thompson, LD R. (eds.). *Diagnostic Pathology and Molecular Genetics of the Thyroid*. Philadelphia: Lippincott Williams and Wilkins, 2012.
28. Cameselle-Teijeiro J, Chan JK. Cribriform-morular variant of papillary carcinoma: A distinctive variant representing the sporadic counterpart of familial adenomatous polyposis-associated thyroid carcinoma? *Mod Pathol* 1999;12:400–411.

29. Xu B, Fuchs TL, Ahmadi S, Alghamdi M, Alzumaili B, Bani MA *et al.* International medullary thyroid carcinoma grading system: A validated grading system for medullary thyroid carcinoma. *J Clin Oncol* 2022;40:96–104.
30. Nikiforov YE, Baloch ZW, Hodak SP, Giordano TJ, Lloyd RV, Seethala RR *et al.* Change in diagnostic criteria for noninvasive follicular thyroid neoplasm with papillarylike nuclear features. *JAMA Oncol* 2018;4:1125–1126.
31. Jang E, Kim K, Jung CK, Bae JS, Kim JS. Clinicopathological parameters for predicting non-invasive follicular thyroid neoplasm with papillary features (NIFTP). *Ther Adv Endocrinol Metab* 2021;doi:10.1177/ 20420188211000500.
32. Cubero Rego D, Lee H, Boguniewicz A, Jennings TA. Noninvasive follicular thyroid neoplasm with papillary-like nuclear features (NIFTP) is rare, benign lesion using modified stringent diagnostic criteria: reclassification and outcome study. *Ann Diagn Pathol* 2020;44:151439.
33. Hershman J. Noninvasive follicular thyroid neoplasms with papillary-like nuclear features (NIFTP) show molecular and clinical similarity to follicular adenomas. *Clin Thyroidol* 2018;30:203–205.
34. Chuang HW, Wang JS, Tsai JW, Hsu CT, Lin KJ. Immunohistochemistry helps to distinguish noninvasive follicular thyroid neoplasm with papillary-like nuclear features/noninvasive encapsulated follicular variant of papillary thyroid carcinoma with other follicular thyroid lesions. *Medicina (Kaunas)* 2021;14:57:1246.
35. Elsans DA, Hussein MRA, Osman MH, Mohamed GA, Hosny G. Challenge in the pathological diagnosis of the follicular-patterned thyroid lesions. *Asian Pac J Cancer Prev* 2021;22:3365–3376.
36. Fu G, Polyakova O, Chazen RS, Freeman JL, Witterick IJ. Diagnostic value of galectin-3 in distinguishing invasive encapsulated carcinoma from noninvasive follicular thyroid neoplasms with papillary-like nuclear features (NIFTP). *Cancers (Basel)* 2021;13:2988.
37. Sadiq Q, Sekhri R, Dibaba DT, Zhao Q, Agarwal S. Hbme1 and ck19 expression in non-invasive follicular thyroid neoplasm with papillary-like nuclear features (NIFTP) vs other follicular patterned thyroid lesions. *World J Surg Oncol* 2021;19:143.
38. Paja M, Zafon C, Iglesias C, Ugalde A, Anda E, Pova A *et al.* Rate of non-invasive follicular thyroid neoplasms with papillary-like nuclear features depends on pathologist's criteria: A multicentre retrospective Southern European study with prolonged follow-up. *Endocrine* 2021;73:131–140.
39. Haugen BR, Alexander EK, Bible KC, Doherty MG, Mandel JS, Nikiforov EY *et al.* 2015 American Thyroid Association management guidelines for adult patients with thyroid nodules and differentiated thyroid cancer: The American Thyroid Association guidelines task force on thyroid nodules and differentiated thyroid cancer. *Thyroid* 2016;26:1–133.
40. Sobrinho-Simoes M, Eloy C, Magalhaes J, Lobo C, Amaro T. Follicular thyroid carcinoma. *Mod Pathol* 2011;24:S10–18.
41. Chetty R. Follicular patterned lesions of the thyroid gland: A practical algorithmic approach. *J Clin Pathol* 2011;64:737–741.
42. Kakudo K. How to handle borderline/precursor thyroid tumors in management of patients with thyroid nodules. *Gland Surg* 2018;7:S8–S18.

43. Kakudo K, Bai Y, Liu Z, Li Y, Ito Y, Ozaki T. Classification of thyroid follicular cell tumors: With special reference to borderline lesions. *Endocr J* 2012;59:1–12.
44. Zhu Y, Li Y, Jung CK, Liu Z, Jain D, Hang JF *et al.* Histopathologic assessment of capsular invasion in follicular thyroid neoplasms-an observer variation study. *Endocr Pathol* 2020;31:132–140.
45. Mohamed DA, Shamlola MM. Immunohistochemical and morphometrical evaluation of well-differentiated thyroid tumor of uncertain malignant potential. *Indian J Pathol Microbiol* 2019;62:17–23.
46. Baser H, Topaloglu O, Tam AA, Cakir B, Ersoy R, Kilicarslan A *et al.* Comparing Clinicopathologic and Radiographic findings between tt-ump, classical, and non-encapsulated follicular variants of papillary thyroid carcinomas. *Endocr Pathol* 2016;27:233–242.
47. Nechifor-Boila A, Borda A, Sassolas G, Catana R, Berger N, Hafdi-Nejjari Z *et al.* Thyroid tumors of uncertain malignant potential: Morphologic and imunohistochemical analysis of 29 cases. *Pathol Res Pract* 2015;211:320–325.
48. Nechifor-Boila A, Catana R, Loghin A, Radu TG, Borda A. Diagnostic value of hbme-1, CD56, Galectin-3 and Cytokeratin-19 in papillary thyroid carcinomas and thyroid tumors of uncertain malignant potential. *Rom J Morphol Embryol* 2014;55:49–56.
49. Yassin Fel Z. Diagnostic criteria of well differentiated thyroid tumor of uncertain malignant potential; a histomorphological and immunohistochemical appraisal. *J Egypt Natl Canc Inst* 2015;27:59–67.
50. Mete O, Asa SL, Bullock MJ, Carty SE, Hodak S, McHugh JB *et al.* Protocol for the examination of specimens from patients with carcinomas of the thyroid gland. Chicago, USA: College of American Pathologists, 2021.
51. Kakudo K, Wakasa T, Ohta Y, Yane K, Ito Y, Yamashita H. Prognostic classification of thyroid follicular cell tumors using Ki-67 labeling index: risk stratification of thyroid follicular cell carcinomas. *Endocr J* 2015;62:1–12.
52. Saltman B, Singh B, Hedvat CV, Wreesmann VB, Ghossein R. Patterns of expression of cell cycle/apoptosis genes along the spectrum of thyroid carcinoma progression. *Surgery* 2006;140:899–905; discussion 905–896.
53. Rivera M, Ricarte-Filho J, Knauf J, Shaha A, Tuttle M, Fagin AJ *et al.* Molecular genotyping of papillary thyroid carcinoma follicular variant according to its histological subtypes (encapsulated vs infiltrative) reveals distinct braf and ras mutation patterns. *Mod Pathol* 2010;23:1191–1200.
54. Chan J, Tumours of the Thyroid and Parathyroid Glands *In: Fletcher CDM (ed.). Diagnostic Histopathology of Tumours (5th edition)*. London,UK: Elsevier, 997–1098.
55. Thompson LD, Wieneke JA, Paal E, Frommelt RA, Adair CF, Heffess CS. A clinicopathologic study of minimally invasive follicular carcinoma of the thyroid gland with a review of the english literature. *Cancer* 2001;91:505–524.
56. Suster S. Thyroid tumors with a follicular growth pattern: Problems in differential diagnosis. *Arch Pathol Lab Med* 2006;130:984–988.
57. Mete O, Asa SL. Pathological definition and clinical significance of vascular invasion in thyroid carcinomas of follicular epithelial derivation. *Mod Pathol* 2011;24:1545–1552.

58. Cao J, Hu JL, Chen C, Wang QL, Fang XH *et al*. Vascular invasion is an independent prognostic factor for distant recurrence-free survival in papillary thyroid carcinoma: A matched-case comparative study. *J Clin Pathol* 2016;69:872–877.
59. Falvo L, Catania A, D'Andrea V, Marzullo A, Giustiniani MC, De Antoni E. Prognostic importance of histologic vascular invasion in papillary thyroid carcinoma. *Ann Surg* 2005;241:640–646.
60. Kim HJ, Sung JY, Oh YL, Kim HJ, Kim WS, Min KY *et al*. Association of vascular invasion with increased mortality in patients with minimally invasive follicular thyroid carcinoma but not widely invasive follicular thyroid carcinoma. *Head Neck* 2014;36:1695–1700.
61. Wreesmann VB, Nixon IJ, Rivera M, Katabi N, Shaba RA, Ganly I *et al*. Prognostic value of vascular invasion in well-differentiated papillary thyroid carcinoma. *Thyroid* 2015;25:503–508.
62. Xu B, Wang L, Tuttle RM, Ganly I, Ghossein R. Prognostic impact of extent of vascular invasion in low-grade encapsulated follicular cell-derived thyroid carcinomas: A clinicopathologic study of 276 cases. *Hum Pathol* 2015;46:1789–1798.
63. Collini P, Sampietro G, Pilotti S. Extensive vascular invasion is a marker of risk of relapse in encapsulated non-hurthle cell follicular carcinoma of the thyroid gland: A clinicopathological study of 18 consecutive cases from a single institution with a 11-year median follow-up. *Histopathology* 2004;44:35–39.
64. Ghossein RA, Hiltzik DH, Carlson DL, Patel S, Shaha A, Singh B *et al*. Prognostic factors of recurrence in encapsulated hurthle cell carcinoma of the thyroid gland: A clinicopathologic study of 50 cases. *Cancer* 2006;106:1669–1676.
65. Lang W, Choritz H, Hundeshagen H. Risk factors in follicular thyroid carcinomas. A retrospective follow-up study covering a 14-year period with emphasis on morphological findings. *Am J Surg Pathol* 1986;10:246–255.
66. Haddad RI, Bischoff L, Ball D, Kandeel F, Bernet V, Blomain E *et al*. Thyroid Carcinoma, Version 2.2022, NCCN Clinical Practice Guidelines in Oncology. *J Natl Compr Canc Netw* 2022;20:925–951.
67. Ortiz S, Rodriguez JM, Soria T, Perez-Flores D, Moreno J, Parrilla P. Extrathyroid spread in papillary carcinoma of the thyroid: Clinicopathological and prognostic study. *Otolaryngol Head Neck Surg* 2001;124:261–265.
68. Andersen PE, Kinsella J, Loree TR, Shaha AR, Shah JP. Differentiated carcinoma of the thyroid with extrathyroidal extension. *Am J Surg* 1995;170:467–470.
69. Carcangiu ML, Zampi G, Pupi A, Castagnoli A, Rosai J. Papillary carcinoma of the thyroid. A clinicopathologic study of 241 cases treated at the University of Florence, Italy. *Cancer* 1985;55:805–828.
70. McConahey WM, Hay ID, Woolner LB, van Heerden JA, Taylor WF. Papillary thyroid cancer treated at the mayo clinic, 1946 through 1970: Initial manifestations, pathologic findings, therapy, and outcome. *Mayo Clin Proc* 1986;61:978–996.
71. Ito Y, Tomoda C, Uruno T, Takamura Y, Matsuzuka F, Kuma K *et al*. Prognostic significance of extrathyroid extension of papillary thyroid carcinoma: Massive but not minimal extension affects the relapse-free survival. *World J Surg* 2006;30:780–786.

72. Ito Y, Tomoda C, Uruno T, Takamura Y, Miya A, Konayashi K *et al.* Minimal extrathyroid extension does not affect the relapse-free survival of patients with papillary thyroid carcinoma measuring 4 cm or less over the age of 45 years. *Surg Today* 2006;36:12–18.
73. Jukkola A, Bloigu R, Ebeling T, Salmela P, Blanco G. Prognostic factors in differentiated thyroid carcinomas and their implications for current staging classifications. *Endocr Relat Cancer* 2004;11:571–579.
74. Nixon IJ, Ganly I, Patel S, Palmer LF, Whitcher MM, Tuttle MR *et al.* The impact of microscopic extrathyroid extension on outcome in patients with clinical t1 and t2 well-differentiated thyroid cancer. *Surgery* 2011;150:1242–1249.
75. Radowsky JS, Howard RS, Burch HB, Stojadinovic A. Impact of degree of extrathyroidal extension of disease on papillary thyroid cancer outcome. *Thyroid* 2014;24:241–244.
76. Riemann B, Kramer JA, Schmid KW, Frankewitsch T, Schober O, Schicha H *et al.* Risk stratification of patients with locally aggressive differentiated thyroid cancer. Results of the msds trial. *Nuklearmedizin* 2010;49:79–84.
77. Shin JH, Ha TK, Park HK, Ahn SM, Kim HT, Choi SC *et al.* Implication of minimal extrathyroidal extension as a prognostic factor in papillary thyroid carcinoma. *Int J Surg* 2013;11:944–947.
78. Fukushima M, Ito Y, Hirokawa M, Miya A, Shimizu K, Miyauchi A. Prognostic impact of extrathyroid extension and clinical lymph node metastasis in papillary thyroid carcinoma depend on carcinoma size. *World J Surg* 2010;34:3007–3014.
79. Xu B, Ibrahimasic T, Wang L, Sabra MM, Tuttle MR, Ganly I *et al.* Clinicopathologic features of fatal non-anaplastic follicular cell-derived thyroid carcinomas. *Thyroid* 2016;26:1588–1597.
80. Kim JW, Roh JL, Gong G, Kim YS, Choi HS, Gong G *et al.* Extent of extrathyroidal extension as a significant predictor of nodal metastasis and extranodal extension in patients with papillary thyroid carcinoma. *Ann Surg Oncol* 2017;24:460–468.
81. Rivera M, Ricarte-Filho J, Tuttle RM, Ganly I, Shaha A, Fagin J *et al.* Molecular, morphologic, and outcome analysis of thyroid carcinomas according to degree of extrathyroid extension. *Thyroid* 2010;20:1085–1093.
82. Su HK, Wenig BM, Haser GC, Rowe EM, Asa LS, Baloch Z *et al.* Inter-observer variation in the pathologic identification of minimal extrathyroidal extension in papillary thyroid carcinoma. *Thyroid* 2016;26:512–517.
83. Hong CM, Ahn BC, Park JY, Jeong SY, Lee SW, Lee J. Prognostic implications of microscopic involvement of surgical resection margin in patients with differentiated papillary thyroid cancer after high-dose radioactive iodine ablation. *Ann Nucl Med* 2012;26:311–318.
84. Kluijfhout WP, Pasternak JD, Kwon JS, Lim J, Gosnell EJ, Khanafshar E *et al.* Microscopic positive tumor margin does not increase the risk of recurrence in patients with t1-t2 well-differentiated thyroid cancer. *Ann Surg Oncol* 2016;23:1446–1451.
85. Lang BH, Shek TW, Wan KY. Does microscopically involved margin increase disease recurrence after curative surgery in papillary thyroid carcinoma? *J Surg Oncol* 2016;113:635–639.

86. Wang LY, Ghossein R, Palmer FL, Nixon JI, Shaha RA, Shah PJ *et al.* Microscopic positive margins in differentiated thyroid cancer is not an independent predictor of local failure. *Thyroid* 2015;25:993–998.
87. Alpert EH, Wenig BM, Dewey EH, Su HK, Dos Reis L, Urken ML. Size distribution of metastatic lymph nodes with extranodal extension in patients with papillary thyroid cancer: A pilot study. *Thyroid* 2015;25:238–241.
88. Asanuma K, Kusama R, Maruyama M, Fujimori M, Amano J. Macroscopic extranodal invasion is a risk factor for tumor recurrence in papillary thyroid cancer. *Cancer Lett* 2001;164:85–89.
89. Ito Y, Hirokawa M, Jikuzono T, Miya A, Kobayashi K, Matsuzuka F *et al.* Extranodal tumor extension to adjacent organs predicts a worse cause-specific survival in patients with papillary thyroid carcinoma. *World J Surg* 2007;31:1194–1201.
90. Lango M, Flieder D, Arrangoiz R, Veloski C, Burtneess B, Mehra R *et al.* Extranodal extension of metastatic papillary thyroid carcinoma: Correlation with biochemical endpoints, nodal persistence, and systemic disease progression. *Thyroid* 2013;23:1099–1105.
91. Moritani S. Impact of invasive extranodal extension on the prognosis of patients with papillary thyroid carcinoma. *Thyroid* 2014;24:1779–1783.
92. Randolph GW, Duh QY, Heller KS, Steward LD, Tufano PR, Mandel JS *et al.* The prognostic significance of nodal metastases from papillary thyroid carcinoma can be stratified based on the size and number of metastatic lymph nodes, as well as the presence of extranodal extension. *Thyroid* 2012;22:1144–1152.
93. Ricarte-Filho J, Ganly I, Rivera M, Katabi N, Fu W, Tuttle MR *et al.* Papillary thyroid carcinomas with cervical lymph node metastases can be stratified into clinically relevant prognostic categories using oncogenic braf, the number of nodal metastases, and extra-nodal extension. *Thyroid* 2012;22:575–584.
94. Wu MH, Shen WT, Gosnell J, Duh QY. Prognostic significance of extranodal extension of regional lymph node metastasis in papillary thyroid cancer. *Head Neck* 2015;37:1336–1343.
95. Bullock MJ, Beitler JJ, Carlson DL, Fonseca I, Katabi N, Hunt LJ *et al.* Data set for the reporting of nodal excisions and neck dissection specimens for head and neck tumors: Explanations and recommendations of the guidelines from the international collaboration on cancer reporting. *Arch Pathol Lab Med* 2019;143:452–462.
96. Du E, Wenig BM, Su HK, Rowe EM, Haser CG, Baloch Z *et al.* Inter-observer variation in the pathologic identification of extranodal extension in nodal metastasis from papillary thyroid carcinoma. *Thyroid* 2016;26:816–819.
97. Tuttle M, Morris LF, Haugen B, Shah J, Sosa JA, Rohren E *et al.* Thyroid-differentiated and anaplastic carcinoma. *In: Amin MB, Edge SB, Greene FL, Byrd DR, Brookland RK, Washington MK eds. AJCC Cancer Staging Manual (8th edition)* Cham, Switzerland: Springer, 2017.
98. Nonaka D, Tang Y, Chiriboga L, Rivera M, Ghossein R. Diagnostic utility of thyroid transcription factors Pax8 and TTF-2 (FoxE1) in thyroid epithelial neoplasms. *Mod Pathol* 2008;21:192–200.
99. Milne D, Johnson SJ, Stephenson T, Poller D. *Tissue Pathways for Endocrine Pathology (3rd edition)*. London, UK: The Royal College of Pathologists, 2019. Available at: www.rcpath.org/profession/guidelines/cancer-datasets-and-tissue-pathways.html

100. Appukutty SJ, Paterson A, Patel NS, Duckworth A, Chan J, O'Donovan M *et al.* Thyroid diagnostic modalities (fine needle aspiration and core needle biopsy) with histology correlation: A tertiary centre experience. *J Clin Pathol* 2022;75:620–626.
101. Cross P, Chandra A, Giles T, Johnson S, Poller D, Stephenson T *et al.* *Guidance on the Reporting of Thyroid Cytology Specimens (2nd edition)*. London; UK: The Royal College of Pathologists, 2016. Available at: www.rcpath.org/uploads/assets/7d693ce4-0091-4621-97f79e2a0d1034d6/g089_guidance_on_reporting_of_thyroid_cytology_specimens.pdf
102. Na DG, Baek JH, Jung SL, Kim HJ, Yong J, Lee HJ *et al.* Core needle biopsy of the thyroid: 2016 consensus statement and recommendations from Korean Society of Thyroid Radiology. *Korean J Radiol* 2017;18:217–237.
103. Nixon IJ, Shaha AR, Patel SG. Surgical diagnosis: Frozen section and the extent of surgery. *Otolaryngol Clin North Am* 2014;47:519–528.
104. Grisales J, Sanabria A. Utility of routine frozen section of thyroid nodules classified as follicular neoplasm. *Am J Clin Pathol* 2020;153:210–220.
105. Cancer Genome Atlas Research Network. Integrated genomic characterization of papillary thyroid carcinoma. *Cell* 2014;159:676–690.
106. Volante M, Lam AK, Papotti M, Tallini G. Molecular pathology of poorly differentiated and anaplastic thyroid cancer: What do pathologists need to know? *Endocr Pathol* 2021;32:63–76.
107. Pozdeyev N, Gay LM, Sokol ES, Hartmaier R, Davis S, French J *et al.* Genetic analysis of 779 advanced differentiated and anaplastic thyroid cancers. *Clin Cancer Res* 2018;24:3059–3068.
108. Kumari S, Adewale R, Klubo-Gwiedzinska J. The molecular landscape of Hurthle cell thyroid cancer is associated with altered mitochondrial function—a comprehensive review. *Cells* 2020;9:1570.
109. Santoro M, Moccia M, Federico G, Carlomagno F. RET Gene Fusions in Malignancies of the Thyroid and Other Tissues. *Genes (Basel)* 2020;11:4:424.
110. Gandolfi G, Ragazzi M, Frasoldati A, Piana S, Ciarrocchi A, Sancisi V. TERT promoter mutations are associated with distant metastases in papillary thyroid carcinoma. *Eur J Endocrinol* 2015;172:403–413.
111. Teng L, Deng W, Lu J, Zhang J, Ren X, Duan H *et al.* Hobnail variant of papillary thyroid carcinoma: Molecular profiling and comparison to classical papillary thyroid carcinoma, poorly differentiated thyroid carcinoma and anaplastic thyroid carcinoma. *Oncotarget* 2017;8:22023–22033.
112. Ibrahimasic T, Xu B, Landa I, Dogan S, Middha S, Seshan V *et al.* Genomic alterations in fatal forms of non-anaplastic thyroid cancer: Identification of med12 and rbm10 as novel thyroid cancer genes associated with tumor virulence. *Clin Cancer Res* 2017;23:5970–5980.
113. Ragazzi M, Torricelli F, Donati B, Ciarrocchi A, Biase de D, Tallini G *et al.* Coexisting well-differentiated and anaplastic thyroid carcinoma in the same primary resection specimen: immunophenotypic and genetic comparison of the two components in a consecutive series of 13 cases and a review of the literature. *Virchows Arch* 2021;478:265–281.

114. Xu B, Fuchs T, Dogan S, Landa I, Katabu N, Fagin AJ *et al.* Dissecting anaplastic thyroid carcinoma: A comprehensive clinical, histologic, immunophenotypic, and molecular study of 360 cases. *Thyroid* 2020;30:1505–1517.
115. Barletta JA, Gilday SD, Afkhami M, Chau GN, Boisselier P, Bocklage T *et al.* Nutm1-rearranged carcinoma of the thyroid: A distinct subset of nut carcinoma characterized by frequent nsd3-nutm1 fusions. *Am J Surg Pathol* 2022;1:46:1706–1715.

Appendix A SNOMED coding

SNOMED topography should be recorded for the site of the tumour. SNOMED morphology codes should be recorded for the diagnosis/tumour morphology.

Versions of SNOMED prior to SNOMED CT will cease to be licenced by the International Health Terminology Standards Development Organisation from 26 April 2017. It is recognised that versions of SNOMED 2, SNOMED 3/RT and SNOMED CT are in use in the UK, these are therefore currently considered acceptable.

SNOMED Procedure codes (P codes in SNOMED 2/3/RT) should be recorded for the procedure. P codes vary according to the SNOMED system in use in different organisations, therefore local P codes should be recorded and used for audit purposes.

A list of applicable SNOMED morphology and topography codes should be provided.

Table 1: A comparison of SNOMED 2 or 3 with SNOMED CT codes – morphological codes

Note: This is not a comprehensive list of all malignancies and other codes should be used, as necessary.

Description	ICD-O/ SNOMED 2/ SNOMED 3.5	SNOMED CT terminology	SNOMED CT conceptid
Follicular cell–derived neoplasms			
Low-risk neoplasms			
Non-invasive follicular thyroid neoplasm with papillary-like nuclear features, NIFTP	M-83491	Non-invasive follicular thyroid neoplasm with papillary like nuclear features (morphologic abnormality)	789731003
Thyroid tumours of uncertain malignant potential			
Follicular tumour of uncertain malignant potential, FTUMP	M-83351	Follicular neoplasm of uncertain malignant potential (morphologic abnormality)	789471007
Well-differentiated tumour of uncertain malignant potential, WDTUMP	M-83481	Well differentiated tumour of uncertain malignant potential (morphologic abnormality)	789442006
Hyalinizing trabecular tumour, HTT	M-83361	Hyalinizing trabecular tumour (morphologic abnormality)	722214003
Malignant neoplasms			
Follicular thyroid carcinoma	M-83303	Follicular adenocarcinoma (morphologic abnormality)	5257006
Minimally invasive follicular thyroid carcinoma (capsular invasion only)	M-83353	Follicular carcinoma, minimally invasive (morphologic abnormality)	128671006
Encapsulated angioinvasive follicular thyroid carcinoma	M-83393	Follicular carcinoma, grossly encapsulated with angioinvasion (morphologic abnormality)	422350000

Widely invasive follicular thyroid carcinoma	M-83303	Follicular carcinoma, widely invasive (morphologic abnormality)	420301000
Invasive encapsulated follicular variant of papillary thyroid carcinoma	M-83433	Papillary carcinoma, follicular variant (morphologic abnormality)	21968007
Papillary thyroid carcinoma	M-82603	Papillary adenocarcinoma (morphologic abnormality)	4797003
Infiltrative follicular variant of papillary thyroid carcinoma	M-83403	Papillary carcinoma, follicular variant (morphologic abnormality)	21968007
Papillary microcarcinoma	M-83413	Papillary microcarcinoma (morphologic abnormality)	128674003
Columnar cell papillary thyroid carcinoma	M-83443	Papillary carcinoma, columnar cell (morphologic abnormality)	128677005
Classic papillary thyroid carcinoma	M-82603	Papillary adenocarcinoma (morphologic abnormality)	4797003
Encapsulated classic papillary thyroid carcinoma	M-83433	Encapsulated papillary carcinoma (morphologic abnormality)	703545003
Diffuse sclerosing papillary thyroid carcinoma	M-83503	Nonencapsulated sclerosing carcinoma (morphologic abnormality)	62681000
Tall cell papillary thyroid carcinoma	M-83443	Papillary carcinoma, tall cell (morphologic abnormality)	422198004
Oncocytic carcinoma of the thyroid	M-82903	Oxyphilic adenocarcinoma (morphologic abnormality)	57596004
Oncocytic papillary thyroid carcinoma.	M-83423	Papillary carcinoma, (morphologic abnormality)	128675002
Differentiated high grade thyroid carcinoma	M-83373	Follicular-derived carcinoma, high-grade (morphologic abnormality)	128673009
Poorly differentiated thyroid carcinoma	M-83373	Insular carcinoma (morphologic abnormality)	128673009
Anaplastic thyroid carcinoma	M-80203	Carcinoma, anaplastic (morphologic abnormality)	58248003
Thyroid C cell–derived carcinoma			
Medullary thyroid carcinoma	M-83453	Medullary carcinoma with amyloid stroma (morphologic abnormality)	128916007
Mixed medullary and follicular cell–derived carcinomas			
Mixed medullary-follicular carcinoma	M-83463	Mixed medullary-follicular carcinoma (morphologic abnormality)	128678000

Mixed medullary-papillary carcinoma	M-83473	Mixed medullary-papillary carcinoma (morphologic abnormality)	128679008
Salivary gland–type carcinomas of the thyroid			
Mucoepidermoid carcinoma	M-84303	Mucoepidermoid carcinoma (morphologic abnormality)	4079000
Secretory carcinoma	M-85023	Mammary analogue secretory carcinoma (morphologic abnormality)	734058001
Thyroid tumours of uncertain histogenesis			
Sclerosing mucoepidermoid carcinoma with eosinophilia	M-84303	Sclerosing mucoepidermoid carcinoma with eosinophilia (morphologic abnormality)	822964002
Cribriform morular thyroid carcinoma	M-82013	Papillary carcinoma, cribriform-morular (morphologic abnormality)	422238009
Thymic and thymic like tumours within the thyroid			
Spindle epithelial tumour with thymus-like elements (SETTLE)	M-85883	Spindle epithelial tumour with thymus-like element (morphologic abnormality)	128719006
Intrathyroidal thymic carcinoma	M-85893	Carcinoma showing thymus-like element (morphologic abnormality)	128720000
Embryonal thyroid neoplasms			
Thyroblastoma	M-89703	Malignant neoplasm, primary (morphologic abnormality)	86049000

Procedure codes (P)

These are used in SNOMED 2 and SNOMED 3 to distinguish biopsies, partial resections and radical resections to indicate the nature of the procedure. Local P codes should be recorded. At present, P codes vary according to the SNOMED system in use in different institutions.

Appendix B TNM classification of malignant tumours of the thyroid (UICC TNM 8)

The staging applies to all tumour types, including anaplastic carcinoma, which hitherto had automatically been staged as stage 4 irrespective of all other details. With TNM 8, those few anaplastic carcinomas that do not attain stage 4 by size or structures invaded are accorded a lower stage, just as though they had been a less aggressive cancer type.

Primary tumour (pT)

pTX	Primary tumour cannot be assessed
pT0	No evidence of primary tumour
pT1a	≤10 mm, limited to thyroid
pT1b	≤20 mm but >10 mm, limited to thyroid
pT2	>20 mm, ≤40 mm, limited to thyroid
pT3a	>40 mm, limited to thyroid
pT3b	Tumour of any size with gross extrathyroidal extension invading strap muscles (sternohyoid, sternothyroid or omohyoid muscles)
pT4a	Tumour invades beyond thyroid capsule and invades any of subcutaneous soft tissues, larynx, trachea, oesophagus, or recurrent laryngeal nerve
pT4b	Tumour invades prevertebral fascia, mediastinal vessels or encases carotid artery

UICC TNM 8 staging applies to carcinomas and includes papillary, follicular, oncocytic (Hürthle cell), poorly differentiated and anaplastic carcinomas.

Multifocal tumours (≥2 foci) of all histological types should be designated (m), the largest focus determining the classification, e.g., pT2(m).

Regional lymph nodes (pN)

pNX	Cannot assess regional lymph nodes
pN0	No regional nodes involved
pN1a	Metastasis in level VI (pretracheal, paratracheal and prelaryngeal/Delphian) lymph nodes
pN1b	Metastasis in other unilateral, bilateral, or contralateral cervical (levels I, II, III, IV or V) or retropharyngeal or superior mediastinal lymph nodes

Distant metastasis (M)

M0	No distant metastases
M1	Distant metastases

Residual primary tumour (R)

RX	Cannot assess presence of residual primary tumour
----	---

- R0 No residual primary tumour
- R1 Microscopic residual primary tumour
- R2 Macroscopic residual primary tumour

Clinical staging

This is mentioned for ease of reference as it may be discussed in the MDT meeting and in relation to clinical trials, but we recommend that pathology reports include only the pathological TNM staging. The translation of the pathological data into staging differs with the tumour type.

In papillary and follicular carcinoma, there is evidence that prognosis is poorer in older patients and therefore different criteria are applied to patients under 55 years from those to patients aged 55 years and older. In medullary carcinoma, no age stratification applies.

All undifferentiated/anaplastic tumours are regarded as categories within stage IV.

Papillary or follicular carcinoma* under 55 years

Stage I	Any T	Any N	M0
Stage II	Any T	Any N	M1

Papillary or follicular carcinoma* 55 years or over

Stage I	T1a, T1b, T2	N0	M0
Stage II	T3	N0	M0
	T1, T2, T3	N1	M0
Stage III	T4a	Any N	M0
Stage IVA	T4b	Any N	M0
Stage IVB	Any T	Any N	M1

Medullary carcinoma

Stage I	T1a, T1b	N0	M0
Stage II	T2, T3	N0	M0
Stage III	T1, T2, T3	N1a	M0
Stage IVA	T1, T2, T3	N1b	M0
	T4a	Any N	M0
Stage IVB	T4b	Any N	M0
Stage IVC	Any T	Any N	M1

Anaplastic/undifferentiated carcinoma

All are considered stage IV			
Stage IVA	T1, T2, T3a	N0	M0
Stage IVB	T1, T2, T3a	N1	M0
	T3b, T4a, T4b	Any N	M0
Stage IVC	Any T	Any N	M1

*Including papillary, follicular, poorly differentiated and Hürthle cell (oncocytic) carcinomas.

Appendix C Reporting proforma for carcinomas of the thyroid

Surname..... Forenames..... Date of birth..... Sex.....
Hospital..... Hospital no..... NHS/CHI no.....
Date of receipt..... Date of reporting..... Report no.....
Pathologist..... Surgeon.....

Clinical Information (select all that apply)

- Information not provided
Previous history of thyroid tumour or related abnormality , specify.....
Relevant biopsy/cytology results , specify.....
Imaging findings , specify.....
Previous surgery/therapy , specify.....
Relevant family history , specify....
Presence of clinical syndrome , specify.....
Other

Operative Procedure

- Not specified
Total thyroidectomy Near total thyroidectomy Hemithyroidectomy Lobectomy Isthmusectomy
*Partial excision , specify type if possible.....
Lymph node dissection , specify if available.....
Other , specify.....
*Anything less than a lobectomy excluding isthmusectomy, including substernal excision.

Operative Findings

- Not specified
Intra-operative macroscopic evidence of extrathyroidal extension
Yes , specify location and tissue invaded..... No Information not available
Intra-operative impression of completeness of excision
R0/R1 R2 , specify location..... Information not available
Other , specify.....

Specimens submitted (select all that apply)

- Not specified
Thyroid gland left right isthmus
Parathyroid gland(s)
Lymph nodes(s) , specify site(s) and laterality.....
Other , specify site(s) and laterality.....

Tumour focality

- Unifocal

Multifocal specify number of tumours in specimen (if >5 state such but no need to specify the number)

Cannot be assessed , specify.....

Tumour site (select all that apply) (For the most clinically relevant tumour)

Not specified

Lobe: left right isthmus pyramidal lobe

soft tissue or muscle , specify site(s) and laterality.....

Other , specify site(s) and laterality.....

Tumour dimensions

Maximum tumour dimension (largest tumour)mm

Additional dimensions (....mm xmm)

Cannot be assessed , specify.....

Histological Tumour Type (select all that apply)

Papillary thyroid carcinoma

Classic (usual, conventional)

Encapsulated classic subtype

Infiltrative follicular subtype

Clear cell subtype

Columnar cell subtype

Diffuse sclerosing subtype

Hobnail subtype

Oncocytic subtype

PTC with fibromatosis/fasciitis-like/desmoid stroma

Solid/trabecular subtype

Spindle cell subtype

Tall cell subtype

Warthin-like subtype

Other subtype , specify..... ..

Invasive encapsulated follicular variant papillary carcinoma (IEFVPTC)

IEFVPTC, minimally invasive

IEFVPTC, encapsulated angioinvasive

IEFVPTC, widely invasive

Follicular thyroid carcinoma (FTC)

FTC, minimally invasive

FTC, encapsulated angioinvasive

FTC, widely invasive

Oncocytic (Hürthle cell) carcinoma

oncocytic carcinoma, minimally invasive

oncocytic carcinoma, encapsulated angioinvasive

oncocytic carcinoma, widely invasive

- Follicular derived carcinoma, high grade
- Differentiated high grade thyroid carcinoma (DHGTC)
- Poorly differentiated thyroid carcinoma (PDTC)
- Anaplastic thyroid carcinoma
- Medullary thyroid carcinoma
- Mixed medullary and follicular cell derived thyroid carcinoma
- Mucoepidermoid carcinoma
- Secretory carcinoma of salivary gland type
- Sclerosing mucoepidermoid carcinoma with eosinophilia
- Cribiform-morular thyroid carcinoma
- Spindle epithelial tumour with thymus-like elements
- Intrathyroid thymic carcinoma
- Thyblastoma
- Other , specify.....

Histological Tumour Grade (Follicular Derived Tumours)

- Well differentiated
- Differentiated high grade
- Poorly differentiated
- Undifferentiated/anaplastic

Histological Tumour Grade (Medullary Carcinoma)

- Low grade
- High grade

Mitotic activity

- Not identified/low (<3 mitoses/2 mm²)
- High (≥ mitoses/2 mm²)
- High (≥ mitoses/2 mm²)
- Number of mitoses per 2 mm².....
- Cannot be assessed

Tumour encapsulation/circumscription

- Encapsulated
- Infiltrative
- Other , specify.....

Capsular invasion

- Not applicable
- Uncertain
- Not identified
- Present
- Cannot be assessed , specify.....

Lymphatic or blood vessel invasion

Not identified

Present

Type of vessel involved (select all that apply)

Blood vessel

Number of vessels involved, for encapsulated neoplasms, specify

Focal, 1-3 foci Extensive, \geq foci

Lymphatic

Small vessel, not otherwise classifiable

Extrathyroidal blood vessel invasion, Not identified Present

Cannot be assessed , specify.....

Necrosis

Not identified

Present

Extrathyroidal extension (select all that apply)

Cannot be assessed

Not identified

Invasion into perithyroid fibroadipose tissue

Invasion into skeletal muscle

Invasion into subcutaneous soft tissue, larynx, trachea, oesophagus or recurrent laryngeal nerve

Invasion into prevertebral fascia or encasing the carotid artery or mediastinal vessel

Margin status

Not involved , distance of tumour to nearest margin.....mm

Involved , specify anterior or posterior.....

Cannot be assessed , specify.....

Lymph node status

No nodes submitted or found

Number of lymph nodes examined.....

Not involved

Involved

Number of positive lymph nodes.....

Number cannot be determined

Location of involved lymph nodes, specify.....

Greatest dimension of largest lymph node with metastasis.....mm

Greatest dimension of largest metastatic focus in lymph node.....mm

Extranodal extension

Not identified

Present

Cannot be determined

C-cell hyperplasia (Medullary carcinoma only)

Not identified

Present

Unilateral

Bilateral

Coexistent pathology (select all that apply)

None identified

Follicular nodular disease

Diffuse hyperplasia

Dyshormonogenetic goitre

Chronic lymphocytic thyroiditis

Follicular adenoma

Oncocytic (Hürthle cell) adenoma

Noninvasive follicular thyroid neoplasm with papillary-like nuclear features (NIFTP)

Other , specify.....

Parathyroid gland status

Not identified

Present

Number of parathyroid gland(s) found.....

Normal

Involved by carcinoma

Hypercellular/enlarged

Ancillary studies

Not performed

Performed , specify.....

Histologically confirmed distant metastases

Not identified

Not assessed

Present , specify site(s)....

Pathological staging (UICC TNM 8th edition)

TNM Descriptors (only if applicable) (select all that apply)

m - multiple primary tumours

r - recurrent

y - post-therapy

Primary tumour (pT)*

TX Primary tumour cannot be assessed

T1 Tumour 2 cm or less in greatest dimension, limited to the thyroid

- T1a, tumour 1 cm or less in greatest dimension, limited to the thyroid
 - T1b, tumour more than 1 cm but not more than 2 cm in greatest dimension, limited to the thyroid
 - T2 Tumour more than 2 cm but not more than 4 cm in greatest dimension, limited to the thyroid
 - T3 Tumour more than 4 cm in greatest dimension, limited to the thyroid or with gross extrathyroidal extension invading only strap muscles (sternohyoid, sternothyroid, or omohyoid muscles)
 - T3a, tumour more than 4 cm in greatest dimension, limited to the thyroid
 - T3b, tumour of any size with gross extrathyroidal extension invading strap muscles (sternohyoid, sternothyroid, or omohyoid muscles)
 - T4 Includes gross extrathyroidal extension into major neck structures
 - T4a, tumour extends beyond the thyroid capsule and invades any of the following: subcutaneous soft tissues, larynx, trachea, oesophagus, recurrent laryngeal nerve
 - T4b, tumour invades prevertebral fascia, mediastinal vessels, or encases carotid artery
- *Including papillary, follicular, poorly differentiated, Hürthle cell (oncocytic) and anaplastic carcinomas.

Regional lymph nodes (pN)

- NX Regional lymph nodes cannot be assessed
- N0 No regional lymph node metastasis
- N1 Regional lymph node metastasis
 - N1a, metastasis in level VI (pretracheal, paratracheal, and prelaryngeal/Delphian lymph nodes) or upper/superior mediastinum
 - N1b, metastasis in other unilateral, bilateral, or contralateral cervical (levels I, II, III, IV or V) or retropharyngeal

Excision status: R0, R1 R2

Appendix D Reporting proforma for carcinomas of the thyroid in list format

Element name	Values	Implementation notes
Operative procedure	Multi-selection value list: <ul style="list-style-type: none"> • Not specified OR <ul style="list-style-type: none"> • Total thyroidectomy • Near total thyroidectomy • Hemithyroidectomy • Lobectomy • Isthmusectomy • Partial excision (specify type if possible) * • Lymph node dissection OR <ul style="list-style-type: none"> • Other, specify 	*Anything less than a lobectomy excluding isthmusectomy, including substernal excision.
Operative findings	Multi-selection value list: <ul style="list-style-type: none"> • Not specified OR Intra-operative macroscopic evidence of extrathyroidal extension <ul style="list-style-type: none"> • Yes, specify location and tissue invaded • No Information not available OR Intra-operative impression of completeness of excision <ul style="list-style-type: none"> • R0/R1 • R2, specify location • Information not available OR <ul style="list-style-type: none"> • Other, specify 	
Specimen(s) submitted	Multi-selection value list: <ul style="list-style-type: none"> • Not specified OR Thyroid gland <ul style="list-style-type: none"> • Left • Right • Isthmus Parathyroid gland(s) Lymph node(s), specify site(s) and laterality OR <ul style="list-style-type: none"> • Other, specify site(s) and laterality 	

Element name	Values	Implementation notes
Tumour focality	<ul style="list-style-type: none"> • Unifocal • Multifocal • Cannot be assessed, specify 	
Tumour site	<ul style="list-style-type: none"> • Not specified <p>OR</p> <ul style="list-style-type: none"> • Lobe <ul style="list-style-type: none"> – Left – Right – Isthmus – Pyramidal lobe – Soft tissue or muscle, specify site(s) and laterality <p>OR</p> <p>Other, specify site(s) and laterality</p>	For the most clinically relevant tumour.
Tumour maximum dimension	<ul style="list-style-type: none"> • Size (mm) of largest tumour • Cannot be assessed, specify 	
Histological tumour type	<p>Single selection value list:</p> <ul style="list-style-type: none"> • Papillary thyroid carcinoma <ul style="list-style-type: none"> – Classic (usual, conventional) – Encapsulated classic subtype – Infiltrative follicular subtype – Clear cell subtype – Columnar cell subtype – Diffuse sclerosing subtype – Hobnail subtype – Oncocytic subtype – PTC with fibromatosis/fasciitis-like/desmoid stroma – Solid/trabecular subtype – Spindle cell subtype – Tall cell subtype – Warthin-like subtype <p>OR</p> <p>Other subtype, specify</p> <ul style="list-style-type: none"> • Invasive encapsulated follicular variant papillary carcinoma (IEFVPTC) <ul style="list-style-type: none"> – IEFVPTC, minimally invasive – IEFVPTC, encapsulated angioinvasive – IEFVPTC, widely invasive • Follicular thyroid carcinoma (FTC) <ul style="list-style-type: none"> – FTC, minimally invasive – FTC, encapsulated angioinvasive – FTC, widely invasive 	Value list from the WHO Classification of Tumours: Pathology and Genetics of Tumours of Endocrine Organs (2022).

Element name	Values	Implementation notes
	<ul style="list-style-type: none"> • Oncocytic (Hürthle cell) carcinomas <ul style="list-style-type: none"> – Oncocytic carcinoma, minimally invasive – Oncocytic carcinoma, encapsulated angioinvasive – Oncocytic carcinoma, widely invasive • Follicular-derived carcinoma, high grade <ul style="list-style-type: none"> – Differentiated high grade thyroid carcinoma (DHGTC) – Poorly differentiated thyroid carcinoma (PDTC) • Anaplastic thyroid carcinoma • Medullary thyroid carcinoma • Mixed medullary and follicular cell derived thyroid carcinoma • Mucoepidermoid carcinoma • Secretory carcinoma of salivary gland type • Sclerosing mucoepidermoid carcinoma with eosinophilia • Cribriform morular thyroid carcinoma • Spindle epithelial tumour with thymus-like elements • Intrathyroid thymic carcinoma • Thyroblastoma <p>OR</p> <ul style="list-style-type: none"> • Other, specify 	
Histological tumour grade (follicular derived tumours)	<ul style="list-style-type: none"> • Well-differentiated • Differentiated high grade • Poorly differentiated • Undifferentiated/anaplastic 	
Medullary thyroid carcinoma	<ul style="list-style-type: none"> • Low grade • High grade 	
Mitotic activity ^b	<ul style="list-style-type: none"> • Not identified/low (<3 mitoses/2 mm²) • High (≥3 mitoses/2 mm²) • High (≥5 mitoses/2 mm²) <p>Number of mitoses per 2 mm²</p> <p>OR</p> <ul style="list-style-type: none"> • Cannot be assessed 	^b 2 mm ² approximates 10 HPFs on some microscopes.
Tumour encapsulation/ circumscription	<ul style="list-style-type: none"> • Encapsulated • Infiltrative • Other, specify 	

Element name	Values	Implementation notes
Capsular invasion	<ul style="list-style-type: none"> • Not applicable • Uncertain • Not identified • Present • Cannot be assessed, specify 	
Lymphatic or blood vessel invasion	<ul style="list-style-type: none"> • Not identified • Present <p>Type of vessel involved</p> <ul style="list-style-type: none"> – Blood vessel <p>Number of vessels involved, for encapsulated neoplasms, specify</p> <ul style="list-style-type: none"> – Focal, 1–3 foci – Extensive, ≥4 foci – Lymphatic – Small vessel, not otherwise classifiable <ul style="list-style-type: none"> • Cannot be assessed, specify 	
Necrosis	<ul style="list-style-type: none"> • Not identified • Present 	
Extrathyroidal extension	<ul style="list-style-type: none"> • Cannot be assessed • Not identified • Invasion into perithyroid fibroadipose tissue • Invasion into skeletal muscle • Invasion into subcutaneous soft tissue, larynx, trachea, oesophagus, or recurrent laryngeal nerve • Invasion into prevertebral fascia or encasing the carotid artery or mediastinal vessel 	
Margin status	<ul style="list-style-type: none"> • Not involved • Involved, specify (anterior or posterior) • Cannot be assessed, specify 	
Lymph node status	<ul style="list-style-type: none"> • No nodes submitted or found Number of lymph nodes examined ____ • Not involved • Involved Number of positive lymph nodes ____ • Number cannot be determined Location of involved lymph nodes, specify <p>Greatest dimension of largest lymph node with metastasis ____ mm</p>	

Element name	Values	Implementation notes
	<p>Greatest dimension of largest metastatic focus in lymph node ____ mm</p> <p>Extranodal extension</p> <ul style="list-style-type: none"> • Not identified • Present • Cannot be determined 	
Coexistent pathology	<ul style="list-style-type: none"> • None identified • Follicular nodular disease • Diffuse hyperplasia • Dys hormonogenetic goitre • Chronic lymphocytic thyroiditis • Follicular adenoma • Oncocytic (Hürthle cell) adenoma • Noninvasive follicular thyroid neoplasm with papillary-like nuclear features (NIFTP) • Other, specify 	
Parathyroid gland status	<ul style="list-style-type: none"> • Not identified • Present <p>Number of parathyroid gland(s) found ____</p> <ul style="list-style-type: none"> – Normal – Involved by carcinoma – Hypercellular/enlarged 	
Histologically confirmed distant metastases	<p>Not identified</p> <p>Not assessed</p> <p>Present, specify site(s)</p>	

Appendix E **Summary table – explanation of grades of evidence**
 (Modified from Palmer K *et al. BMJ* 2008;337:1832)

Grade (level) of evidence	Nature of evidence
Grade A	<p>At least one high-quality meta-analysis, systematic review of randomised controlled trials or a randomised controlled trial with a very low risk of bias and directly attributable to the target cancer type</p> <p>or</p> <p>A body of evidence demonstrating consistency of results and comprising mainly well-conducted meta-analyses, systematic reviews of randomised controlled trials or randomised controlled trials with a low risk of bias, directly applicable to the target cancer type.</p>
Grade B	<p>A body of evidence demonstrating consistency of results and comprising mainly high-quality systematic reviews of case-control or cohort studies and high-quality case-control or cohort studies with a very low risk of confounding or bias and a high probability that the relation is causal, and which are directly applicable to the target cancer type</p> <p>or</p> <p>Extrapolation evidence from studies described in A.</p>
Grade C	<p>A body of evidence demonstrating consistency of results and including well-conducted case-control or cohort studies and high-quality case-control or cohort studies with a low risk of confounding or bias and a moderate probability that the relation is causal, and which are directly applicable to the target cancer type</p> <p>or</p> <p>Extrapolation evidence from studies described in B.</p>
Grade D	<p>Non-analytic studies such as case reports, case series or expert opinion</p> <p>or</p> <p>Extrapolation evidence from studies described in C.</p>
Good practice point (GPP)	<p>Recommended best practice based on the clinical experience of the authors of the writing group.</p>

Appendix F AGREE II guideline monitoring sheet

The cancer datasets of The Royal College of Pathologists comply with the AGREE II standards for good quality clinical guidelines (www.agreetrust.org). The sections of this dataset that indicate compliance with each of the AGREE II standards are indicated below.

AGREE standard	Section of guideline
Scope and purpose	
1 The overall objective(s) of the guideline is (are) specifically described	Introduction
2 The health question(s) covered by the guideline is (are) specifically described	Introduction
3 The population (patients, public, etc.) to whom the guideline is meant to apply is specifically described	Foreword
Stakeholder involvement	
4 The guideline development group includes individuals from all the relevant professional groups	Foreword
5 The views and preferences of the target population (patients, public, etc.) have been sought	Foreword
6 The target users of the guideline are clearly defined	Introduction
Rigour of development	
7 Systematic methods were used to search for evidence	Foreword
8 The criteria for selecting the evidence are clearly described	Foreword
9 The strengths and limitations of the body of evidence are clearly described	Foreword
10 The methods for formulating the recommendations are clearly described	Foreword
11 The health benefits, side effects and risks have been considered in formulating the recommendations	Foreword and Introduction
12 There is an explicit link between the recommendations and the supporting evidence	All sections
13 The guideline has been externally reviewed by experts prior to its publication	Foreword
14 A procedure for updating the guideline is provided	Foreword
Clarity of presentation	
15 The recommendations are specific and unambiguous	All sections
16 The different options for management of the condition or health issue are clearly presented	All sections
17 Key recommendations are easily identifiable	All sections
Applicability	
18 The guideline describes facilitators and barriers to its application	Foreword
19 The guideline provides advice and/or tools on how the recommendations can be put into practice	Appendices
20 The potential resource implications of applying the recommendations have been considered	Foreword
21 The guideline presents monitoring and/or auditing criteria	13
Editorial independence	
22 The views of the funding body have not influenced the content of the guideline	Foreword
23 Competing interest of guideline development group members have been recorded and addressed	Foreword