



# Standards and datasets for reporting cancers

## Dataset for histopathological reporting of vulval carcinomas

November 2023

**Authors:** Dr Asma Faruqi, Barts Health NHS Trust, London  
Dr Brian Rous, Cambridge University NHS Foundation Trust, Cambridge

<b>Unique document number</b>	G070
<b>Document name</b>	Dataset for histopathological reporting of vulval carcinomas
<b>Version number</b>	5
<b>Produced by</b>	Dr Asma Faruqi and Dr Brian Rous, on behalf of the Royal College of Pathologists' Working Group for Cancer Services. The authors are specialist gynaecological pathologists. Dr Faruqi has sat on committees relevant to quality assurance and policy in gynaecological pathology. Dr Rous is a gynaecological pathologist.
<b>Date active</b>	November 2023 <b>(to be implemented within 3 months)</b>
<b>Date for review</b>	November 2026
<b>Comments</b>	<p>This document will supersede the <i>Dataset for histological reporting of vulval neoplasms (4th edition)</i>, published in 2018. In accordance with the College's pre-publications policy, this document was on The Royal College of Pathologists' website for consultation from 25 July to 22 August 2023. Responses and authors' comments are available to view on request.</p> <p><b>Dr Michael Eden</b> <b>Acting Clinical Lead for Guideline Review</b></p>



The Royal College of Pathologists  
6 Alie Street, London, E1 8QT  
Tel: 020 7451 6700  
Fax: 020 7451 6701  
Web: [www.rcpath.org](http://www.rcpath.org)

Registered charity in England and Wales, no. 261035  
© 2023, The Royal College of Pathologists

This work is copyright. You may download, display, print and reproduce this document for your personal, non-commercial use. Requests and inquiries concerning reproduction and rights should be addressed to The Royal College of Pathologists at the above address. First published: 2023.

## Contents

Foreword.....	3
1 Introduction.....	4
2 Clinical information required on the specimen request form.....	7
3 Preparation of specimens before dissection of resection specimens .....	8
4 Specimen handling and block selection for resection specimens.....	8
5 Core data items for resection specimens .....	12
6 Non-core data items .....	22
7 Small biopsies .....	23
8 Diagnostic coding and staging.....	23
9 Criteria for audit.....	23
10 References.....	24
Appendix A FIGO and TNM staging of vulval carcinoma.....	33
Appendix B WHO classification and SNOMED codes .....	36
Appendix C Reporting proforma for vulval cancer resection specimens in list format..	39
Appendix D Reporting proforma for vulval cancer biopsy specimens in list format .....	48
Appendix E Summary table – Explanation of levels of evidence .....	51
Appendix F AGREE II compliance monitoring sheet .....	52



NICE has accredited the process used by the Royal College of Pathologists to produce its guidelines. Accreditation is valid for 5 years from 25 July 2017. More information on accreditation can be viewed at [www.nice.org.uk/accreditation](http://www.nice.org.uk/accreditation).

For full details on our accreditation visit: [www.nice.org.uk/accreditation](http://www.nice.org.uk/accreditation).

## Foreword

The cancer datasets published by The Royal College of Pathologists (RCPATH) are a combination of textual guidance, educational information and reporting proformas. The datasets enable pathologists to grade and stage cancers in an accurate, consistent manner in compliance with international standards and provide prognostic information, thereby allowing clinicians to provide a high standard of care for patients and appropriate management for specific clinical circumstances. This guideline has been developed to cover most common circumstances. However, we recognise that guidelines cannot anticipate every pathological specimen type and clinical scenario. Occasional variation from the practice recommended in this guideline may therefore be required to report a specimen in a way that maximises benefit to the patient.

Each dataset contains core data items that are mandated for inclusion in the Cancer Outcomes and Services Dataset (COSD – previously the National Cancer Data Set) in England. Core data items are items that are supported by robust published evidence and are required for cancer staging, optimal patient management and prognosis. Core data items meet the requirements of professional standards (as defined by the Information Standards Board for Health and Social Care [ISB]) and it is recommended that at least 90% of reports on cancer resections should record a full set of core data items. Other non-core data items are described. These may be included to provide a comprehensive report or to meet local clinical or research requirements. All data items should be clearly defined to allow the unambiguous recording of data.

The following stakeholders were contacted to consult on this document:

- Working Group of the British Association of Gynaecological Pathologists (BAGP), comprising BAGP Council and co-opted members
- British Gynaecological Cancer Society (BGCS)
- British Society for the Study of Vulval Diseases.

The information used to develop this dataset was obtained by undertaking a systematic search of Pubmed from January 2015 to July 2023. Key terms searched included ‘vulval carcinoma’, ‘vulval precursor lesions’ and literature pertaining to guidelines and managements. In addition, International Collaboration on Cancer Reporting (ICCR) guidelines, abstracts from selected conference proceedings (including the BAGP Annual Scientific Conference, European Society of Gynaecological Oncology and United States

and Canadian Academy of Pathology) were screened. Published evidence was evaluated using modified SIGN guidance (see Appendix E). Consensus of evidence in the guideline was achieved by expert review. Gaps in the evidence will be identified by College members via feedback received during consultation.

No major organisational changes have been identified that would hinder the implementation of the dataset.

A formal revision cycle for all cancer datasets takes place on a 3-yearly basis. However, each year, the College will ask the author of the dataset, in conjunction with the relevant subspecialty advisor to the College, to consider whether or not the dataset needs to be updated or revised. A full consultation process will be undertaken if major revisions are required, i.e. revisions to core data items (the only exception being changes to international tumour grading and staging schemes that have been approved by the Specialty Advisory Committee on Cellular Pathology and affiliated professional bodies; these changes will be implemented without further consultation). If minor revisions or changes to non-core data items are required, an abridged consultation process will be undertaken whereby a short note of the proposed changes will be placed on the College website for two weeks for members' attention. If members do not object to the changes, the short notice of change will be incorporated into the dataset and the full revised version (incorporating the changes) will replace the existing version on the College website.

The dataset has been reviewed by the Professional Guidelines team, Working Group on Cancer Services and Lay Advisory Group and was placed on the College website for consultation with the membership from 25 July to 22 August 2023. All comments received from the Working Group and membership were addressed by the author to the satisfaction of the Chair of the Working Group and the Clinical Lead for Guideline Review.

This dataset was developed without external funding to the writing group. The College requires the authors of datasets to provide a list of potential conflicts of interest; these are monitored by the Professional Guidelines team and are available on request. The authors have declared that they have no conflicts of interest.

## 1 Introduction

This dataset is intended to be used for the reporting of all carcinomas of vulval skin and mucosa only. For vulval melanomas, the *Dataset for the histological reporting of primary cutaneous malignant melanoma and regional lymph nodes*<sup>1</sup> is recommended.

In the context of gynaecological malignancies, vulval carcinoma is relatively rare; nevertheless, there has been an increase over the past two decades. Most of the statistics available use the term 'vulval cancer' but, as the majority of vulval cancers are carcinomas, the data are relevant in the context of this dataset. Between 2016 and 2018, there were around 1,400 new cases diagnosed in the UK every year and in 2018 there were 474 deaths from vulval cancer.<sup>2</sup> Vulval cancer is associated with significant morbidity and mortality, particularly in older women where the disease is more likely to present at a later stage.<sup>3</sup> The incidence increases with age, rising steeply after 80 years. Since 1990, there has been a statistically significant increase in incidence in women between the ages of 25 to 69 years, which has been demonstrated in a number of studies.

When analysing these data, it is useful to consider the bimodal pathway in the development of vulval neoplasia;<sup>4-6</sup> broadly speaking, tumours in the younger age group are associated with high-risk human papilloma virus (HPV) infection and those in older women present on a background of inflammatory dermatoses, especially lichen sclerosis.<sup>7,8</sup> With the increased incidence of HPV-related neoplasia at other sites (throat, penis, anus), it is reasonable to assume that the increase in vulval neoplasia in younger women is likely to be HPV-related.

Primary surgery is the treatment choice for vulval cancer and in the UK; about 70% of patients undergo surgical resection as part of their cancer treatment.<sup>2</sup>

Prognostic features in vulval carcinoma are the site and size of the lesion, the depth of invasion or alternatively tumour thickness, the number of involved lymph nodes, the size of the nodal deposits, extranodal spread, lymphovascular space invasion and HPV status.

## **1.1 Changes in the 5th edition**

- Inclusion of only 1 set of tumour measurements (previously, macroscopic and microscopic were included) in line with ICCR recommendations.<sup>9</sup>
- This revision of the last vulval cancer dataset published in 2018 incorporates entities included in the WHO classification of female genital tumours (2020).<sup>10</sup>
- Updated FIGO (2021) staging, including new guidance on measurement of depth of invasion.<sup>11</sup>
- If more than one tumour is present, each should be should be separately staged with separate datasets filled in. In line with ICCR recommendations, lymph nodes need only be mentioned once.

- Further details on precursor lesions.
- Interpretation of ancillary tests.
- Updated recommendations for handling and reporting sentinel lymph nodes (SLN).
- Updated recommendations on margin measurement.
- SNOMED-CT coding.

## **1.2 Target users and health benefits of this guideline**

The dataset is primarily intended for use by consultant and other pathologists when reporting resection specimens of vulval cancers. Surgeons and oncologists can refer to the dataset when interpreting histopathology reports. The dataset should be available at multidisciplinary team (MDT) meetings for recording of accurate information and to inform discussion. It can also be used to assist in clinical trials. Many of the data items are collected for epidemiological analysis by Cancer Registries.

## **1.3 Precursor disease: vulval intraepithelial neoplasia**

### **1.3.1 HPV-associated vulval intraepithelial neoplasia**

The nomenclature of precursor lesions in HPV-related neoplasia includes the terms usual type vulval intraepithelial neoplasia (VIN) and classical VIN. The terminology recommended by the World Health Organization (WHO) and the LAST project is low-grade squamous intraepithelial lesion (LSIL), which includes HPV-related changes and VIN1, and high-grade squamous intraepithelial lesion (HSIL), referring to VIN2/3, Bowen's disease and Bowenoid dysplasia.<sup>10,12</sup> In the UK, VIN1, 2 and 3 are still used and well understood by the clinical team managing the patient; in the context of vulval neoplasia, their use is not proscribed but LSIL/HSIL may be added in line with WHO recommendations. The risk factors are similar to those involved in cervical intraepithelial neoplasia, infection with high risk HPV (usually subtypes 16 and 18), immunosuppression and smoking. Multifocality with concomitant or subsequent intraepithelial neoplasia of the cervix, vagina, anal and perianal regions can also occur.

### **1.3.2 HPV-independent vulval intraepithelial neoplasia**

Differentiated VIN (dVIN) is often seen in the older age group on a background of inflammatory dermatoses, such as lichen sclerosus (LS). It is characterised by basal cell atypia and abnormal keratinocyte differentiation. Many, but not all, of these lesions are associated with *TP53* mutation. LS is not regarded as a precursor lesion; however, it is a

significant risk factor and increases the risk of recurrence if incompletely excised.<sup>13,14</sup> All diagnoses of dVIN should be accompanied by a comment on p53 (mutation-type or wild-type).

Differentiated exophytic lesion (deVIL) and vulval acanthosis with altered differentiation (VAAD) are regarded as subtypes of HPV-independent VIN. These have overlapping morphology and are associated with HPV-independent carcinoma, including verrucous carcinoma. They are characterised by acanthosis, thick hyperkeratosis, an often verruciform architecture, cytoplasmic maturation and generally lack the basal atypia encountered in dVIN. In VAAD, there is loss of the granular layer accompanied by multilayered parakeratosis and cytoplasmic pallor of the superficial epithelium. Unlike dVIN, these lesions do not show *TP53* mutation but have shown other mutations (*ARID2*, *PIK3CA* and *HRAS*). Since these lesions lack significant nuclear atypia, they can be difficult to recognise and dermatoses, such as hypertrophic LS, enter the differential diagnosis. Close attention to the history and liaison with clinician is required.<sup>7,8,15–17</sup>

There is no overall consensus regarding terminology for these p53-wild type lesions. One proposal is that they should be termed HPV-independent p53-wild-type verruciform acanthotic vulvar intraepithelial neoplasia (HPVi(p53wt) vaVIN).<sup>18</sup> Another proposal is to refer to them as vulval aberrant maturation (VAM).<sup>19</sup> Neither is universally accepted; however, regardless of the term used, it is important to emphasise that they are HPV-independent precursors and p53 wild-type. This should be stated clearly in the conclusion.

## 2 Clinical information required on the specimen request form

The specimen request form should include:

- full patient details
- history including results of previous biopsies/cytology and any prior adjuvant therapy (chemotherapy, radiotherapy or chemoradiation)
- details of operative procedure
- details of specimen orientation, for example documentation of any sutures used for orientation diagram, including orientation of vaginal, urethral and anal margins, if present.

### **3 Preparation of specimens before dissection of resection specimens**

- A photographic record or diagram of the orientated specimen is helpful as the blocks taken can be marked upon it and retained with the patient's record.
- Large specimens may be pinned onto a cork board prior to fixation.
- Surgical margins should be inked.

### **4 Specimen handling and block selection for resection specimens**

#### **4.1 Macroscopic description**

This should include:

- size of the specimen measured in millimetres and in three dimensions
- background skin abnormalities
- confirmation of the presence of any orientation sutures and any ink applied to orientate.

#### **4.2 Block selection**

This should include:

- adequate tumour sampling (a representative megablock may be helpful)
- sampling of the closest margin(s) to the tumour
- representative blocks of any non-neoplastic epithelial abnormality
- any other incidental abnormality.

#### **4.3 Lymph nodes**

Inguinofemoral (groin) lymph node resection is not usually performed if the depth of invasion is less than 1 mm and the horizontal size is less than 20 mm (FIGO stage IA), as studies have shown that there is a very low risk of nodal metastases in these patients.<sup>20</sup>

The following should be observed during lymph node resection.



- All lymph nodes must be sampled with an adequate rim of surrounding tissue.
- In most cases, the nodes can be identified by careful palpation. The remaining adipose tissue should be processed even if there are no palpable nodes. Where there is excessive adipose tissue, it would be reasonable to sample up to 5 additional cassettes; if no lymph nodes are retrieved by these methods, all the adipose tissue should be sampled.
- If a node has macroscopic tumour involvement, one or more representative blocks may be taken after careful examination. The presence of extracapsular extension makes the tumour FIGO stage IIIC at least; if there is any doubt about this, the entire node should be submitted for examination.
- If a node appears normal, it should be submitted in its entirety.
- Lymph nodes greater than 4 mm should be serially sectioned at 2 mm intervals perpendicular to the long axis.
- Smaller nodes may be embedded in their entirety or after bisection.

#### **4.4 Sentinel lymph nodes**

Complete inguinofemoral lymph node dissection is associated with considerable morbidity and, therefore, SLN excision in the treatment of early stage vulval carcinoma is regarded as the standard of care.<sup>21–26</sup>

The criteria for selection include unifocality, a tumour size of 40 mm or less and no clinically suspicious inguinofemoral nodes. Intraoperative frozen sectioning of these lymph nodes may lead to tissue loss and, therefore, examination of paraffin-embedded tissue is recommended.

The following is recommended practice.

- All nodal tissue is sampled.
- If more than 1 lymph node is retrieved, then each lymph node must be clearly labelled and submitted in a separate cassette.
- Lymph nodes larger than 4 mm are sliced perpendicular to the long axis at 2 mm intervals. Each slice is placed face down with the equivalent face for each slice.
- Multiple slices may be submitted per cassette; however, care should be taken not to overcrowd the cassette and a maximum of 3 slices is recommended.

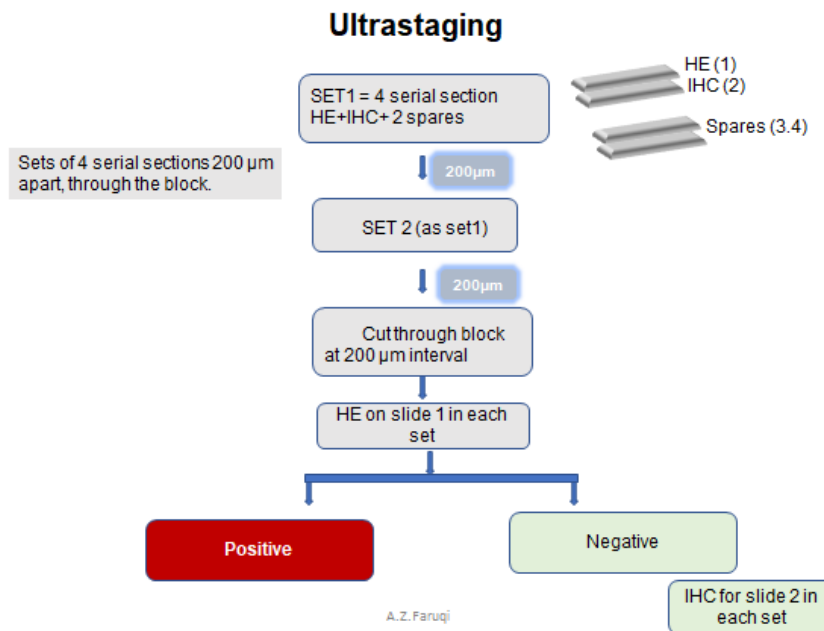
- Haematoxylin and eosin stains (H&E) are performed on each block.
- It is essential to examine a full face of the tissue so that the sub-capsular sinus is evident.
- If metastasis is confirmed, the largest deposit is measured and no further action is required.
- If there is no evidence of nodal metastasis, ultrastaging is recommended.

#### **4.4.1 Ultrastaging**

This is a labour-intensive procedure, both in terms of laboratory workload and consultant time. Therefore, it requires prior discussion and agreement between the surgical and pathology teams and adequate support in terms of costing to reflect this. The current evidence indicates it is more effective at identifying micrometastases than routine sampling. A variety of methods have been employed for ultrastaging and there is no consensus about the most effective protocol. Various studies have ultrasectioned the nodes at 500  $\mu\text{m}$ , 400  $\mu\text{m}$ , 200  $\mu\text{m}$  and 40  $\mu\text{m}$ .<sup>27–30</sup> Mathematical models have shown that the probability of detecting metastases of 0.25 mm is estimated to be above 90% if the node is ultrasectioned at 200–250  $\mu\text{m}$  step sections.<sup>31,32</sup>

The protocol outlined in the BAGP and BGCS consensus document<sup>33</sup> recommends the following if the first H&E is negative (Figure 1).

- Sets of 4 serial sections are cut 200  $\mu\text{m}$  apart all the way through the block.
- Slide 1 of each set is stained for H&E.
- If positive, no further action is required.
- If negative, proceed to immunohistochemistry on slide 2 from each set using a broad spectrum cytokeratin such as AE1/3.
- The remaining two slides in each set are spares.



**Figure 1: The BAGP protocol for ultrastaging if the first H&E is negative.**

The size of lymph node metastases has implications for prognosis and treatment. Ultrastaging may bring to light very small tumour deposits.<sup>34–36</sup> Using the size criteria recommended by FIGO, the following terminology is recommended.<sup>11</sup>

- Macrometastasis – greater than 2 mm.
- Micrometastasis – 0.2–2 mm.
- Isolated tumour cells – less than 0.2 mm. These are presently considered as negative for metastatic disease. Nevertheless, it is important to include the presence of ITC in the final conclusion. It is noted that the 2023 ESGO guidelines recommend additional treatment of the involved inguinofemoral area.<sup>37</sup>

The report should state the maximum size of the deposit in millimetres. The presence of extracapsular extension should be reported.

*[Level of evidence B – Presence of lymph node metastasis, size of lymph node metastasis and presence of extracapsular extension are independent prognostic variables.]*

## 5 Core data items for resection specimens

### 5.1 Clinical

#### 5.1.1 History

Any history of previous vulval carcinoma and/or precursor lesions and/or inflammatory dermatoses should be recorded, as well as previous surgery and/or adjuvant therapy.

#### 5.1.2 Operative procedure

Wide local excision refers to removal of the full thickness of vulval skin and/or mucosa with preservation of subcutaneous fat and other deep tissues (older terminologies include partial vulvectomy, superficial vulvectomy, skinning vulvectomy). Wide local excision is usually performed for pre-invasive or non-malignant lesions or for diagnostic purposes where cancer has not been ruled out.

Radical vulvectomy (partial or total) is usually performed for biopsy-confirmed invasive carcinoma and involves removing the vulval tissue down to the deep fascia. Radical vulvectomy may include removal of the clitoris with the prepuce, the labia majora, labia minora, a portion of vagina, urethra and/or anus. Orientation of the specimen is essential to evaluate margin status. It is important for the surgeon to assist in this by placing appropriate sutures and ideally providing a diagram or photograph.

Wide local excision and radical vulvectomy procedures will be tailored depending on the tumour size, pathological diagnosis, patient wishes/expectations, likely impact on psychosexual function and tumour location with respect to proximity to other vital structures.

*[Level of evidence – GPP.]*

### 5.2 Macroscopy

#### 5.2.1 Specimen size

Documentation of specimen size in 3 dimensions in millimetres allows correlation between clinical appearances of the specimen, macroscopic assessment and microscopic assessment, reducing the risk of laboratory error. It also gives clinicians dealing with the patient an indication as to how radical the resection was.

*[Level of evidence – GPP.]*

## 5.2.2 Tumour site

The report should include the anatomical subsites involved, the laterality (left/right/midline) and the extension into any adjacent structures. The anatomical subsites (labium majus, labium minus, central, clitoris) of the vulva that are involved by squamous cell carcinoma (SCC) have been shown to have prognostic significance. Due to the pattern of lymphatic drainage, patients with midline tumours, clitoral involvement and anterior labium minus tumours have worse survival.<sup>38</sup>

*[Level of evidence D – Site of involvement has independent prognostic value.]*

## 5.3 Tumour dimensions

### 5.3.1 Maximum horizontal dimension

Size is an important prognostic factor and is included in FIGO staging.<sup>11</sup> For large specimens, it may not be practical to measure microscopic size across multiple slides; in these circumstances, the macroscopic size may be more accurate.

The maximum horizontal dimension is measured parallel to the skin/and or mucosal surface. All measurements should be in millimetres. The final pathology report should contain only 1 set of measurements after correlation between both macroscopic and microscopic assessment.

*[Level of evidence B – Tumour size is an independent prognostic variable.]*

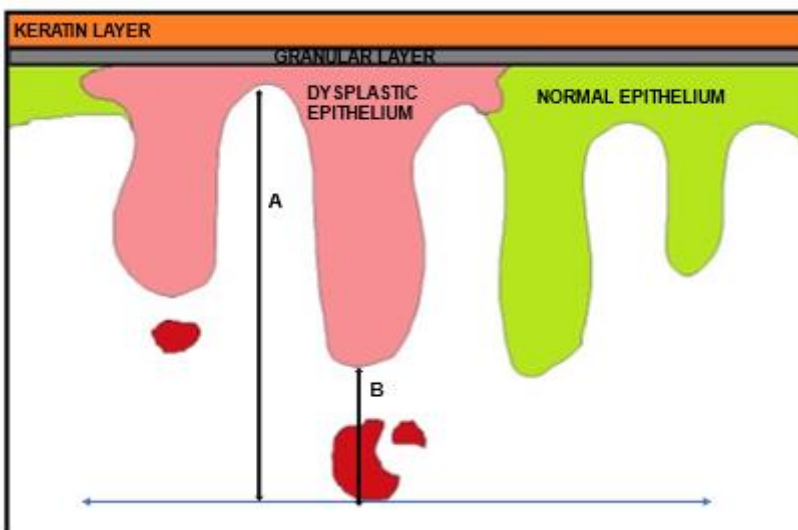
### 5.3.2 Depth of invasion

Accurate measurement of invasion requires a calibrated ocular eyepiece or similar method or use of a calibrated digital pathology system. Many histopathologists may not have access to these; the Vernier scale present on the microscope can be used instead, although it may sometimes be difficult to measure perpendicularly from the surface using this method.

The new FIGO 2021 staging system has introduced a different method for measurement of depth of invasion, which has been implemented since 01 January 2022.

- Prior to 01/01/2022 – depth of invasion was measured in millimetres from the adjacent most superficial dermal papilla to the deepest point of invasion (see A in Figure 2).
- From 01/01/2022 – depth of invasion is measured from the basement membrane of the deepest adjacent dysplastic (tumour free) rete ridge or the nearest dysplastic rete ridge to the deepest point of invasion (see B in Figure 2).<sup>39,40</sup>

- It is noted that the most recent guidelines from European Society of Gynaecological Oncology (ESGO) recommend the FIGO 2009 method of measurement (Option A in the diagram), on the basis that more prospective studies are required before the new method is adopted.<sup>37</sup> The number of cases that would be downstaged by the use of FIGO 2021 is extremely low and as FIGO 2021 has been used in the UK since 01/01/2022 it is appropriate to continue using it.
- In extremely exceptional cases where there are other adverse prognostic factors present and where the tumour would be upstaged using the old method, a detailed evaluation is recommended. This includes processing of further tissue from the tumour and examination of extra levels; if the findings remain the same and after discussion at the multidisciplinary meeting, both stages may be included in the final report. Use of both staging systems should not be the norm. If the 2009 staging system has been used with regard to further treatment, both stages should be included in the conclusion together with a comment about why the 2009 stage was considered more appropriate.



**Figure 2: Measurement of depth of invasion in vulval carcinoma. A. Conventional method (FIGO, 2009): from the adjacent most superficial dermal papilla to the deepest point of invasion. B. Recommended method (FIGO, 2021): from the basement membrane of the deepest adjacent dysplastic rete peg to the deepest point of invasion.**

*[Level of evidence B – Depth of invasion is an independent prognostic factor.]<sup>20,41,42</sup>*

## 5.4 Microscopy

### 5.4.1 Histological tumour type

#### Squamous cell carcinoma

Squamous cell carcinoma (SCC) of the vulva is the most common vulval malignancy. Tumour type determines biological behaviour of the tumour; for example, in contrast to SCC, basal cell carcinoma is highly unlikely to metastasise.<sup>43</sup>

Traditional histologic subtyping of SCC, using terms such as keratinising, non-keratinising, basaloid and warty, has been superseded by human papillomavirus (HPV) status as the major determinant of classification. Vulval SCC is now divided into HPV-associated and HPV-independent types.

HPV-independent SCC has a worse prognosis with significantly worse recurrence-free and overall survival compared to HPV-associated SCC.<sup>17,44–46</sup> There is also growing evidence that HPV-independent SCC is less responsive to radiotherapy.<sup>47,48</sup>

HPV-associated SCC is secondary to persistent infection by oncogenic high-risk HPV (most commonly types 16 and 18) and associated with smoking, immunosuppression and often multifocal disease including HPV-associated lesions in other areas of the lower female genital tract (vagina, cervix) and anal/perianal regions. HPV-independent SCC often arises in the setting of lichen sclerosus and chronic inflammation.<sup>49</sup>

The majority of HPV-associated SCC exhibit basaloid or warty morphology. HPV-independent SCC, which also includes verrucous carcinoma, tends to be keratinising; however a significant percentage of cases (15–20%) exhibit overlapping morphologic features.<sup>50,51</sup> The nature of any adjacent precursor lesion may be helpful in determining the HPV status (dVIN or classical VIN) but, owing to this morphological overlap, in practice, ancillary testing is necessary to determine the HPV status.

Most, but not all, HPV-independent vulval SCCs are associated with *TP53* mutations. A small proportion is *TP53* wild-type and there is growing evidence that these may have an intermediate prognosis between HPV-associated SCC and HPV-independent *TP53* mutated neoplasms.<sup>52</sup> It is therefore recommended these tumours should be reported as ‘HPV-independent, *TP53* mutation-type’ and ‘HPV-independent, *TP53* wild-type’.

Grading of vulval SCC is not recommended and is not included in this dataset. This is because the grade has not been shown to consistently correlate with clinical outcome.<sup>53</sup> In fact, there is a paradox in that HPV-independent SCC, which tends to be keratinising and

often well-differentiated, has a worse prognosis than HPV-associated SCC, which is typically non-keratinising, basaloid and poorly differentiated. In addition, no validated grading system exists for vulval SCC.

### **Basal cell carcinoma**

Basal cell carcinomas are histologically identical to their counterparts occurring in other cutaneous locations.

### **Adenocarcinoma**

Vulval adenocarcinomas are rare and should be diagnosed using the 2020 WHO Classification.<sup>10</sup> They may be of mammary gland type (various types as in the breast), of sweat gland origin (various types), intestinal type or arise from Paget's disease (invasive Paget's).<sup>54,55</sup> Before diagnosing primary vulval adenocarcinoma, metastasis from elsewhere should always be considered; correlation of the clinical picture (including the past history) with pathological features and immunohistochemical studies may assist.

### **Other carcinomas**

A variety of carcinomas (squamous, glandular, salivary-type and other) can arise from the Bartholin's glands.<sup>56</sup> To be considered a Bartholin's gland primary, the tumour should involve the anatomic region of the Bartholin's glands and be histologically compatible with an origin in Bartholin's glands with no alternative primary site identified elsewhere; preferably, normal Bartholin's gland tissue should be present in the vicinity of the neoplasm.

### **Neuroendocrine tumours**

Neuroendocrine neoplasia is classified according to the 2020 WHO Classification (neuroendocrine tumour, small cell neuroendocrine carcinoma, large cell neuroendocrine carcinoma, mixed neuroendocrine-non-neuroendocrine carcinoma, Merkel cell carcinoma).<sup>10</sup> Some vulval neuroendocrine carcinomas are driven by HPV-infection, while some Merkel cell carcinomas are driven by polyomavirus.<sup>57,58</sup>

*[Level of evidence C – Tumour type is an independent prognostic factor.]*

### **5.4.2 Lymphovascular space invasion**

Lymphovascular space invasion (LVSI) does not affect tumour stage; however, it is important to recognise, as there is an association with tumour spread and recurrence. Retraction artefacts should be borne in mind and only tumour emboli in endothelium-lined spaces should be regarded as positive.



While usually straightforward, the assessment of lymphovascular invasion may be difficult in a minority of cases, for which the reasons may include (but are not limited to) suboptimal fixation or cauterisation artefacts. In such cases, examination of multiple levels and/or immunostaining for endothelial or lymphatic markers (such as CD31, CD34, D2-40, ERG) may be employed to assist with the decision-making. Cases that are still equivocal after taking additional steps may be reported as indeterminate for lymphovascular invasion, but this designation should only be used sparingly and it is useful to provide the reason in a comment in the report.

*[Level of evidence D – The presence of LVSI is an independent predictor of inguinal lymph node involvement.]*

### **5.4.3 Perineural invasion**

Perineural invasion (PNI is defined as the presence of malignant cells in the layers of the nerve sheath (epineurium, perineurium and endoneurium). It was previously thought to be either a form of lymphatic invasion or spread along the path of least resistance. While PNI may be associated with other adverse features, such as deep invasion and lymphovascular invasion, there is emerging evidence that it is an independent prognostic factor, especially with regard to tumour recurrence.<sup>38,43,44</sup> Tumour cells swirling around or along a nerve but not actually invading the nerve layers may not have the same clinical significance and should not be reported as PNI.<sup>59–62</sup> The term intraneural or perineurial is more accurate but it is recognised that perineurial/intraneural and perineural have been used interchangeably in most publications. The term perineural is retained as long as it refers to invasion of the nerve.

*[Level of evidence – D.]*

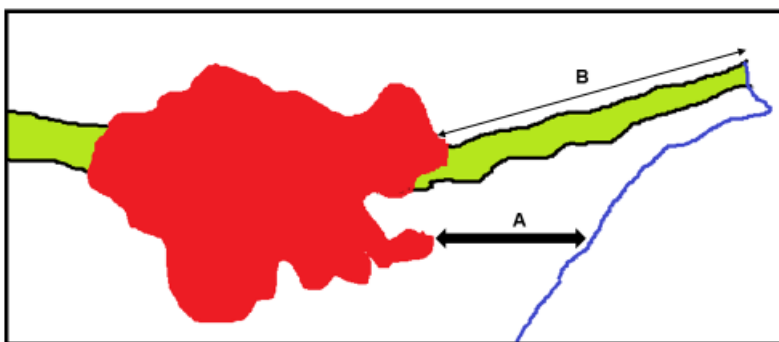
### **5.4.4 Margin status**

Recurrence rates in vulval carcinoma and cancer-related deaths have been shown to be related to pathological margin distance.<sup>63,64</sup> Owing to factors such as tissue shrinkage and epithelial changes, the microscopic distance to the margin may not be the same as that measured macroscopically.<sup>41,65–67</sup> A clearance of at least 8 mm has been suggested as the pathological margin distance required to significantly reduce the risk of local recurrence.<sup>63,68,69</sup>

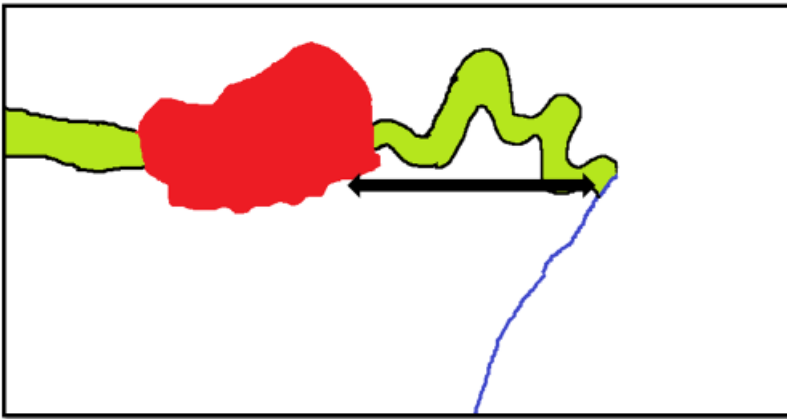
Considerable difficulty may occur in measurement of the minimal peripheral margin, especially if the tumour is exophytic and if there are folds in the skin and/or mucosa. A

survey conducted in 2018 at a BAGP meeting highlighted these difficulties and has led to the following series of recommendations.

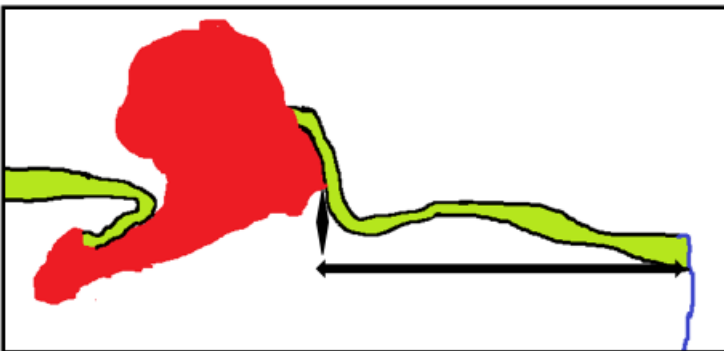
- The margin is the distance of invasive carcinoma to the epithelial–stromal junction or the peripheral stromal edge, whichever is less (Figure 3).
- The peripheral surgical margin is perpendicular to the surface and includes the skin/mucosa and the underlying soft tissue.
- Involvement of the margin should be reported.
- If uninvolved, the minimal peripheral surgical margin should be measured.
- Measurements should be in straight line whenever possible (Figure 4).
- If a collarette of tissue is present (as occurs in exophytic tumours) the measurement can include two straight lines joined at an angle (Figure 5).
- Measurement as a curved line (which is possible when assessing a digital image) is not currently recommended.
- The minimum distance to the deep margin should be recorded.<sup>70</sup>



**Figure 3: Margin measurement. A. Shortest distance to the epithelial–stromal interface OR the peripheral stromal edge, whichever is the most clinically relevant. B. This distance is what is visible at the time of surgical resection, so can be included for audit purposes.**



**Figure 4: Margin measurement should be in a straight line through the tissue, even when the surface epithelium is undulating or curved.**



**Figure 5: In exophytic tumours or if a collarette of epithelium is present, the distance to the margin can be measured as 2 straight lines at an angle.**

*[Level of evidence D – The distance of tumour from margin correlates with risk of recurrence.]*

#### **5.4.5 Precursor lesions**

The presence of HPV-associated VIN 2/3 (HSIL), HPV-independent precursors or Paget’s disease should be recorded. Involvement of a margin by a precursor lesion should be recorded. The distance of the precursor lesion to the nearest margin should be recorded.

Carcinomas associated with dVIN may be more likely to recur.<sup>71</sup>

*[Level of evidence – D.]*

#### **5.4.6 Lymph node status**

The number of involved lymph nodes, the size of the largest metastatic deposit and the presence or absence of extranodal spread should be recorded. Only inguinofemoral

(groin) nodes are regarded as regional for FIGO and TNM staging; pelvic nodes are considered to represent distant metastatic disease.

*[Level of evidence – B.]*

#### **5.4.7 Size of nodal deposits**

Nodal deposits greater than 5 mm in size have been shown to correlate with poorer survival and the tumour is upstaged in both the FIGO staging system and the TNM classification.<sup>11</sup> In the 2009 FIGO system, the stage was not clear if there were two lymph nodes with deposits measuring 5 mm and less than 5 mm, respectively. This problem is resolved in the 2021 staging system. Any number of lymph nodes with metastases equal to or less than 5 mm are included in stage IIIA and any number of lymph nodes with metastases greater than 5 mm are staged as IIIB.

In the case of SLN, it is prudent to document the size of nodal metastases even if they are less than 5 mm. This is advisable for the purposes of data collection, as there is emerging evidence that, even when the size of the deposit is less than 5 mm, non-sentinel metastases may occur in a small minority of cases.<sup>34</sup>

*[Level of evidence B – Nodal deposit size is an independent prognostic factor.]*

#### **5.4.8 Extracapsular spread**

Tumour extension outside the lymph node has been shown to be an independent predictor of poorer survival and is included in the FIGO and TNM staging systems.<sup>72,73</sup>

*[Level of evidence B – Extranodal extension is an independent prognostic factor.]*

#### **5.4.9 Non-neoplastic epithelial disease**

The presence or absence of the following non-neoplastic epithelial disease (NNED) should be recorded because there is an association with development of dVIN, invasive cancer and increased risk of recurrence.<sup>74</sup>

- Lichen sclerosus.
- Mixed lichen sclerosus and squamous hyperplasia.

*[Level of evidence D – The presence of NNED is associated with the development of cancer and increased risk of recurrence.]*

## 5.4.10 Ancillary studies

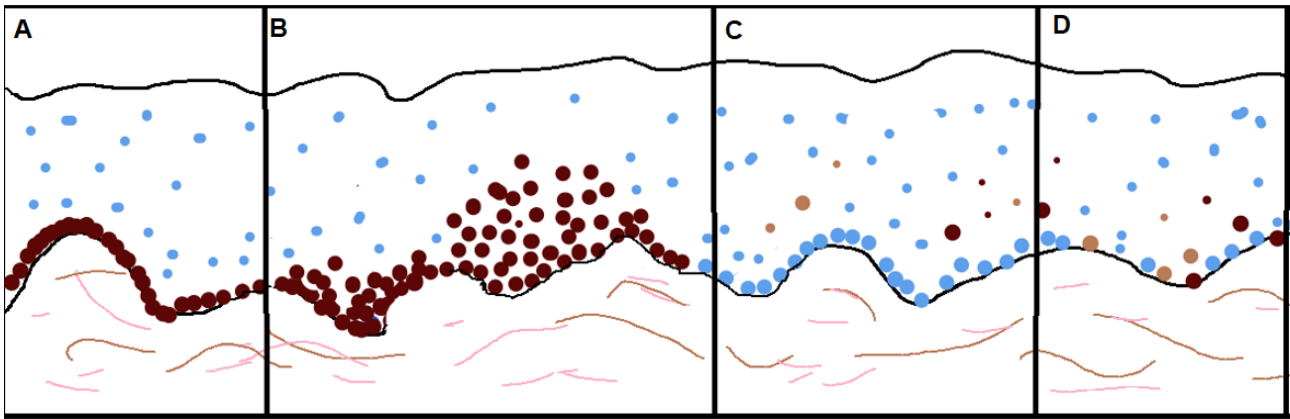
### HPV-associated tumours

The presence or absence of HPV is an important prognostic factor with regards to radiotherapy response and survival.<sup>44,46,75,76</sup> Women with HPV-dependent carcinoma have a better response to radiotherapy, fewer in-field relapses and better survival. There appears to be clear stratification into 2 groups based on HPV status, which is taken into account in the 2020 WHO tumour classification.<sup>10</sup>

Molecular methods for detecting high-risk HPV include PCR-based amplification of HPV DNA (this method can give rise to false positive results), DNA in-situ hybridisation (ISH) and RNA ISH. Not all laboratories will have access to these tests. However, immunohistochemistry for p16 is a reliable surrogate marker for high-risk HPV infection. The pattern of p16 staining is important. In precursor lesions (HSIL) p16 should only be regarded as positive if there is strong, linear, nuclear and cytoplasmic staining in the basal and suprabasal epithelium, at least 6 cells across which may fade in the upper layers ('block pattern'). It can be slightly different from that seen in cervix, in that it may not necessarily involve one-third to two-thirds of the epithelium.<sup>44,46,75</sup> When reporting p16 staining, the terms 'positive' or 'negative' are to be avoided and the terms 'block-type', 'aberrant' or 'abnormal' used instead. In the majority of cases, almost all the cells of the invasive tumour have abnormal p16 expression.

### HPV-independent tumours

Many of these tumours and their precursor lesions are associated with *TP53* mutation. Immunohistochemistry for p53 should be always employed when reporting such cases. It is acknowledged that p53 immunohistochemistry may sometimes be difficult to interpret, therefore awareness of the 3 most common mutant patterns encountered is important. These are: (1) continuous staining of the basal layers; (2) basal and parabasal/diffuse staining; (3) complete loss of staining ('null pattern'); and (4) cytoplasmic staining only. Cytoplasmic staining is rare. In *TP53* mutation-type tumours, immunohistochemistry for p53 is also useful in assessing margin status.<sup>77</sup> Not all HPV-independent carcinoma harbour *TP53* mutation and a normal p53 pattern does not exclude an HPV-I tumour. In a minority of cases, the tumour may have abnormal p16 as well as abnormal p53 staining. In such cases the p53 abnormality takes precedence and the tumour should be classified as HPV-independent, p53 mutation-type.<sup>78</sup>



**Figure 6: Patterns of p53 staining: A. Continuous basal; B. Parabasal and diffuse; C. Null; D. Wild-type. A–C are mutation-type patterns.**

It is important to bear in mind that HPV-associated carcinoma may show p53 overexpression but this has been described as a ‘mid-epithelial pattern’ that avoids the basal layer.<sup>79–81</sup>

Immunohistochemical staining for p16 and p53 is essential for all cases of VIN and invasive SCC to classify them according to HPV status and, if the p16 is normal, to further classify as *TP53* mutation-type or *TP53* wild-type. This will provide crucial information of clinical significance.

*[Level of evidence D – High-risk HPV infection in the vulva may be associated with HPV infection at other gynaecological sites.]*

#### **5.4.11 Pathologically confirmed distant metastasis**

The presence of distant metastatic disease may not always be known to the pathologist prior to the MDT meeting. If relevant specimens that indicate distant metastatic disease are received (e.g. biopsies of distant sites or pelvic lymph nodes), this should be recorded as pM1. Distant metastatic disease correlates with poorer survival.

*[Level of evidence – B.]*

## **6 Non-core data items**

These may be recorded separately and include:

- koilocytosis/LSIL as an indication of HPV infection
- fibromyxoid stromal reaction as an adverse prognostic indicator<sup>56</sup>

## 7 Small biopsies

Wide local excisions are handled in the same way as vulvectomy specimens. Ellipse and punch biopsies are handled according to size in a manner similar to skin specimens. Larger ellipse biopsies may need inking of the margins. If a lesion is identified, transverse sectioning, including the nearest resection margin, is recommended.

## 8 Diagnostic coding and staging

Primary vulval carcinomas should be subtyped according to the WHO 2020 classification and coded using SNOMED codes (Appendix B).<sup>10</sup> Tumours should be staged using the 2021 FIGO staging system with the option to include 8th edition of UICC TNM staging (Appendix A). This has been implemented in the UK since 01/01/22. Cases reported prior to this date would have been staged according to the FIGO 2009 staging system.

## 9 Criteria for audit

The following are recommended by the RCPATH as key assurance indicators (see [Key Assurance Indicators for Pathology Services](#), November 2019) and key performance indicators (see [Key Performance Indicators – Proposals for implementation](#), July 2013):

- cancer resections should be reported using a template or proforma, including items listed in the English COSD, which are, by definition, core data items in RCPATH cancer datasets. English trusts were required to implement the structured recording of core pathology data in the COSD
  - standard: 95% of reports must contain structured data
- histopathology cases must be reported, confirmed and authorised within 7 and 10 calendar days of the procedure
  - standard: 80% of cases must be reported within 7 calendar days and 90% within 10 calendar days.

This dataset can be used as a standard in audits. Examples of audits include completeness of recording of all data items in histopathology reports, audits of numbers of lymph nodes retrieved and of variation between diagnostic biopsies and final histopathology reports.

## 10 References

1. Slater D, Cook M. *Dataset for histopathological reporting of primary cutaneous malignant melanoma and regional lymph nodes*. London, UK: The Royal College of Pathologists, 2019. Accessed March 2022. Available at: <https://www.rcpath.org/uploads/assets/53688094-791e-4aaa-82cec42c3cb65e35/Dataset-for-histopathological-reporting-of-primary-cutaneous-basal-cell-carcinoma.pdf>
2. Cancer Research UK. *Vulval cancer mortality statistics*. Accessed March 2022. Available at: <https://www.cancerresearchuk.org/health-professional/cancer-statistics/statistics-by-cancer-type/vulval-cancer/mortality>
3. Lai J, Ellera R, Nordin A, Hirschowitz L, Rous B, Gildea C *et al*. Vulval cancer incidence, mortality and survival in England: age-related trends. *BJOG* 2014;121:728–739.
4. Ueda Y, Enomoto T, Kimura T, Yoshino K, Fujita M, Kimura T. Two distinct pathways to development of squamous cell carcinoma of the vulva. *J Skin Cancer* 2011;95–1250.
5. van de Nieuwenhof HP, Massuger LF, van der Avoort IA, Bekkers RL, Casparie M, Abma W *et al*. Vulvar squamous cell carcinoma development after diagnosis of VIN increases with age. *Eur J Cancer* 2009;45:851–6.
6. Scurry J. Does lichen sclerosus play a central role in the pathogenesis of human papillomavirus negative vulvar squamous cell carcinoma? The itch-scratch-lichen sclerosus hypothesis. *Int J Gynecol Cancer* 1999;9:89–97.
7. Neville G, Chapel DB, Crum CP, Song SJ, Yoon JY, Lee KR *et al*. Interobserver reproducibility of the diagnosis of differentiated exophytic vulvar intraepithelial lesion (DEVIL) and the distinction from its mimics. *Histopathology* 2021;79:957–965.
8. Roy SF, Wong J, Le Page C, Tran-Thanh D, Barkati M, Pina A *et al*. DEVIL, VAAD and vLSC constitute a spectrum of HPV-independent, p53-independent intra-epithelial neoplasia of the vulva. *Histopathology* 2021;79:975–988.
9. ICCR. *Carcinomas of the vulva*. Accessed March 2022. Available at: <http://www.iccr-cancer.org/datasets/published-datasets/female-reproductive/carcinoma-of-the-vulva>



10. World Health Organization. *WHO Classification of Tumours Volume 4, Female Genital Tumours (5th edition)*. Lyon, France: International Agency for Research on Cancer, 2020.
11. Olawaiye AB, Cotler J, Cuello MA, Bhatla N, Okamoto A, Wilailak S *et al*. FIGO staging for carcinoma of the vulva: 2021 revision. *Int J Gynaecol Obstet* 2021;155:43-47.
12. Members of Last Project Work Groups, Darragh TM, Colgan TJ, Cox JT, Heller DS, Henry MR *et al*. The Lower Anogenital Squamous Terminology Standardization Project for HPV-Associated Lesions: Background and consensus recommendations from the College of American Pathologists and the American Society for Colposcopy and Cervical Pathology. *Arch Pathol Lab Med* 2012;136:1266–1297.
13. Griesinger LM, Walline H, Wang GY, Lorenzatti Hiles G, Welch KC, Haefner HK *et al*. Expanding the morphologic, immunohistochemical, and HPV genotypic features of high-grade squamous intraepithelial lesions of the vulva with morphology mimicking differentiated vulvar intraepithelial neoplasia and/or lichen sclerosus. *Int J Gynecol Pathol* 2021;1:205–213.
14. Dabi Y, Gosset M, Bastuji-Garin S, Mitri-Frangieh R, Bendifallah S, Darai E *et al*. Associated lichen sclerosus increases the risk of lymph node metastases of vulvar cancer. *J Clin Med* 2020;17:1–250.
15. Akbari A, Pinto A, Amemiya Y, Seth A, Mirkovic J, Parra-Herran C. Differentiated exophytic vulvar intraepithelial lesion: Clinicopathologic and molecular analysis documenting its relationship with verrucous carcinoma of the vulva. *Mod Pathol* 2020;33:2011–2018.
16. Watkins JC, Howitt BE, Horowitz NS, Ritterhouse LL, Dong F, MacConaill LE *et al*. Differentiated exophytic vulvar intraepithelial lesions are genetically distinct from keratinizing squamous cell carcinomas and contain mutations in PIK3CA. *Mod Pathol* 2017;30:448–458.
17. Nooij LS, Ter Haar NT, Ruano D, Rakislova N, van Wezel T, Smit VTHBM *et al*. Genomic characterization of vulvar (pre)cancers identifies distinct molecular subtypes with prognostic significance. *Clin Cancer Res* 2017;15:23:6781–6789.
18. Parra-Herran C, Nucci MR, Singh N, Rakislova N, Howitt BE, Hoang L *et al*. HPV-independent, p53-wild-type vulvar intraepithelial neoplasia: A review of nomenclature

and the journey to characterize verruciform and acanthotic precursor lesions of the vulva. *Mod Pathol* 2022;35:10:1317–1326.

19. Heller DS, Day T, Allbritton JI, Scurry J, Radici G *et al.* Diagnostic criteria for differentiated vulvar intraepithelial neoplasia and vulvar aberrant maturation. *J Low Genit Tract Dis* 2021;25:57–70.
20. Hacker NF, Van der Velden J. Conservative management of early vulvar cancer. *Cancer* 1993;71:1673–7.
21. Slomovitz BM, Coleman RL, Oonk MH, van der Zee A, Levenback C. Update on sentinel lymph node biopsy for early-stage vulvar cancer. *Gynecol Oncol* 2015;138:472–477.
22. Levenback CF, van der Zee AG, Rob L, Plante M, Covens A, Schneider *et al.* Sentinel lymph node biopsy in patients with gynecologic cancers: Expert panel statement from the International Sentinel Node Society Meeting, February 21, 2008. *Gynecol Oncol* 2009;114:151–156.
23. Cibula D, Oonk MH, Abu-Rustum NR. Sentinel lymph node biopsy in the management of gynecologic cancer. *Curr Opin Obstet Gynecol* 2015;27:66–72.
24. Platt SL. Review of the current surgical management of vulval cancer. *World J Obstet Gynecol* 2016;5:97–101.
25. Moore RG, Granai CO, Gajewski W, Gordinier M, Steinhoff MM. Pathologic evaluation of inguinal sentinel lymph nodes in vulvar cancer patients: a comparison of immunohistochemical staining versus ultrastaging with hematoxylin and eosin staining. *Gynecol Oncol* 2003;91:378–382.
26. Hauspy J, Beiner M, Harley I, Ehrlich L, Rasty G, Covens A. Sentinel lymph node in vulvar cancer. *Cancer* 2007;1:1015–1023.
27. Devaja O, Mehra G, Coutts M, Adamson S, Montalto SA, Donaldson J *et al.* A prospective study of sentinel lymph node detection in vulval carcinoma: is it time for a change in clinical practice? *Int J Gynecol Cancer* 2011;21:559–564.
28. Vidal-Sicart S, Puig-Tintoré LM, Lejárcegui JA, Paredes P, Ortega ML, Muñoz A *et al.* Validation and application of the sentinel lymph node concept in malignant vulvar tumours. *Eur J Nucl Med Mol Imaging* 2007;34:384–391.

29. Achimas-Cadariu P, Harter P, Fisseler-Eckhoff A, Beutel B, Traut A, Du Bois A. Assessment of the sentinel lymph node in patients with invasive squamous carcinoma of the vulva. *Acta Obstet Gynecol Scand* 2009;88:1209–1214.
30. Levenback CF, Ali S, Coleman RL, Gold MA, Fowler JM, Judson PL *et al.* Lymphatic mapping and sentinel lymph node biopsy in women with squamous cell carcinoma of the vulva: a gynecologic oncology group study. *J Clin Oncol* 2012;30:3786–3791.
31. Meyer JS. Sentinel lymph node biopsy: strategies for pathologic examination of the specimen. *J Surg Oncol* 1998;69:212–218.
32. Euscher ED, Malpica A, Atkinson EN, Levenback CF, Frumovitz M, Deavers MT. Ultrastaging improves detection of metastases in sentinel lymph nodes of uterine cervix squamous cell carcinoma. *Am J Surg Pathol* 2008;32:1336–1343.
33. Morrison J, Baldwin P, Buckley L, Cogswell L, Edey K, Faruqi A *et al.* British Gynaecological Cancer Society (BGCS) vulval cancer guidelines: Recommendations for practice. *Eur J Obstet Gynecol Reprod Biol* 2020;252:502–525.
34. Oonk MH, van Hemel BM, Hollema H, de Hullu JA, Ansink AC, Vergote I *et al.* Size of sentinel-node metastasis and chances of non-sentinel-node involvement and survival in early-stage vulvar cancer: results from GROINSS-V, a multicentre observational study. *Lancet Oncol* 2010;11:646–652.
35. Robison K, Steinhoff MM, Granai CO, Brard L, Gajewski W, Moore RG. Inguinal sentinel node dissection versus standard inguinal node dissection in patients with vulvar cancer: A comparison of the size of metastasis detected in inguinal lymph nodes. *Gynecol Oncol* 2006;101:24–27.
36. Oonk MHM, Hollema H, van der Zee AGJ. Sentinel node biopsy in vulvar cancer: Implications for staging. *Best Pract Res Clin Obstet Gynaecol* 2015;29:812–821.
37. Oonk MHM, Planchamp F, Baldwin P, Mahner S, Mirza MR, Fischerova D *et al.* European Society of Gynaecological Oncology guidelines for the management of patients with vulvar cancer – Update 2023. *Int J Gynecol Cancer* 2023;3:1023–1043.
38. Hinten F, van den Einden LC, Cissen M, IntHout J, Massuger LF, de Hullu JA. Clitoral involvement of squamous cell carcinoma of the vulva: localization with the worst prognosis. *Eur J Surg Oncol* 2015;41:592–598.

39. Skala SL, Ebbott JA, Zhao L, Lieberman RW. Predictive value of an alternative strategy for measuring depth and size of stage 1 vulvar squamous cell carcinoma. *J Low Genit Tract Dis* 2020;24:265–271.
40. Van den Einden LC, Massuger LF, Jonkman JK, Bult P, de Hullu JA, Bulten J. An alternative way to measure the depth of invasion of vulvar squamous cell carcinoma in relation to prognosis. *Mod Pathol* 2015;28:295–302.
41. Rowley KC, Gallion HH, Donaldson ES, van Nagell JR, Higgins RV, Powell DE *et al.* Prognostic factors in early vulvar cancer. *Gynecol Oncol* 1988;31:43–49.
42. Magrina JF, Gonzalez-Bosquet J, Weaver AL, Gaffey TA, Leslie KO, Webb MJ *et al.* Squamous cell carcinoma of the vulva stage IA: long-term results. *Gynecol Oncol* 2000;76:24–27.
43. Pisani C, Poggiali S, De Padova L, Andreassi A, Bilenchi R. Basal cell carcinoma of the vulva. *J Eur Acad Dermatol Venereol* 2006;20:446–448.
44. McAlpine JN, Leung SCY, Cheng A, Miller D, Talhouk A, Gilks CB *et al.* Human papillomavirus (HPV)-independent vulvar squamous cell carcinoma has a worse prognosis than HPV-associated disease: a retrospective cohort study. *Histopathology* 2017;71:238–246.
45. Allo G, Yap ML, Cuartero J, Milosevic M, Ferguson S, Mackay H *et al.* HPV-independent vulvar squamous cell carcinoma is associated with significantly worse prognosis compared with HPV-associated tumors. *Int J Gynecol Pathol* 2020;39:391–399.
46. Lee LJ, Howitt B, Catalano P, Tanaka C, Murphy R, Cimbak N *et al.* Prognostic importance of human papillomavirus (HPV) and p16 positivity in squamous cell carcinoma of the vulva treated with radiotherapy. *Gynecol Oncol* 2016;142:293–298.
47. Proctor L, Hoang L, Moore J, Thompson E, Leung S, Natesan D *et al.* Association of human papilloma virus status and response to radiotherapy in vulvar squamous cell carcinoma. *Int J Gynecol Cancer* 2020;30:100–106.
48. Horne ZD, Dohopolski MJ, Pradhan D, Bhargava R, Edwards RP, Kelley JL *et al.* Human papillomavirus infection mediates response and outcome of vulvar squamous cell carcinomas treated with radiation therapy. *Gynecol Oncol* 2018;151:96–101.

49. McCluggage WG. Recent developments in vulvovaginal pathology. *Histopathology* 2009;54:156–73.
50. Rakislova N, Clavero O, Alemany L, Saco A, Quirós B, Lloveras B *et al.* Histological characteristics of HPV-associated and -independent squamous cell carcinomas of the vulva: A study of 1,594 cases. *Int J Cancer* 2017;141:2517–2527.
51. Dong F, Kojiro S, Borger DR, Growdon WB, Oliva E. Squamous cell carcinoma of the vulva: A subclassification of 97 cases by clinicopathologic, immunohistochemical, and molecular features (p16, p53, and EGFR). *Am J Surg Pathol* 2015;39:1045–1053.
52. Kortekaas KE, Bastiaannet E, van Doorn HC, de Vos van Steenwijk PJ, Ewing-Graham PC, Creutzberg CL *et al.* Vulvar cancer subclassification by HPV and p53 status results in three clinically distinct subtypes. *Gynecol Oncol* 2020;159:649–656.
53. Chen J, Ln H. A review of prognostic factors in squamous cell carcinoma of the vulva: Evidence from the last decade. *Semin Diagn Pathol* 2020;22:2570–30088-5.
54. Tessier-Cloutier B, Asleh-Aburaya K, Shah V, McCluggage WG, Tinker A, Gilks CB. Molecular subtyping of mammary-like adenocarcinoma of the vulva shows molecular similarity to breast carcinomas. *Histopathology* 2017;71:446–452.
55. He SR, Deng WH, Yang L, Yang K, Cui D, Liu DG. Cloacogenic adenocarcinoma of the vulva: one new case and literature review. *Eur J Gynaecol Oncol* 2017;38:296–302.
56. Nazeran T, Cheng AS, Karnezis AN, Tinker AV, Gilks CB. Bartholin gland carcinoma: Clinicopathologic features, including p16 expression and clinical outcome. *Int J Gynecol Pathol* 2019;38:189–195.
57. Chen PP, Ramalingam P, Alvarado-Cabrero I, Euscher ED, Nagarajan P, Lawson BC *et al.* High-grade neuroendocrine carcinomas of the vulva: A clinicopathologic study of 16 cases. *Am J Surg Pathol* 2021;45:304–316.
58. Coggshall K, Tello TL, North JP, Yu SS. Merkel cell carcinoma: An update and review: Pathogenesis, diagnosis, and staging. *J Am Acad Dermatol* 2018;78:433–442.

59. Gadducci A, Pistolesi S, Cosio S, Naccarato AG. Is perineural invasion a novel prognostic factor useful to tailor adjuvant treatment in patients treated with primary surgery for cervical and vulvar carcinoma?. *Anticancer Res* 2020;40:3031–3037.
60. Ferrari F, Forte S, Ardighieri L, Bonetti E, Fernando B, Sartori E *et al.* Multivariate analysis of prognostic factors in primary squamous cell vulvar cancer: The role of perineural invasion in recurrence and survival. *Eur J Surg Oncol* 2019;45:2115–2119.
61. Pergialiotis V, Ferousis L, Rouvali A, Liatsou E, Haidopoulos D, Rodolakis A *et al.* Perineural invasion as a predictive biomarker of groin metastases and survival outcomes in vulvar cancer: A meta-analysis. *Cancer Invest* 2022;40:733–741.
62. Micheletti L, Borella F, Preti M, Frau V, Cosma S, Privitera S *et al.* Perineural invasion in vulvar squamous-cell carcinoma is an independent risk factor for cancer-specific survival, but not for locoregional recurrence: Results from a single tertiary referral center. *Cancers (Basel)* 2021;14:124.
63. Chan JK, Sugiyama V, Pham H, Gu M, Rutgers J, Osann K *et al.* Margin distance and other clinico-pathologic prognostic factors in vulvar carcinoma: a multivariate analysis. *Gynecol Oncol* 2007;104:636–641.
64. Rouzier R, Haddad B, Plantier F, Dubois P, Pelisse M, Paniel BJ. Local relapse in patients treated for squamous cell vulvar carcinoma: incidence and prognostic value. *Obstet Gynecol* 2002;100:1159–1167.
65. Balega J, Butler J, Jeyarajah A, Oram D, Shepherd J, Faruqi A *et al.* Vulval cancer: what is an adequate surgical margin? *Eur J Gynaecol Oncol* 2008;29:455–458.
66. Tran T, Sundaram CP, Bahler CD, Eble JN, Grignon DJ, Monn MF *et al.* Correcting the shrinkage effects of formalin fixation and tissue processing for renal tumors: toward standardization of pathological reporting of tumor size. *J Cancer* 2015;2:759–66.
67. Schned AR, Wheeler KJ, Hodorowski CA, Heaney JA, Ernstoff MS, Amdur RJ. Tissue-shrinkage correction factor in the calculation of prostate cancer volume. *Am J Surg Pathol* 1996;20:1501–1506.
68. Baiocchi G, Mantoan H, de Brot L, Badiglian-Filho L, Kumagai LY, Faloppa CC *et al.* How important is the pathological margin distance in vulvar cancer? *Eur J Surg Oncol* 2015;41:1653–1658.

69. Nooij LS, van der Slot MA, Dekkers OM, Stijnen T, Bosse T, Smit VTHMB *et al.* Tumour-free margins in vulvar squamous cell carcinoma: Does distance really matter? *Eur J Cancer* 1990;65:139–149.
70. Kortekaas KE, Van de Vijver KK, van Poelgeest MIE, Gilks CB, Smit VTHBM, Arif S *et al.* Practical guidance for measuring and reporting surgical margins in vulvar cancer. *Int J Gynecol Pathol* 2020;39:420–427.
71. Eva LJ, Ganesan R, Chan KK, Honest H, Malik S, Luesley DM. Vulval squamous cell carcinoma occurring on a background of differentiated vulval intraepithelial neoplasia is more likely to recur: a review of 154 cases. *J Reprod Med* 2008;53:397–401.
72. van der Velden J, van Lindert AC, Lammes FB, ten Kate FJ, Sie-Go DM, Oosting H *et al.* Extracapsular growth of lymph node metastases in squamous cell carcinoma of the vulva. The impact on recurrence and survival. *Cancer* 1995;75:2885–2890.
73. Raspagliesi F, Hanozet F, Ditto A, Solima E, Zanaboni F, Vecchione F *et al.* Clinical and pathological prognostic factors in squamous cell carcinoma of the vulva. *Gynecol Oncol* 2006;102:333–337.
74. Yap JK, Fox R, Leonard S, Ganesan R, Kehoe ST, Dawson CW *et al.* Adjacent lichen sclerosis predicts local recurrence and second field tumour in women with vulvar squamous cell carcinoma. *Gynecol Oncol* 2016;142:420–426.
75. Wakeham K, Kavanagh K, Cuschieri K, Millan D, Pollock KG, Bell S *et al.* HPV status and favourable outcome in vulvar squamous cancer. *Int J Cancer* 2017;140:1134–1146.
76. Hay CM, Lachance JA, Lucas FL, Smith KA, Jones MA. Biomarkers p16, human papillomavirus and p53 predict recurrence and survival in early-stage squamous cell carcinoma of the vulva. *J Low Genit Tract Dis* 2016;20:252–256.
77. Singh N, Gilks CB. Vulval squamous cell carcinoma and its precursors. *Histopathology* 2020;76:128–138.
78. Hang Y, Almadani N, Thompson EF, Tessier-Cloutier B, Chen J, Ho J *et al.* Classification of vulvar squamous cell carcinoma and precursor lesions by p16 and p53 immunohistochemistry: Considerations, caveats, and an algorithmic approach. *Mo Pathol* 2023;36:100145.

79. Kortekaas KE, Solleveld-Westerink N, Tessier-Cloutier B, Rutten TA, Poelgeest MIE, Gilks CB *et al.* Performance of the pattern-based interpretation of p53 immunohistochemistry as a surrogate for TP53 mutations in vulvar squamous cell carcinoma. *Histopathology* 2020;77:92–99.
80. Tessier-Cloutier B, Kortekaas KE, Thompson E, Pors J, Chen J, Ho J *et al.* Major p53 immunohistochemical patterns in in situ and invasive squamous cell carcinomas of the vulva and correlation with TP53 mutation status. *Mod Pathol* 2020;3:1595–1605.
81. Singh N, Gilks CB, Wong RWC, McCluggage WG, Simon C. *Interpretation of p16 Immunohistochemistry In Lower Anogenital Tract Neoplasia*. Derby, UK: The British Association of Gynaecological Pathologists, 2018. Available at:  
<https://www.bgcs.org.uk/wp-content/uploads/2019/05/BAGP-UKNEQAS-clQC-project-p16-interpretation-guide-2018.pdf>



## Appendix A FIGO and TNM staging of vulval carcinoma

### FIGO staging of vulval carcinoma

	FIGO 2021 (from 01/01/2022)	FIGO 2009 (prior to 01/01/2022)	Comment
I	Tumour confined to the vulva	Tumour confined to the vulva	No change
IA	Tumour size $\leq 2$ cm and stromal invasion $\leq 1$ mm <sup>a</sup>	Lesions $\leq 2$ cm in size, confined to the vulva or perineum and with stromal invasion $\leq 1.0$ mm, no nodal metastasis	Change in method used by pathologists to measure depth of stromal invasion. Likely to result in fewer tumours having depth $>1$ mm.
IB	Tumour size $>2$ cm or stromal invasion $>1$ mm <sup>a</sup>	Lesions $>2$ cm in size or with stromal invasion $>1.0$ mm <sup>a</sup> , confined to the vulva or perineum, with negative nodes	
II	Tumour of any size with extension to lower one-third of the urethra, lower one-third of the vagina, lower one-third of the anus with negative nodes	Tumour of any size with extension to adjacent perineal structures (1/3 lower urethra, 1/3 lower vagina, anus) with negative nodes	No change
III	Tumour of any size with extension to upper part of adjacent perineal structures, or with any number of nonfixed, nonulcerated lymph node	Tumour of any size with or without extension to adjacent perineal structures (1/3 lower urethra, 1/3 lower vagina, anus) with positive inguino-femoral lymph nodes	See below
IIIA	Tumour of any size with disease extension to upper two-thirds of the urethra, upper two-thirds of the vagina, bladder mucosa, rectal mucosa, or regional lymph node metastases $\leq 5$ mm	(i) With 1 lymph node metastasis ( $\geq 5$ mm), or (ii) 1–2 lymph node metastasis(es) ( $< 5$ mm)	Now includes: - upper 2/3 urethra or upper 2/3 vagina, bladder mucosa or rectal mucosa (previously all stage IVA). metastasis $>5$ mm. - any number of lymph nodes as long as $\leq 5$ mm No longer includes:

			- lymph node metastasis in a single node >5mm (now stage IIIB)
IIIB	Regional <sup>b</sup> lymph node metastases >5mm	(i) With 2 or more lymph node metastases (≥5 mm), or (ii) 3 or more lymph node metastases (<5 mm)	Now includes: - any number of lymph nodes if size of metastasis >5mm Now excludes: - 3 or more lymph nodes if size is ≤5mm (now stage IIIA)
IIIC	Regional <sup>b</sup> lymph node metastases with extracapsular spread	With positive nodes with extracapsular spread	No change
IV	Tumour of any size fixed to bone, or fixed, ulcerated lymph node metastases, or distant metastases	Tumour invades other regional (2/3 upper urethra, 2/3 upper vagina), or distant structures	See below
IVA	Disease fixed to pelvic bone, or fixed or ulcerated regional <sup>b</sup> lymph node metastases	Tumour invades any of the following: (i) upper urethral and/or vaginal mucosa, bladder mucosa, rectal mucosa, or fixed to pelvic bone, or (ii) fixed or ulcerated inguinofemoral lymph nodes	Now excludes: - upper 2/3 urethra or upper 2/3 vagina, bladder mucosa or rectal mucosa (now stage IIIA).
IVB	Distant metastases	Any distant metastasis including pelvic lymph nodes	No change
			Change in method of measurement of depth of invasion. No change in regional nodes.

<sup>a</sup>Depth of invasion is measured from the basement membrane of the deepest, adjacent, dysplastic, tumour-free rete ridge (or nearest dysplastic rete peg) to the deepest point of invasion. <sup>b</sup>Regional refers to inguinal and femoral lymph nodes.

## **UICC TNM Classification (8th edition)**

### **T – Primary tumour**

TX Primary tumour cannot be assessed

T0 No evidence of primary tumour

Tis Carcinoma in situ (pre-invasive carcinoma)

T1 Tumour confined to vulva

T1a Tumour 2 cm or less in greatest dimension and with stromal invasion no greater than 1.0 mm

T1b Tumour greater than 2 cm and/or stromal invasion greater than 1.0 mm

T2 Tumour invades any of the following structures: lower third of urethra, lower third of vagina, anus

T3 Tumour includes any of the following perineal structures: upper two-thirds of urethra, upper two-thirds of vagina, bladder mucosa, rectal mucosa; or fixed to pelvic bone

### **N – Regional lymph nodes**

NX Regional lymph nodes cannot be assessed

N0 No regional lymph nodes metastasis

N1 Regional lymph node metastasis with the following features:

N1a One or two lymph node metastases each less than 5 mm

N1b One lymph node metastasis 5 mm or greater

N2 Regional lymph node metastasis with the following features

N2a Three or more lymph nodes metastases each less than 5 mm

N2b Two or more lymph node metastases 5 mm or greater

N2c Lymph node metastasis with extracapsular spread

N3 Fixed or ulcerated regional lymph node metastasis

### **M – Distant metastasis**

M0 No distant metastasis

M1 Distant metastasis (including pelvic lymph nodes)

## Appendix B WHO classification and SNOMED codes

Tumour site	ICD-10	SNOMED 2/3 Code	SNOMED-CT terminology	SNOMED-CT code
Vulva	C51	T-80000/T-81000	Entire vulva (body structure)	265796001

The morphology codes are from the International Classification of Diseases for Oncology (ICD-O).

Morphological codes	SNOMED 2/3 /ICD-O code	SNOMED-CT terminology	SNOMED-CT code
<b>Intraepithelial tumours</b>			
HSIL (VIN 2/3)	M-80772	Squamous intraepithelial neoplasia, grade III (morphologic abnormality)	20365006
dVIN	M-80712	Differentiated intraepithelial neoplasia (morphologic abnormality)	816198009
Paget's disease	M-85423	Paget's disease, extramammary (except Paget's disease of bone) (morphologic abnormality)	71447003
<b>Squamous cell carcinoma</b>			
Keratinising or non-keratinising	M-80703	Squamous cell carcinoma, no ICD-O subtype (morphologic abnormality)	28899001
Squamous cell carcinoma HPV-associated	M-80853	Human papillomavirus positive squamous cell carcinoma (morphologic abnormality)	783212001
Squamous cell carcinoma HPV-independent	M-80863	Human papillomavirus negative squamous cell carcinoma (morphologic abnormality)	783213006
Verrucous	M-80513	Verrucous carcinoma (morphologic abnormality)	89906000
<b>Basal cell carcinoma</b>			
Basal cell carcinoma	M-80903	Basal cell carcinoma (morphologic abnormality)	1338007
<b>Glandular tumours</b>			
Adenocarcinoma of anogenital mammary-like glands	M-85003	Infiltrating duct carcinoma (morphologic abnormality)	82711006

Phyllodes tumour, malignant	M-90203	Phyllodes tumour, malignant (morphologic abnormality)	87913009
Adenocarcinoma, sweat gland type	M-84003	Sweat gland adenocarcinoma (morphologic abnormality)	32272007
Adenocarcinoma, intestinal type	M-81443	Adenocarcinoma, intestinal type (morphologic abnormality)	25190001
<b>Bartholin's gland tumours</b>			
Adenocarcinoma, NOS	M-81403	Adenocarcinoma, no subtype (morphologic abnormality)	35917007
Squamous cell carcinoma, NOS	M-80703	Squamous cell carcinoma, no ICD-O subtype (morphologic abnormality)	28899001
Adenosquamous carcinoma	M-85603	Adenosquamous carcinoma (morphologic abnormality)	59367005
Adenoid cystic carcinoma	M-82003	Adenoid cystic carcinoma (morphologic abnormality)	11671000
Myoepithelial carcinoma	M-89823	Malignant myoepithelioma (morphologic abnormality)	128884000
Epithelial-myoepithelial carcinoma	M-85623	Epithelial-myoepithelial carcinoma (morphologic abnormality)	9618003
Squamous cell carcinoma, HPV-associated	M-80853	Human papillomavirus positive squamous cell carcinoma (morphologic abnormality)	783212001
<b>Neuroendocrine tumours</b>			
Neuroendocrine tumour, grade 1	M-82403	Neuroendocrine tumour grade 1 (morphologic abnormality)	127572005
Neuroendocrine tumour, grade 2	M-82493	Neuroendocrine tumour grade 2 (morphologic abnormality)	127573000
Small cell neuroendocrine carcinoma	M-80413	Small cell carcinoma (morphologic abnormality)	74364000
Large cell neuroendocrine carcinoma	M-80133	Large cell neuroendocrine carcinoma (morphologic abnormality)	128628002

Combined small cell neuroendocrine carcinoma	M-80453	Combined small cell carcinoma (morphologic abnormality)	21326004
Combined large cell neuroendocrine tumour	M-80313	Large cell neuroendocrine carcinoma (morphologic abnormality)	128628002
<b>Germ cell tumours</b>			
Germ cell tumour, NOS	M-90643	Germinoma (morphologic abnormality)	28307001
Yolk sac tumour	M-90713	Endodermal sinus tumour (morphologic abnormality)	74409009

### Procedure codes (P)

These are used in SNOMED 2 and SNOMED 3 to distinguish biopsies, partial resections and radical resections to indicate the nature of the procedure.

Local P codes should be recorded. At present, P codes vary according to the SNOMED system in use in different institutions.

## Appendix C Reporting proforma for vulval cancer resection specimens in list format

Element name	Values	Implementation comments
Clinical information, History of previous cancer, specify	Free text	
Clinical information, Prior neoadjuvant therapy, specify	Free text	
Clinical information, Other, specified	Free text	
Clinical information, information not provided	Single selection value list: <ul style="list-style-type: none"> <li>• Information provided</li> <li>• Information not provided</li> </ul>	Information provided selected if any of above values have non-null values
Operative procedure	Multiple selection value list: <ul style="list-style-type: none"> <li>• Not specified</li> <li>• Wide local excision</li> <li>• Partial radical vulvectomy, left</li> <li>• Total radical vulvectomy</li> <li>• Lymph nodes</li> <li>• Other</li> </ul>	
Operative procedure, Lymph nodes, specify site	Free text	Only applicable if Operative procedure, Lymph nodes selected
Operative procedure, Other specify	Free text	Only applicable if Operative procedure, Other selected
Specimen dimensions, 1	Size in mm	
Specimen dimensions, 2	Size in mm	
Specimen dimensions, 3	Size in mm	
Specimen dimensions, cannot be assessed, specify	Free text	
Tumour site	Multiple selection value list: <ul style="list-style-type: none"> <li>• Left vulva, not specified</li> <li>• Left vulva, Labium majus</li> <li>• Left vulva, Labium minus</li> <li>• Left vulva, Bartholin glands</li> </ul>	

	<ul style="list-style-type: none"> <li>• Right vulva, not specified</li> <li>• Right vulva, Labium majus</li> <li>• Right vulva, Labium minus</li> <li>• Right vulva, Bartholin glands</li> <li>• Midline/Central/Clitoral</li> <li>• Vulva, site not known</li> <li>• Extension to adjacent structures, vagina</li> <li>• Extension to adjacent structures, urethra</li> <li>• Extension to adjacent structures, anal/perianal</li> <li>• Extension to adjacent structures, other</li> <li>• Other</li> </ul>	
Tumour site, extension to adjacent structures, other specify	Free text	
Tumour site, other	Free text	
Tumour dimensions, Maximum horizontal tumour dimension	Size in mm	
Tumour dimensions, Depth of invasion	Size in mm	
Tumour dimensions, cannot be assessed, specify	Free text	
Histological type	<p>Single selection value list:</p> <ul style="list-style-type: none"> <li>• Squamous cell carcinoma, HPV-associated</li> <li>• Squamous cell carcinoma, HPV -independent</li> <li>• Squamous cell carcinoma, NOS</li> <li>• Basal cell carcinoma</li> <li>• Bartholin gland carcinoma</li> <li>• Adenocarcinoma</li> <li>• Neuroendocrine carcinoma</li> <li>• Other</li> </ul>	
Histological type, Bartholin gland carcinoma	Free text	Only applicable if 'Histological type, Bartholin gland carcinoma' is selected.



Histological type, Adenocarcinoma	Free text	Only applicable if 'Histological type, Adenocarcinoma' is selected.
Histological type, Neuroendocrine carcinoma	Free text	Only applicable if 'Histological type, Neuroendocrine carcinoma' is selected.
Histological type, other	Free text	Only applicable if 'Histological type, Other' is selected.
Lymphovascular invasion	Single selection value list: <ul style="list-style-type: none"> <li>• Present</li> <li>• Not identified</li> <li>• Indeterminate</li> </ul>	
PNI (perineural/perineurial invasion)	Single selection value list: <ul style="list-style-type: none"> <li>• Present</li> <li>• Not identified</li> </ul>	
Margin status, invasive tumour	Single selection value list: <ul style="list-style-type: none"> <li>• Cannot be assessed</li> <li>• Not involved</li> <li>• Involved</li> </ul>	
Margin status, invasive tumour, not involved, distance	Distance in mm	Only applicable if Margin status, invasive tumour 'Not involved' selected
Margin status, invasive tumour, not involved, specify closest margin	Free text	Only applicable if Margin status, invasive tumour 'Not involved' selected
Margin status, invasive tumour, involved, specify margin	Free text	Only applicable if Margin status, invasive tumour 'Involved' selected
Margin status, precursor lesions, not involved, distance	Distance in mm	Only applicable if Margin status, precursor lesions 'Not involved' selected
Margin status, precursor lesions, not involved, specify closest margin	Free text	Only applicable if Margin status, precursor lesions 'Not involved' selected
Margin status, precursor lesions, involved, specify margin	Free text	Only applicable if Margin status, precursor lesions 'Involved' selected
Lymph node status, sentinel lymph nodes	Single selection value list: <ul style="list-style-type: none"> <li>• Cannot be assessed</li> </ul>	

	<ul style="list-style-type: none"> <li>No nodes submitted or found</li> <li>Nodes identified</li> </ul>	
Lymph node status, sentinel lymph nodes, Site 1, description	Free text	
Lymph node status, sentinel lymph nodes, Site 1, number of nodes examined	Integer	
Lymph node status, sentinel lymph nodes, Site 1, number of nodes positive	Integer	
Lymph node status, sentinel lymph nodes, Site 1, Size of maximum tumour deposit	Size in mm	
Lymph node status, sentinel lymph nodes, Site 1, extracapsular spread	Single selection value list: <ul style="list-style-type: none"> <li>Not identified</li> <li>Present</li> </ul>	
Lymph node status, sentinel lymph nodes, Site 2, description	Free text	
Lymph node status, sentinel lymph nodes, Site 2, number of nodes examined	Integer	
Lymph node status, sentinel lymph nodes, Site 2, number of nodes positive	Integer	
Lymph node status, sentinel lymph nodes, Site 2, Size of maximum tumour deposit	Size in mm	
Lymph node status, sentinel lymph nodes, Site 2, extracapsular spread	Single selection value list: <ul style="list-style-type: none"> <li>Not identified</li> <li>Present</li> </ul>	
Lymph node status, sentinel lymph nodes, Classification of nodal metastasis	Single selection value list: <ul style="list-style-type: none"> <li>Isolated tumour cells (&lt;0.2 mm)</li> <li>Micrometastasis (0.2–2 mm)</li> <li>Macrometastasis (&gt;2 mm)</li> </ul>	
Lymph node status, sentinel lymph nodes, if positive	Single selection value list: <ul style="list-style-type: none"> <li>Identified with ultrastaging including immunohistochemistry</li> </ul>	

	<ul style="list-style-type: none"> <li>Identified with ultrastaging without immunohistochemistry</li> <li>Identified without ultrastaging</li> </ul>	
Lymph node status, regional non-sentinel lymph nodes	<p>Single selection value list:</p> <ul style="list-style-type: none"> <li>Cannot be assessed</li> <li>No nodes submitted or found</li> <li>Nodes identified</li> </ul>	
Lymph node status, regional non-sentinel lymph nodes, Site 1, description	Free text	
Lymph node status, regional non-sentinel lymph nodes, Site 1, number of nodes examined	Integer	
Lymph node status, regional non-sentinel lymph nodes, Site 1, number of nodes positive	Integer	
Lymph node status, regional non-sentinel lymph nodes, Site 1, Size of maximum tumour deposit	Size in mm	
Lymph node status, regional non-sentinel lymph nodes, Site 1, extracapsular spread	<p>Single selection value list:</p> <ul style="list-style-type: none"> <li>Not identified</li> <li>Present</li> </ul>	
Lymph node status, regional non-sentinel lymph nodes, Site 2, description	Free text	
Lymph node status, regional non-sentinel lymph nodes, Site 2, number of nodes examined	Integer	
Lymph node status, regional non-sentinel lymph nodes, Site 2, number of nodes positive	Integer	
Lymph node status, regional non-sentinel lymph nodes, Site 2, Size of maximum tumour deposit	Size in mm	

Lymph node status, regional non-sentinel lymph nodes, Site 2, extracapsular spread	Single selection value list: <ul style="list-style-type: none"> <li>• Not identified</li> <li>• Present</li> </ul>	
Lymph node status, regional non-sentinel lymph nodes, Classification of nodal metastasis	Single selection value list: <ul style="list-style-type: none"> <li>• Isolated tumour cells (&lt;0.2 mm)</li> <li>• Micrometastasis (0.2–2 mm)</li> <li>• Macrometastasis (&gt;2 mm)</li> </ul>	
Lymph node status, regional non-sentinel lymph nodes, Clinically fixed or ulcerated lymph nodes	Single selection value list: <ul style="list-style-type: none"> <li>• Not known</li> <li>• Present</li> </ul>	
Lymph node status, non-regional lymph nodes	Single selection value list: <ul style="list-style-type: none"> <li>• Cannot be assessed</li> <li>• No nodes submitted or found</li> <li>• Nodes identified</li> </ul>	
Lymph node status, non-regional lymph nodes, Site 1, description	Free text	
Lymph node status, non-regional lymph nodes, Site 1, number of nodes examined	Integer	
Lymph node status, non-regional lymph nodes, Site 1, number of nodes positive	Integer	
Lymph node status, non-regional lymph nodes, Site 1, Size of maximum tumour deposit	Size in mm	
Lymph node status, non-regional lymph nodes, Site 1, extracapsular spread	Single selection value list: <ul style="list-style-type: none"> <li>• Not identified</li> <li>• Present</li> </ul>	
Lymph node status, non-regional lymph nodes, Site 2, description	Free text	
Lymph node status, non-regional lymph nodes, Site 2, number of nodes examined	Integer	

Lymph node status, non-regional lymph nodes, Site 2, number of nodes positive	Integer	
Lymph node status, non-regional lymph nodes, Site 2, Size of maximum tumour deposit	Size in mm	
Lymph node status, non-regional lymph nodes, Site 2, extracapsular spread	Single selection value list: <ul style="list-style-type: none"> <li>• Not identified</li> <li>• Present</li> </ul>	
Lymph node status, non-regional lymph nodes, Classification of nodal metastasis	Single selection value list: <ul style="list-style-type: none"> <li>• Isolated tumour cells (&lt;0.2 mm)</li> <li>• Micrometastasis (0.2–2 mm)</li> <li>• Macrometastasis (&gt;2 mm)</li> </ul>	
Co-existent pathology/precursor lesions	Single selection value list: <ul style="list-style-type: none"> <li>• None identified</li> <li>• Present</li> </ul>	
Co-existent pathology/precursor lesions, present	Multiple selection value list: <ul style="list-style-type: none"> <li>• Low grade squamous intraepithelial lesion (LSIL), HPV-associated</li> <li>• High grade squamous intraepithelial lesion (HSIL), HPV-associated</li> <li>• Vulval intraepithelial neoplasia (VIN), HPV-independent</li> <li>• Lichen sclerosus</li> <li>• Other</li> </ul>	Only applicable if Co-existent pathology/precursor lesions, present selected
Co-existent pathology/precursor lesions, present, other specify	Free text	Only applicable if Co-existent pathology/precursor lesions, present, Other selected
Ancillary studies	Single selection value list: <ul style="list-style-type: none"> <li>• Not performed</li> <li>• Performed</li> </ul>	
Ancillary studies, performed	Multiple selection value list: <ul style="list-style-type: none"> <li>• p16 immunohistochemistry</li> <li>• HPV testing</li> </ul>	Only applicable of Ancillary studies, Performed selected

Pathologically confirmed distant metastasis	Single selection value list: <ul style="list-style-type: none"> <li>• Not identified</li> <li>• Present</li> </ul>	
Pathologically confirmed distant metastasis, present, specify	Free text	Only applicable if pathologically confirmed distant metastasis, Present selected
UICC TNM version	Single selection value list: <ul style="list-style-type: none"> <li>• 8</li> </ul>	Value must be 8
TNM descriptors	Multiple selection value list: <ul style="list-style-type: none"> <li>• m (multiple primary tumours)</li> <li>• r (recurrent)</li> <li>• y (post-therapy)</li> </ul>	
pT category	Single selection value list: <ul style="list-style-type: none"> <li>• TX</li> <li>• T0</li> <li>• Tis</li> <li>• T1a</li> <li>• T1b</li> <li>• T2</li> <li>• T3</li> </ul>	
pN category	Single selection value list: <ul style="list-style-type: none"> <li>• NX</li> <li>• N0</li> <li>• N1a</li> <li>• N1b</li> <li>• N2a</li> <li>• N2b</li> <li>• N2c</li> <li>• N3</li> </ul>	
FIGO version	Single selection value list: <ul style="list-style-type: none"> <li>• 2021</li> </ul>	
Provisional FIGO stage	Single selection value list: <ul style="list-style-type: none"> <li>• IA</li> <li>• IB</li> <li>• II</li> <li>• IIIA(i)</li> <li>• IIIA(ii)</li> <li>• IIIB(i)</li> </ul>	

	<ul style="list-style-type: none"> <li>• IIIB(ii)</li> <li>• IIIC</li> <li>• IVA(i)</li> <li>• IVA(ii)</li> <li>• IVB</li> </ul>	
SNOMED Topography code	May have multiple codes. Look up from SNOMED tables.	
SNOMED Morphology code	May have multiple codes. Look up from SNOMED tables.	

## Appendix D Reporting proforma for vulval cancer biopsy specimens in list format

Element name	Values	Implementation comments
Clinical information, History of previous cancer, specify	Free text	
Clinical information, Prior neoadjuvant therapy, specify	Free text	
Clinical information, Other, specified	Free text	
Clinical information, information not provided	Single selection value list: <ul style="list-style-type: none"> <li>• Information provided</li> <li>• Information not provided</li> </ul>	Information provided selected if any of above values have non-null values
Procedure	Single selection value list: <ul style="list-style-type: none"> <li>• Punch biopsy</li> <li>• Wedge biopsy</li> </ul>	
Laterality	Single selection value list: <ul style="list-style-type: none"> <li>• Left</li> <li>• Right</li> <li>• Midline</li> <li>• Not known</li> </ul>	
Operative procedure, Other specify	Free text	Only applicable if Operative procedure, Other selected
Histological type	Single selection value list: <ul style="list-style-type: none"> <li>• Squamous cell carcinoma, HPV-associated</li> <li>• Squamous cell carcinoma, HPV -independent</li> <li>• Squamous cell carcinoma, NOS</li> <li>• Basal cell carcinoma</li> <li>• Bartholin gland carcinoma</li> <li>• Adenocarcinoma</li> <li>• Neuroendocrine carcinoma</li> <li>• Other</li> </ul>	
Histological type, Bartholin gland carcinoma	Free text	Only applicable if 'Histological type, Bartholin gland



		carcinoma' is selected.
Histological type, Adenocarcinoma	Free text	Only applicable if 'Histological type, Adenocarcinoma' is selected.
Histological type, Neuroendocrine carcinoma	Free text	Only applicable if 'Histological type, Neuroendocrine carcinoma' is selected.
Histological type, other	Free text	Only applicable if 'Histological type, Other' is selected.
Lymphovascular invasion	Single selection value list: <ul style="list-style-type: none"> <li>• Present</li> <li>• Not identified</li> <li>• Indeterminate</li> </ul>	
Perineural invasion	Single selection value list: <ul style="list-style-type: none"> <li>• Present</li> <li>• Not identified</li> </ul>	
Margin status, invasive tumour	Single selection value list: <ul style="list-style-type: none"> <li>• Cannot be assessed</li> <li>• Not involved</li> <li>• Involved</li> </ul>	
Co-existent pathology/precursor lesions	Single selection value list: <ul style="list-style-type: none"> <li>• None identified</li> <li>• Present</li> </ul>	
Co-existent pathology/precursor lesions, present	Multiple selection value list: <ul style="list-style-type: none"> <li>• Low grade squamous intraepithelial lesion (LSIL), HPV-associated</li> <li>• High grade squamous intraepithelial lesion (HSIL), HPV-associated</li> <li>• Vulval intraepithelial neoplasia (VIN), HPV-independent</li> <li>• Lichen sclerosis</li> <li>• Other</li> </ul>	Only applicable if Co-existent pathology/precursor lesions, present selected
Co-existent pathology/precursor lesions, present, other specify	Free text	Only applicable if Co-existent pathology/precursor

		lesions, present, Other selected
Ancillary studies	Single selection value list: <ul style="list-style-type: none"> <li>• Not performed</li> <li>• Performed</li> </ul>	
Ancillary studies, performed	Multiple selection value list: <ul style="list-style-type: none"> <li>• p16 immunohistochemistry</li> <li>• HPV testing</li> </ul>	Only applicable of Ancillary studies, Performed selected
SNOMED Topography code	May have multiple codes. Look up from SNOMED tables.	
SNOMED Morphology code	May have multiple codes. Look up from SNOMED tables.	

## Appendix E Summary table – Explanation of grades of evidence

(modified from Palmer K *et al. BMJ* 2008; 337:1832)

Grade (level) of evidence	Nature of evidence
Grade A	<p>At least one high-quality meta-analysis, systematic review of randomised controlled trials or a randomised controlled trial with a very low risk of bias and directly attributable to the target population</p> <p>or</p> <p>A body of evidence demonstrating consistency of results and comprising mainly well-conducted meta-analyses, systematic reviews of randomised controlled trials or randomised controlled trials with a low risk of bias, directly applicable to the target cancer type.</p>
Grade B	<p>A body of evidence demonstrating consistency of results and comprising mainly high-quality systematic reviews of case-control or cohort studies and high-quality case-control or cohort studies with a very low risk of confounding or bias and a high probability that the relation is causal and which are directly applicable to the target population</p> <p>or</p> <p>Extrapolation evidence from studies described in A.</p>
Grade C	<p>A body of evidence demonstrating consistency of results and including well-conducted case-control or cohort studies and high-quality case-control or cohort studies with a low risk of confounding or bias and a moderate probability that the relation is causal and which are directly applicable to the target population</p> <p>or</p> <p>Extrapolation evidence from studies described in B.</p>
Grade D	<p>Non-analytic studies such as case reports, case series or expert opinion</p> <p>or</p> <p>Extrapolation evidence from studies described in C.</p>
Good practice point (GPP)	<p>Recommended best practice based on the clinical experience of the authors of the writing group.</p>

## Appendix F AGREE II compliance monitoring sheet

The guidelines of The Royal College of Pathologists comply with the AGREE II standards for good quality clinical guidelines. The sections of this guideline that indicate compliance with each of the AGREE II standards are indicated in the table.

AGREE standard	Section of guideline
<b>Scope and purpose</b>	
1 The overall objective(s) of the guideline is (are) specifically described	1
2 The health question(s) covered by the guideline is (are) specifically described	1
3 The population (patients, public, etc.) to whom the guideline is meant to apply is specifically described	Foreword, 1
<b>Stakeholder involvement</b>	
4 The guideline development group includes individuals from all the relevant professional groups	Foreword
5 The views and preferences of the target population (patients, public, etc.) have been sought	Foreword
6 The target users of the guideline are clearly defined	1
<b>Rigour of development</b>	
7 Systematic methods were used to search for evidence	Foreword
8 The criteria for selecting the evidence are clearly described	Foreword
9 The strengths and limitations of the body of evidence are clearly described	Foreword
10 The methods for formulating the recommendations are clearly described	Foreword
11 The health benefits, side effects and risks have been considered in formulating the recommendations	Foreword
12 There is an explicit link between the recommendations and the supporting evidence	4–6
13 The guideline has been externally reviewed by experts prior to its publication	Foreword
14 A procedure for updating the guideline is provided	Foreword
<b>Clarity of presentation</b>	
15 The recommendations are specific and unambiguous	4–8
16 The different options for management of the condition or health issue are clearly presented	4–8
17 Key recommendations are easily identifiable	4–8
<b>Applicability</b>	
18 The guideline describes facilitators and barriers to its application	Foreword, 1
19 The guideline provides advice and/or tools on how the recommendations can be put into practice	Appendices A–D
20 The potential resource implications of applying the recommendations have been considered	Foreword
21 The guideline presents monitoring and/or auditing criteria	9
<b>Editorial independence</b>	
22 The views of the funding body have not influenced the content of the guideline	Foreword
23 Competing interest of guideline development group members have been recorded and addressed	Foreword