



# Tissue pathways for dermatopathology

February 2024

**Authors:** Dr Ehab Husain, Aberdeen Royal Infirmary, NHS Grampian  
Dr Kristofer Holte, Royal Victoria Hospital, Belfast  
Dr Alice Hardwick, Aberdeen Royal Infirmary, NHS Grampian

<b>Unique document number</b>	G075
<b>Document name</b>	Tissue pathways for dermatopathology
<b>Version number</b>	3
<b>Produced by</b>	Dr Ehab Husain (writing lead), Consultant Histopathologist and Honorary Senior Lecturer (clinical), Aberdeen Royal Infirmary, NHS Grampian and the University of Aberdeen, Aberdeen. Dr Kristofer Holte, Consultant Dermatopathologist, Institute of Pathology, Royal Victoria Hospital, Belfast. Dr Alice Hardwick, Consultant Histopathologist, Aberdeen Royal Infirmary, NHS Grampian, Aberdeen.
<b>Date active</b>	November 2023 <b>(to be implemented within 3 months)</b>
<b>Date for full review</b>	November 2028
<b>Comments</b>	<p>This document replaces the 2nd edition of <i>Tissue pathway for dermatopathology</i>, published in 2019.</p> <p>In accordance with the College's pre-publications policy, this document was on the Royal College of Pathologists' website for consultation from 14 November to 12 December 2023. Responses and authors' comments are available to view on request following final publication of this tissue pathway.</p> <p><b>Dr Brian Rous</b> <b>Clinical Lead for Guideline Review</b></p>



The Royal College of Pathologists  
6 Alie Street, London E1 8QT  
Tel: 020 7451 6700  
Fax: 020 7451 6701  
Web: [www.rcpath.org](http://www.rcpath.org)

Registered charity in England and Wales, no. 261035  
© 2024, the Royal College of Pathologists

This work is copyright. You may download, display, print and reproduce this document for your personal, non-commercial use. Requests and inquiries concerning reproduction and rights should be addressed to The Royal College of Pathologists at the above address. First published: 2024.

## Contents

Foreword.....	3
1 Introduction.....	4
2 Staffing, workload and laboratory facilities: general considerations .....	5
3 Inflammatory dermatoses .....	6
4 Immunobullous disorders and other specimens requiring immunofluorescence .....	11
5 Scalp biopsies and hair specimens .....	15
6 Nail specimens .....	20
7 Skin specimens for benign lesions and benign neoplastic lesions including melanocytic lesions .....	22
8 Criteria for audit .....	25
9 References .....	26
Appendix A Summary table – Explanation of grades of evidence.....	29
Appendix B AGREE II guideline monitoring sheet .....	30



NICE has accredited the process used by the Royal College of Pathologists to produce its autopsy guidelines. Accreditation is valid for 5 years from 25 July 2017. More information on accreditation can be viewed at [www.nice.org.uk/accreditation](http://www.nice.org.uk/accreditation).

For full details on our accreditation visit: [www.nice.org.uk/accreditation](http://www.nice.org.uk/accreditation).

## Foreword

The tissue pathways published by the Royal College of Pathologists (RCPATH) are guidelines that enable pathologists to deal with routine surgical specimens in a consistent manner and to a high standard. This ensures that accurate diagnostic and prognostic information is available to clinicians for optimal patient care and ensures appropriate management for specific clinical circumstances. This guideline has been developed to cover most common circumstances. However, we recognise that guidelines cannot anticipate every pathological specimen type and clinical scenario. Occasional variation from the practice recommended in this guideline may therefore be required to report a specimen in a way that maximises benefit to the patient. In these circumstances, pathologists should be able to provide a clear rationale for any variation.

The guidelines themselves constitute the tools for implementation and dissemination of good practice.

The following stakeholders were consulted for this document:

- British Society for Dermatopathology
- British Association of Dermatologists.

No major organisational changes or cost implications have been identified that would hinder the implementation of the guideline.

The information used to develop this tissue pathway was obtained by undertaking a systematic search of PubMed database and existing NICE, UK and international guidance. Key terms searched included skin (hair and nail) pathology, biopsy, resection, grossing, immunopathology, immunobullous, immunofluorescence and immunohistochemistry (IHC) and dates searched were between August 2022 and June 2023. A total of 35 studies met the selection criteria and were considered for review. Published evidence was evaluated using modified SIGN guidance (see Appendix A). Consensus of evidence in the guideline was achieved by expert review. Gaps in the evidence were identified by College members via feedback received during consultation.

A formal revision cycle for all tissue pathways takes place on a 5-yearly basis. However, each year the College will ask the authors of the tissue pathways, in conjunction with the relevant subspecialty adviser to the College, to consider whether or not the document needs to be updated or revised. A full consultation process will be undertaken if major revisions are required. If minor revisions are required, an abridged consultation process

will be undertaken, whereby a short note of the proposed changes will be placed on the College website for 2 weeks for members' attention. If members do not object to the changes, the changes will be incorporated into the pathways and the full revised version (incorporating the changes) will replace the existing version on the College website. All changes will be documented in the data control section of the relevant pathway.

The tissue pathway has been reviewed by the Professional Guidelines team and was placed on the College website for consultation with the membership from 14 November to 12 December 2023. All comments received from the membership were addressed by the authors to the satisfaction of the Clinical Lead for Guideline Review.

The tissue pathways was developed without external funding to the writing group. The College requires the authors of guidelines to provide a list of potential conflicts of interest; these are monitored by the Professional Guidelines team and are available on request. The authors of this document have declared that there are no conflicts of interest.

## 1 Introduction

This document provides guidance on specimen handling and reporting of skin biopsies obtained for the assessment of inflammatory dermatoses, with separate sections dedicated to the handling of specimens requiring immunofluorescence and hair and nail specimens. It also provides a brief overview of specimen handling and reporting of non-neoplastic and benign neoplastic lesions, including benign melanocytic lesions.

Specific reference to specimens received from paediatric patients is not made in this pathway. It is anticipated that the majority of specimens received from this patient group for assessment of the conditions covered by this pathway can and should be managed in the same manner as set out below.

The specimens discussed in this guideline are expected to be encountered in the majority of histopathology departments in the UK, constituting a large volume of the skin work received and reported by histopathologists, both those in a general reporting setting and in centres with subspecialty reporting.

This tissue pathway aims to provide advice on the handling, processing and reporting of these specimens with reference to published literature. The focus is on promoting good practice to ensure a high standard of patient care across all departments throughout the UK.

Frequent reference is made throughout the document to the importance of clinical information in the accurate diagnosis of skin disorders, as well as appropriate site selection for specimen submission. The authors consider these 2 factors to be integral to the assessment and diagnosis of skin specimens, as well as underpinning the absolute need for clinicopathological correlation in the assessment of many skin specimens. Intrinsic to this approach is an appreciation of close working relationships between pathologists and local clinicians, to allow effective and accurate reporting of specimens to achieve best patient care. The need for second opinions and expert opinions is recognised and should be encouraged where required.

### **1.1 Target users of this guideline**

The primary users of this tissue pathway are trainee and consultant histopathologists, as well as dermatologists practising with the RCPATH Diploma in Dermatopathology. However, the pathway will also be of value to biomedical scientists involved in macroscopic description and dissection of skin biopsies and, going forward, potentially in the reporting of skin specimens by biomedical scientists. It is anticipated that the recommendations could also be used by dermatologists in the clinical setting in the selection of biopsy sites, as well as indicating the importance of clinical information in aiding accurate clinicopathological correlation.

## **2 Staffing, workload and laboratory facilities – general considerations**

### **2.1 Staffing and workload**

Departments reporting the specimen types described in this pathway should have an adequate number of pathologists, biomedical scientists, technical staff and clerical staff to function effectively. In general, staffing levels should follow the workload guidelines of the RCPATH. Pathologists should:

- participate in audit
- participate in an appropriate continuing professional development (CPD) scheme, such as the 1 provided by RCPATH
- consider participating in the National Specialist Dermatopathology External Quality Assurance (EQA) scheme.

Workload data should be recorded in a format that facilitates the determination and, therefore, appropriate allocation of resources involved, including adequate reporting time.

## **2.2 Laboratory facilities**

The laboratory should:

- be equipped to allow the recommended technical procedures to be performed safely
- be enrolled with the United Kingdom Accreditation Service (UKAS)
- participate in the UK National Specialist Dermatopathology EQA Scheme for various cellular pathology techniques and immunofluorescence (if applicable).

Reports should be held on an electronic database that has facilities to search and retrieve specific data and that is indexed according to SNOMED CT or antecedent versions of SNOMED T, M and P codes. It is acknowledged that existing laboratory information systems may not meet this standard; in this case, the ability to store data in this way should be considered when laboratory systems are to be replaced or upgraded.

## **3 Inflammatory dermatoses**

### **3.1 Indications**

This section refers to skin biopsies that have been sent for the assessment of inflammatory dermatoses. Specimens that have been sent for the assessment of immunobullous diseases, scalp and hair biopsies sent for assessment of alopecia, nail specimens and non-neoplastic or benign neoplastic lesions are covered in separate sections in this document.

### **3.2 Staffing**

Accurate diagnosis of skin biopsies taken for the assessment of inflammatory skin diseases requires adequate knowledge of the histopathological patterns of these diseases and the application of a diagnostic algorithm. It is advisable to have a lead subspecialist with a special interest in inflammatory dermatoses to promote the best practice and maximise diagnostic outcomes when dealing with these specimens. While not compulsory, it is recommended that this pathologist should consider participating in the National Specialist Dermatopathology EQA scheme. Specialist qualifications offered by the RCPATH (Diploma in Dermatopathology) and/or the European Union of Medical Specialists (International Board Certification in Dermatopathology) can be obtained by both

pathologists and dermatologists following appropriate training in dermatopathology, although neither are an absolute requirement to be a subspecialist lead in dermatopathology.

*[Level of evidence – GPP.]*

Due to morphological overlap between different inflammatory dermatoses, relying on histology alone might not be sufficient to reach a specific diagnosis. In this context, clinicopathological correlation is essential.<sup>1,2</sup> Where facilities and staff availability allow, a dedicated clinicopathological correlation (CPC) meeting is a useful adjunct to the diagnostic process in unusual or difficult inflammatory skin cases. These meetings allow pathologists and dermatologists to discuss cases, including access to greater clinical information and photographs, to reach either an accurate diagnosis or, if that is not possible, to at least limit the potential differential diagnoses for consideration. In some centres, these meetings are conducted in the outpatient setting, with patients present to be examined in person. They can also facilitate discussion of factors which may hinder accurate diagnosis and indicate further steps which may improve diagnostic yield. Accordingly, frequent attendance at these meetings by pathologists reporting inflammatory skin specimens is mandatory and adequate time should be given in job plans to facilitate this.

*[Level of evidence – D, GPP.]*

### **3.3 Specimen submission**

Providing adequate clinical information is of paramount importance in the pathological assessment of all specimens submitted for histopathological examination. The authors feel that this cannot be emphasised enough in relation to skin biopsies taken for the assessment of inflammatory dermatoses where, perhaps more so than in other surgical specimens, the diagnosis relies on clinicopathological correlation.<sup>2-5</sup>

Frequently, this is not the case. It is a common finding to receive biopsies with insufficient clinical information. In addition to the age and sex of the patient, the clinical history should include the site and duration of the current issue under investigation, as well as the distribution of the rash or specific lesions. Information should be provided regarding clinical differential diagnosis, past history of similar rashes/lesions, relevant systemic disease, as well as any relevant current or previous medication. In particular, it is essential that details concerning systemic or topical treatment, such as steroids, are recorded; these should include duration of treatment and, if applicable, when treatment was discontinued. Any

factors that might result in immune deficiency, such as previous organ transplant, must be recorded and history of recent travel should also be documented if relevant. Diagnostic accuracy of inflammatory skin diseases may be increased when the biopsy findings are correlated with clinical images, provided that the reporting pathologist has adequate familiarity with the clinical appearance of different inflammatory skin conditions;<sup>6</sup> to this end, access to clinical photography is desirable along with sufficient clinical information.

Selecting the appropriate site and technique of the biopsy is essential to obtain adequate and representative tissue sample for histopathological assessment;<sup>4</sup> for example, deeper biopsies, including a sufficient volume of subcutaneous adipose tissue, are required in cases of suspected panniculitis or large vessel vasculitis.<sup>7,8</sup> Inflammatory skin diseases have a life cycle with different phases of evolution with corresponding histological changes; therefore, it is important to select a recent active lesion without secondary changes, such as excoriation and ulceration, which might result in non-specific findings.<sup>4</sup>

Skin biopsies taken for assessment of inflammatory dermatoses are almost always received in 10% neutral buffered formalin. Some biopsies may be received in saline or Michel's solution if immunofluorescence is required; please refer to section 4.3.2 for further information regarding these specimens. Each biopsy should be placed in a separate, adequately labelled container including sufficient patient details, the nature of the specimen and the specimen site.

*[Level of evidence – D.]*

### **3.4 Specimen dissection/processing**

Inflammatory skin diseases are histologically assessed using both punch biopsies and incisional biopsies. The handling and dissection of skin biopsies can be performed by appropriately trained biomedical scientists, histopathology and dermatopathology trained medical personnel.

The macroscopic description should include the type of specimen (punch, incisional biopsy), along with 3-dimensional measurements including depth of the specimen. A comment should be made about the colour of epidermis and any lesion identified should be described with regards to size, type (papule, macule, vesicle, plaque etc. – see Box 1), borders (well-circumscribed, irregular), colour (homogenous or variegated) and shape.



**Box 1: Commonly used dermatological terms for use in macroscopic description.<sup>9</sup>**

Macule: a small (<1 cm) flat, non-palpable circumscribed area of change in skin colour.

Patch: larger (>1 cm) non-palpable circumscribed area of change in skin colour.

Papule: a raised, palpable lesion <0.5 cm in diameter.

Nodule: a raised, palpable lesion  $\geq$ 0.5 cm in diameter.

Plaque: a raised, palpable lesion usually flat-topped and >2 cm in diameter.

Vesicle: an elevated fluid-filled lesion <0.5 cm in diameter (contains clear fluid).

Bulla: an elevated fluid-filled lesion  $\geq$ 0.5 cm in diameter (contains clear fluid).

Pustule: an elevated fluid-filled lesion usually <0.5 cm filled with purulent fluid.

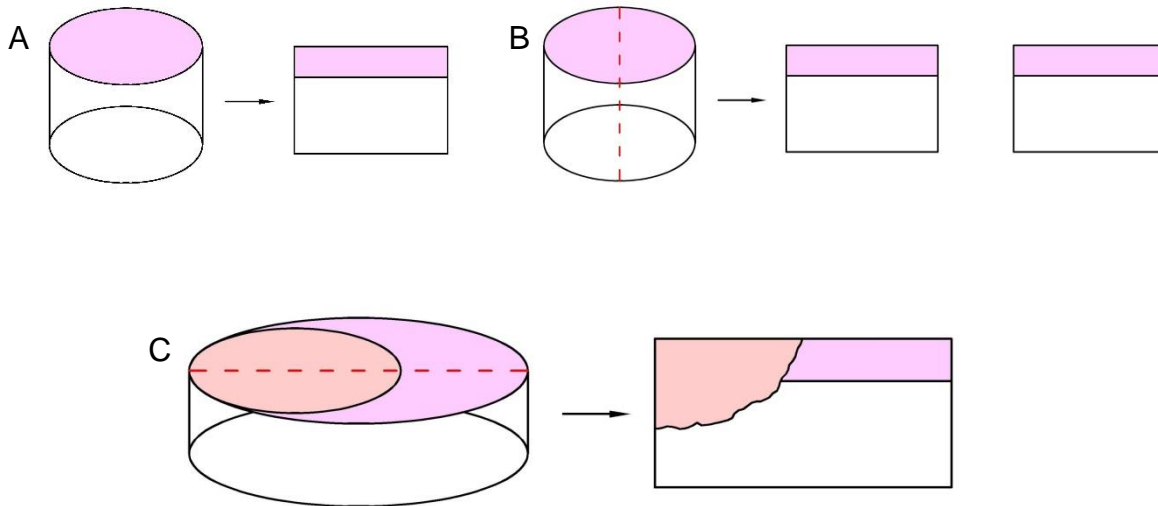
Erosion: loss of the outer layers of the epidermis; superficial and does not involve connective tissue (the dermis), therefore healing occurs without scarring.

Ulceration: loss of the full thickness of the epidermis with extension into the dermis; deeper lesions that have a great chance of healing with scarring.

Fissure: a linear crack in the epidermis, usually secondary to skin dryness and loss of elasticity.

Punch biopsies with a diameter of 4 mm or greater should be bisected longitudinally, while smaller punches can be embedded intact. Intact vesicles should not be cut through, as the roof and contents of the vesicle are important in histological assessment. The tissue must be embedded with the skin surface perpendicular to the plane of section (Figures 1A and B). Incisional biopsies usually comprise vaguely elliptical specimens, containing both lesional and normal skin. In most cases, these specimens should be bisected along their long axis to allow histological representation of lesional skin with the contrast of adjacent normal skin (Figure 1C). 3 levels should routinely be requested in the first instance. Further deeper levels or serial sectioning of the block are recommended in cases where the histological findings are expected to be focal or subtle.

**Figure 1: Diagram showing handling of small biopsy specimens and incisional biopsies. A:  $\leq 4$  mm punch biopsy and biopsies with intact vesicles, embedded intact. B:  $\geq 4$  mm punch biopsy, bisected and both halves embedded on cut face. C: Incisional biopsy, containing lesional material (pale oval) and normal skin, bisected along the long axis.**



### 3.5 Staining

In the first instance, a haematoxylin and eosin (H&E) stained section should be examined by light microscopy. This will inform the use of further special stains and immunohistochemistry in order to achieve a specific diagnosis. A short discussion of some useful ancillary tests is given below, but is not intended to be an exhaustive list.

Periodic acid-Schiff (PAS) with diastase (PASD) staining can be used to highlight fungal hyphae – consideration should be given to routinely performing PASD on all inflammatory biopsies for this purpose. Additionally PAS/PASD staining can highlight other features, such as a thickened subepidermal band in established lupus. Alcian blue and Hale's colloidal iron can be used to highlight dermal and perifollicular mucin. Elastic stains, such as elastic van Gieson (EVG), can be used to highlight alterations to dermal or vascular elastic distribution, while CD34 can be used to highlight alterations in the distribution of CD34-positive dermal cells. Martius Scarlet Blue (MSB) can be used to highlight fibrin, which may be useful to identify subtle foci of fibrinoid necrosis in cases of suspected vasculitis. Toluidine blue and CD117 can be used to highlight mast cells.

Special stains for organisms, including Gram, Grocott, Wade-Fite and Ziehl-Neelsen, can be used to attempt to identify bacterial, fungal, atypical mycobacterial and mycobacterial organisms, although confirmation by other microbiological methods is recommended.

Warthin-Starry or preferably Treponema (spirochaete) immunohistochemistry should be

used in the setting of suspected syphilis as it is more sensitive and specific than Warthin-Starry staining.<sup>10</sup>

### **3.6 Report content**

The report should state the type of specimen received, with a record of the components present (i.e. epidermis, dermis, subcutaneous adipose tissue and other tissues like muscle or cartilage). A description of the histological changes identified should be provided, along with a comment about any additional investigations performed including levels and/or special stains and what additional information these provided. By assimilating the provided clinical information, clinical photographs if provided and the histological changes identified, a diagnosis should be proffered. If it not possible to provide a single diagnosis, a list of potential differential diagnoses should be given for clinical consideration.

### **3.7 Frozen sections**

Frozen sections are infrequently encountered in dermatopathology practice in the assessment of inflammatory dermatoses. They may be seen rarely in cases of suspected toxic epidermal necrolysis or staphylococcal scalded skin syndrome to assess the level of cleavage and degree of epidermal necrosis. It may also be considered in the early stages of necrotising fasciitis. Pathologists dealing with frozen section requests should have adequate experience and competency in assessing such specimens.

## **4 Immunobullous disorders and other specimens requiring immunofluorescence**

### **4.1 Indications**

This section refers to skin specimens sent for immunofluorescence, usually in tandem with a specimen sent for routine histopathological assessment.

Immunofluorescence is primarily used in the assessment and classification of autoimmune blistering disorders and is considered the gold standard for the diagnosis of these conditions.<sup>11</sup> Immunofluorescence is an immunohistochemical technique used to detect either immunoreactants bound to tissue (immunoglobulins IgG, IgM and IgA, complement factor, C3 and, in some centres, fibrinogen) in direct immunofluorescence or circulating antibodies against a defined antigen in serum or blister fluid in indirect immunofluorescence.

Immunofluorescence antigen mapping can be used, either alone or in conjunction with transmission electron microscopy, in the classification of inherited epidermolysis bullosa.<sup>12</sup> Detailed discussion of specimens sent for inherited epidermolysis bullosa is beyond the scope of this pathway.

Immunofluorescence has a lesser role in the assessment of certain connective tissue disorders, such as lupus erythematosus, and as a diagnostic tool has largely been replaced by serological testing.<sup>13</sup> Immunofluorescence can be used to support a diagnosis of IgA-associated vasculitis (Henoch-Schönlein purpura), however the presence of IgA in association with vessel walls in adults is not specific for this diagnosis and can be seen in a wide range of non-vasculitic conditions.<sup>14</sup>

*[Level of evidence – D.]*

## **4.2 Staffing**

Immunofluorescence, salt-split skin analysis and immunofluorescence antigen mapping should be performed in a laboratory with adequate experience and competency in these techniques to ensure high quality results. Immunofluorescence should be interpreted by a pathologist with sufficient experience of the technique and should be assessed in conjunction with the histopathological changes seen in the routinely stained sections if provided.

## **4.3 Specimen submission**

Specimens received for immunofluorescence are overwhelmingly punch biopsies. For handling of accompanying formalin fixed specimens for routine histopathological assessment, please see section 3.4.

Specimens should be accompanied by an appropriate clinical history, as described in section 3.3. This should include whether there is a history of either local or systemic therapy, which may have suppressed underlying inflammatory pathways, altering the histologic pattern of disease. If clinically feasible, disease modifying drugs should be withheld for 2 to 4 weeks before biopsy,<sup>15</sup> although this is not always possible.

### **4.3.1 Selection of biopsy site**

Selection of the optimal site, as well as the optimal lesion, to biopsy is crucial with regards to immunofluorescence and histological analysis. These parameters vary depending on the suspected diagnosis and a didactic description of all variables is beyond the scope of this document but can be found elsewhere in review papers.<sup>4</sup>

In general terms, a biopsy from an intact fresh vesicle or bulla is recommended for light microscopy. If the blister is too large to be sampled by punch biopsy, either a punch biopsy of the edge of the bulla including intact skin and blister cavity is recommended, or a scooped shave with 'saucerisation' of the intact bulla for processing.<sup>16</sup> By selecting a fresh lesion, secondary changes such as epithelial regeneration, scarring and infection are minimised.<sup>15</sup>

For immunofluorescence, perilesional skin is recommended. This is variably defined as being within 5–10 mm of a lesion.<sup>17</sup> False negative immunofluorescence results can occur if lesional samples are taken due to consumption of immunoreactants, or if a specimen is taken too early in the prodromal stage, resulting in immunoreactants being at sub-detection levels.<sup>13</sup> Punch biopsies are adequate for immunofluorescence, however there are occasions where a broad shave may be appropriate, such as in dermatitis herpetiformis, allowing examination of a greater number of dermal papillae.<sup>13</sup>

In contrast to immunobullous disorders, biopsies taken for direct immunofluorescence in connective tissue diseases should be taken from established lesional skin,<sup>13</sup> although a biopsy from sun-protected non-lesional skin can be used in systemic lupus erythematosus.<sup>13,16</sup> In vasculitic lesions, samples taken for light microscopy should be taken from established (>72 hours) lesions, while samples for immunofluorescence should be from newly established (<24 hours) lesions.<sup>16</sup>

*[Level of evidence – D.]*

#### **4.3.2 Transport medium**

Specimens for light microscopy should be submitted in 10% neutral buffered formalin, as per section 3.3.

Specimens for direct immunofluorescence should be received in a suitable substrate, such as Michel's medium or saline. It is imperative that tissue submitted for immunofluorescence should not be accidentally contaminated with formalin; this is particularly relevant in the assessment of pemphigus, as even brief exposure to formalin can result in false negative results. The effect of formalin on immunofluorescence results in other immunobullous disorders may be less significant.<sup>16</sup> Saline may show better preservation of immunofluorescence, with some studies demonstrate that storage in isotonic saline at room temperature for 24 hours reduces or eliminates background IgG immunofluorescence signal and improves results, while other reports recommend rapid processing (<24 hours).<sup>18</sup> In contrast, specimens submitted in Michel's solution can remain

at room temperature for up to 6 months and retain their antigenicity. Salt-split skin specimens can be sent in either saline or Michel's solution. The transport medium used should be agreed with the processing laboratory locally and communication between those taking the biopsies and the receiving laboratory/pathologists is encouraged.

#### **4.4 Specimen dissection/processing**

Please refer to section 3.3 for handling of punch biopsies and incisional biopsies.

#### **4.5 Staining**

Immunofluorescence immunohistochemistry for selected immunoreactants should be performed in accordance with departmental standard operating procedures (SOPs) by laboratories that are accredited to undertake such work.

Exclusion of infective aetiologies should be considered depending on the light microscopy findings, and special stains for fungal and bacterial organisms can be performed (see 'inflammatory skin' sections).

If local facilities allow, a photomicrograph should be considered of a positive result to provide a permanent record of the finding. This can be useful as a governance tool, where the finding is unexpected in a given clinical context, as well as being useful for demonstrating at subsequent clinicopathological correlation meetings.

*[Level of evidence – GPP.]*

The immunofluorescent distribution pattern in bullous pemphigoid and epidermolysis bullosa acquisita can be similar, making differentiation of the 2 diseases difficult. In this scenario, split skin analysis can be used.<sup>18</sup> By separating the epidermis from the dermis before performing the immunofluorescence panel, it is possible to identify more precisely where immunoreactants have been deposited, with immunoreactants localising to the dermal aspect in epidermolysis bullosa.

Slides stained for immunofluorescence should be stored in a dry, dark place to prevent signal degradation due to the bleaching effect of exposing the signal to light.

#### **4.6 Report content**

In cases examined using immunofluorescence techniques, the report should state whether the test was direct or indirect and state the immunoreactants stained for. For each immunoreactant, a comment should be made as to whether the test was positive, showing specific deposition of immunoreactants, or negative/showing no specific deposition. In the

case of positive direct immunofluorescence, comment should be made on the following features:

- primary location of deposition:
  - in the case of autoimmune blistering disorders, this will either be in the basement membrane zone or demonstrating in an intercellular distribution
  - in the case of connective tissue disorders, deposition is in the dermoepidermal region, producing a 'lupus band'
  - in the case of vasculitis, deposition would be expected within vessel walls
- the pattern and, if applicable, the intensity, if multiple immunoreactants are detected, of the deposition in the case of autoimmune blistering disorders, either linear or granular, confluent or focal (i.e. granular IgA in dermal papillae of the basement membrane in dermatitis herpetiformis)
- the type of immunoreactant deposited (i.e. IgG, IgM, IgG, C3, fibrinogen)
- the location of any secondary deposits.<sup>19</sup>

These findings should be correlated with the clinical information supplied, along with the findings of any light microscopy examination and a preferred diagnosis offered. If it is not possible to offer a single diagnosis, a differential diagnosis should be given. In these cases, discussion at a CPC meeting should be considered to achieve an accurate diagnosis. If there are specific issues with the biopsy that prevented a definitive diagnosis being reached, such as a lesion with secondary changes, then re-biopsy of an appropriate lesion can be recommended in the report.

*[Level of evidence – GPP.]*

## **5 Scalp biopsies and hair specimens**

### **5.1 Indications**

This section refers to skin biopsies and hair specimens that have been sent for the assessment of hair loss/alopecia. For scalp biopsies that have been sent for assessment of an inflammatory dermatosis, a benign melanocytic or a benign neoplastic lesion, please refer to the relevant section of this document or dataset in the case of malignancy.

## **5.1 Staffing**

Scalp biopsies and hair specimens may occasionally be received as part of routine biopsy work in general histopathology laboratories. Such specimens will be more frequently received in local/regional specialist centres where clinicians may have a specialist interest in alopecia. Familiarity with normal hair anatomy is essential in the reporting of scalp biopsies. Each department should have access to at least 1 consultant dermatopathologist with an interest or experience in the reporting of scalp biopsies/alopecia.

Accurate reporting of scalp biopsies requires interpretation of histological features in the context of the clinical picture. The referring clinician should provide clear information on the duration, location and morphology of scalp abnormalities in addition to any relevant prior therapies or systemic illnesses. A list of potential differential diagnoses for the reporting histopathologist to address may be helpful. Centres with a specialist alopecia service and large numbers of scalp biopsies may benefit from regular alopecia CPC meetings.

## **5.2 Specimen submission**

1 or several biopsies may be submitted depending on the suspected diagnosis, clinical constraints and attempts to minimise patient morbidity. Most biopsies are submitted in 10% neutral buffered formalin for light microscopic examination.<sup>20</sup> Additional samples may be sent for direct immunofluorescence in Michel's medium or saline and should be dealt with as per section 4. The biopsy may be vertically pre-bisected by the clinician, with half submitted for each modality.<sup>21</sup> A hair sample (lacking the supporting dermis and subcutis) obtained via hair pull or hair pluck may be submitted, usually without fixative, for microscopic assessment of the hair follicle cycle. Hairs submitted for assessment of hair shaft disorders are obtained by clipping a sample close to the scalp, to prevent introducing unwanted traumatic artefactual changes that render the specimen non-diagnostic.

## **5.3 Specimen dissection/processing**

Biopsies can be examined in either the vertical or horizontal plane of section, both with inherent strengths and weaknesses. Horizontal and more complex sectioning protocols may require minimal additional training of laboratory personnel and the introduction of departmental SOPs. The approach taken is at the discretion of the reporting pathologist and should be selected to best highlight the relevant pathological features.



### **5.3.1 Vertical sections**

Vertical sections enable assessment of the full skin thickness, including the epidermis and dermoepidermal junction, an important region in several scarring alopecias.<sup>20,22</sup>

Additionally perifollicular inflammation, where present, is easily localised. Vertical sections contain comparatively few terminal hair follicles (4 to 6 per section), potentially missing focal, non-uniform diagnostic features unless the specimen is extensively sectioned.<sup>16,23</sup>

### **5.3.2 Horizontal sections**

Horizontal sections enable rapid assessment of hair follicle number, morphology and hair cycle status. All follicles are visualised, enabling the detection of non-uniform abnormalities. The dermoepidermal junction and papillary dermis are comparatively sub-optimally visualised. Horizontal sectioning is of particular use in the assessment of non-scarring alopecias.

Combining both vertical and horizontal sectioning provides the most complete histological assessment; this approach is relatively simple if 2 biopsies have been received for this purpose.<sup>22</sup> If 1 biopsy has been received, protocols exist allowing examination in both planes of sectioning without added workload or laboratory costs.<sup>20</sup> 2 such protocols are briefly outlined below in sections 5.4.3 and 5.4.4.

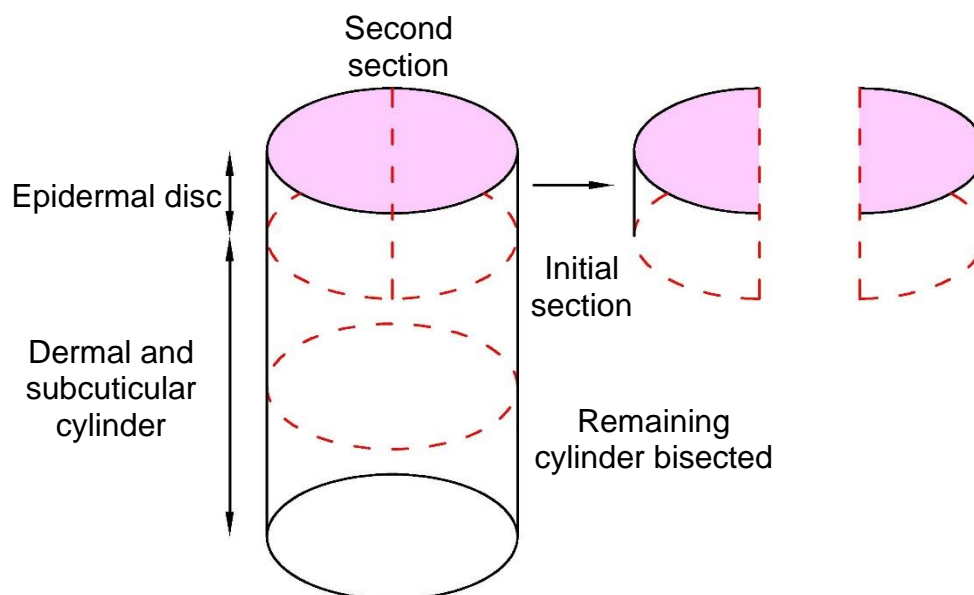
*[Level of evidence – C.]*

### **5.3.3 The HoVert technique**

The biopsy is first transected approximately 1 mm below the skin surface in the horizontal plane to produce an epidermal disc and a lower portion. The epidermal disc is subsequently bisected vertically and embedded on edge obtaining sections through the epidermis and dermoepidermal junction. The lower portion, depending on length, is horizontally cut into 2 or 3 sections with deep surfaces inked for orientation. The inked surfaces are embedded producing horizontal sections from along the length of the hair follicles (Figure 2). Examination at several levels may be required to assess the hair follicle in its entirety. The epidermal disc and lower portion can be submitted in the same cassette, conserving laboratory resources.<sup>20</sup>

*[Level of evidence – D.]*

**Figure 2: The HoVert technique (adapted from Nguyen *et al.*, 2011).<sup>20</sup>**



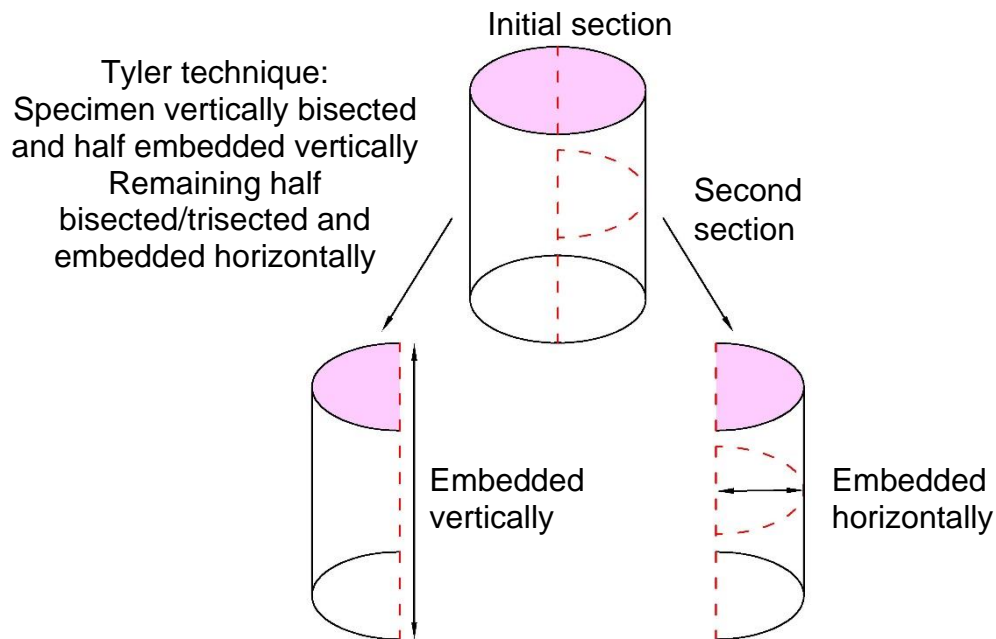
HoVert technique:  
Epidermal disc, bisected and embedded vertically  
Remaining cylinder bisected/trisected and embedded horizontally

### 5.3.4 The Tyler technique

The 4 mm biopsy is first bisected vertically. 1 half is embedded in the vertical plane of section, without further alteration. The other half is further bisected horizontally, with the deep surfaces inked for orientation. Embedding of inked surfaces produces horizontal sections from along the length of the hair follicles (Figure 3).<sup>24</sup>

*[Level of evidence – D.]*

**Figure 3: The Tyler technique (adapted from Elston, 2012).<sup>24</sup>**



### 5.3.5 Hair samples

Hair samples are prepared in a dry mount. A rectangular frame with double-sided sticky tape edges (Frame-Seal incubation chamber) may be employed to affix hairs to the slide. A cover glass is then placed over the Frame-Seal. Alternative adhesives may be used.<sup>25</sup>

## 5.4 Staining

Special stains and immunohistochemistry can highlight specific anatomical regions within the hair follicle. Giemsa, Toluidine blue and Ziehl-Neelsen stain the inner root sheath; Ziehl-Neelsen in addition stains hair shafts. Staining of the inner root sheath helps highlight premature desquamation in central centrifugal cicatricial and other alopecias.<sup>26</sup> CD34 stains cells of the outer root sheath. CK15 stains the follicular bulge region, which is lost early in scarring alopecia.<sup>26</sup>

PAS with diastase will demonstrate any fungal hyphae within or around hair shafts; it also highlights thickening of the basement membrane zone in longstanding lesions of lupus.<sup>21</sup> Both Alcian blue and Hale's colloidal iron stain excess dermal mucin and mucinous perifollicular fibroplasia. Elastic stains such as EVG highlight the presence of fibrous tracts (follicular scars).<sup>26</sup> CD3 highlights lymphocytes in a peribulbar location and within fibrous tracts in alopecia areata.<sup>21</sup> CD123 stains clusters of plasmacytoid dendritic cells in alopecia secondary to lupus. The presence of treponemes, highlighted with specific immunohistochemistry, confirms syphilitic alopecia.

*[Level of evidence – D.]*

#### **5.4.1 Direct immunofluorescence**

Perifollicular cytooid bodies, commonly staining with IgM, is suggestive of lichen planopilaris. Granular deposition of immunoglobulins and C3 along the dermoepidermal junction supports a diagnosis of cutaneous lupus.<sup>27</sup> Direct immunofluorescence will also assess for autoimmune bullous diseases, which can rarely present with alopecia; for further details, see section 4.

### **5.5 Report content**

A pattern-based approach is employed to analyse scalp biopsies. The particular approach varies by personal preference; however, for cicatricial alopecia, most pathologists follow the schema produced by the North American Hair Research Society.<sup>28</sup> Wherever possible, efforts should be made to favour a specific diagnosis, addressing the clinical differential diagnoses provided by the referring clinician.

## **6 Nail specimens**

### **6.1 Indications**

A wide range of inflammatory, melanocytic and neoplastic conditions can affect the nail unit. The nail may be sampled for diagnostic or therapeutic purposes.

### **6.2 Staffing**

Nail specimens may occasionally be received as part of the routine biopsy material received in general histopathology laboratories. Such specimens will be more frequently received in local/regional specialist centres where clinicians may have a specialist interest in nail disease. Reporting of nail biopsies does not require specialist expertise in dermatopathology, however familiarity with normal nail anatomy is essential. Each department should have access to at least 1 consultant dermatopathologist with interest or experience in the reporting of nail specimens, who should partake in the National Specialist Dermatopathology EQA scheme.

Accurate reporting of nail specimens requires interpretation of histological features in the context of the clinical presentation. The referring clinician should provide clear information on the duration, location and morphology of any abnormalities in addition to any relevant

prior therapies or systemic illnesses. A list of potential differential diagnoses for the reporting histopathologist to address may be helpful.

### **6.3 Specimen submission**

Nail clippings are commonly submitted without fixative. Most other nail specimens are submitted in 10% neutral buffered formalin. The nail may be orientated with ink, a suture or affixed to a paper template.<sup>29,30</sup> If the plate and epithelium are received adherent to one another, they should not be separated to prevent specimen loss and help maintain orientation.<sup>31</sup> If, however, the nail plate and epithelium are received detached, submission in separate cassettes may enable more tailored processing.

### **6.4 Specimen dissection/processing**

Specimens are conventionally sectioned longitudinally with respect to the nail unit and digit. In larger excisional specimens, a combination of longitudinal and transverse sections may be employed to allow more comprehensive margin assessment. Nail clippings are submitted on edge.

Processing nail specimens is challenging as they commonly contain both rigid nail plate and more delicate epithelium. Before sectioning, the rigid nail plate requires softening to prevent shattering and possible specimen loss. A variety of softening agents are available, including phenol, trichloroacetic acid, cedar oil, chitin softening agent, potassium hydroxide, Tween, potassium thioglycolate and several commercial softeners, such as detergents, depilatory creams and fabric conditioners.<sup>32</sup>

Decalcification solutions, often employed for bone processing, potentially damage tissue and should be avoided.<sup>33</sup> Tissue adherence to slides can be another source of challenge and may be improved by pre-treating the glass slides with albumin, glycerol or gelatin. Plastic embedding overcomes nail rigidity and tissue adherence issues, but is costly and labour intensive with a longer processing time.<sup>34</sup>

*[Level of evidence – GPP.]*

### **6.5 Staining**

PAS and Gomori methenamine silver are equally efficacious in the identification of fungi. The detection of red blood cells can be aided with a modified benzidine stain.<sup>35</sup> Conversion of haemoglobin to haemosiderin does not occur in the nail plate/subungual space,

rendering hemosiderin stains such as Perls Prussian blue unhelpful.<sup>32</sup> Fontana-Masson stain can highlight melanin granules.

Several immunohistochemical stains are available for melanocytic lesions, including Melan A, SOX10, HMB45, MITF, S100 and PRAME. Melan A stains melanocyte cytoplasm including dendritic processes, potentially overestimating melanocyte density. SOX10 and MITF, though not lineage specific, are nuclear stains that aid in precise quantification of melanocytes. S100 may fail to stain some melanocytes, particularly within the nail matrix.<sup>36</sup> S100 and SOX10 are commonly the only immunohistochemical stains that label desmoplastic melanomas. PRAME can be useful in distinguishing melanocytic naevi from melanomas.<sup>37</sup> Depending on the clinical context and personal preference, a panel of melanocytic immunostains may be required to optimally assess melanocytic lesions.

Immunostaining with Ki67 and p53 may be useful in distinguishing subungual keratoacanthomas from squamous cell carcinoma, both being stronger and more diffuse in the latter disease.<sup>34</sup>

*[Level of evidence – D.]*

## **6.6 Report content**

The report should provide a summary of the gross and histological findings followed by either a definitive diagnosis or histopathological differential diagnosis. Any additional investigations including special stains, immunohistochemistry, review of clinical images or prior biopsies should be included in the report.

# **7 Skin specimens for benign lesions and benign neoplastic lesions including melanocytic lesions**

## **7.1 Indications**

This section refers to skin biopsies and excisional specimens that have been sent for the assessment of benign skin lesions. For biopsies that have been sent for an inflammatory dermatosis, alopecia or a nail condition, please refer to the relevant section.

## **7.2 Staffing**

Skin specimens taken for benign lesions constitute a substantial proportion of the routine biopsy material received in general histopathology laboratories. Most are of low

complexity, lending to delegation of the macroscopic description, dissection and sampling to appropriately trained and supported biomedical scientists, where appropriate. This is aided by following well-defined departmental SOPs, regular audit and engaging in quality assurance processes.

Reporting of benign skin specimens does not require specialist expertise in dermatopathology. Pathologists reporting dermatopathology should partake in an appropriate EQA scheme. Lead pathologists, or pathologists whose work consists predominantly of dermatopathology, should participate in the dermatopathology EQA scheme.

### **7.3 Specimen submission**

Specimens are commonly submitted in 10% neutral buffered formalin. The size of the specimen should be measured in 3 dimensions. If a lesion is visualised, its characteristics and dimensions, including the distance from the nearest peripheral excision margin, should be recorded. For melanocytic lesions, additional characteristics should be recorded, including lesional symmetry, variability of pigmentation and regularity of the lesion border. The referring clinician may have orientated the specimen by means of a suture or inking, if so this should be documented.

*[Level of evidence – GPP.]*

### **7.4 Specimen dissection/processing**

Although not mandatory, consideration should be given to inking the surgical margins of excisional specimens, particularly if there is the possibility of incomplete excision. For orientated specimens, this can be facilitated by the application of different coloured inks to different excision margins. The approach to specimen dissection is tailored according to the specimen size and the presence, location and uniformity of any lesion(s).

The following general principles apply. Specimens under 4 mm in diameter should be submitted for processing without sectioning. Punch biopsies, shave or curetted specimens 4 mm or more in surface diameter may be bisected or trisected along their long axis, perpendicular to the skin surface. If the lesion is very small, consider sectioning adjacent to the lesion, in case levelling of the block to obtain a complete face ('facing') removes or exhausts all lesional tissue.

Larger excision specimens should be cut at regular 2–3 mm intervals so that the closest macroscopically visible peripheral and deep excision margins can be assessed

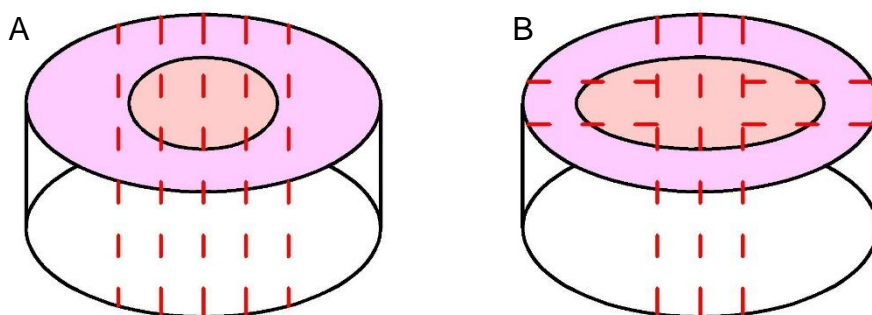
histologically. In most instances, this will require transverse rather than longitudinal sectioning (Figure 4A). If the lesion is clearly identified, well circumscribed and distant from the polar margins of the ellipse, their submission is discretionary. In very large excision specimens, the peripheral margin may be sampled at multiple selected points (Figure 4B). An annotated diagram may provide useful documentation of sampling and aid reporting. If facilities exist, an annotated digital image can be produced visually demonstrating the origin of blocks.

The number of sections submitted from a case is similarly discretionary and consideration should be given to the clinical diagnosis, size and macroscopic findings. Lesions with uniform features such as cysts and lipomas may require minimal sampling. Larger lesions with a heterogeneous appearance generally require submission of several sections to ensure assessment of the full range of histological features. When the lesion is ill-distinct or not apparent, all of the specimen should be submitted. Pigmented lesions, if clinically or macroscopically atypical, should be submitted in their entirety where possible.<sup>15,17</sup> Large pigmented lesions with focal abnormal areas, such as giant congenital naevi or naevus spilus, where submission of the entire lesion is not feasible, should have all abnormal areas sampled.<sup>15</sup>

In the setting where more than 1 lesion has been removed in an ellipse, the above principles still apply. Sections must be taken to demonstrate the full range of histological features and also the closest excision margins for both/all of the lesions.

*[Level of evidence – GPP.]*

**Figure 4: Diagrams showing the handing of excision specimens. A: Transverse sections in small specimens. B: Assessment of large size samples at multiple points.**





## 7.5 Staining

A wide range of special and immunohistochemical stains can be employed in lesional dermatopathology to establish a diagnosis. This is informed by the clinical context and the histological differential diagnosis. Comments regarding melanocytic immunohistochemistry can be found in section 6.5. Detailed discussion is beyond the scope of this guideline.

## 7.6 Report content

The report should provide a summary of the gross and histological findings followed by either a definitive diagnosis or histopathological differential diagnosis. Any additional investigations including special stains, immunohistochemistry, review of clinical images or prior biopsies should be included in the report.

It is good practice to comment on excision margins, particularly in regard to naevi, as depending on the degree of dysplasia, if present, a close proximity to the excision margins may lead to re-excision.

*[Level of evidence – D.]*

## 8 Criteria for audit

The following are recommended by the RCPATH as key assurance indicators (see [Key assurance indicators for pathology services](#), November 2019):

- histopathology cases that are reported, confirmed and authorised within 7 to 10 calendar days of the procedure
  - standard: 80% of cases must be reported within 7 calendar days and 90% within 10 calendar days.

Where clinically appropriate, histopathology cases must be reported, confirmed and authorised within an agreed turnaround time between service providers and service users that may deviate from the 7 to 10 days standard.

## 9 References

1. Rajaratnam R, Smith AG, Biswas A, Stephens M. The value of skin biopsy in inflammatory dermatoses. *Am J Dermatopathol* 2009;31:350–353.
2. Tod B, Jordaan HF, Schneider JW. Retrospective value of skin biopsy in histologically confirmed cases of the perivascular dermatitis subgroup of the inflammatory dermatoses. *Am J Dermatopathol* 2016;38:26–32.
3. Sellheyer K, Bergfeld WF. "Lesion," "rule out...", and other vagaries of filling out pathology requisition forms. *J Am Acad Dermatol* 2005; 52:5:914–915.
4. Sina B, Kao GF, Deng AC, Gaspari AA. Skin biopsy for inflammatory and common neoplastic skin diseases: optimum time, best location and preferred techniques. A critical review. *J Cutan Pathol* 2009;36:505–510.
5. Llamas-Velasco M, Paredes BE. Basic concepts in skin biopsy. Part I. *Actas Dermosifiliogr* 2012;103:12–20.
6. Cerroni L, Argenyi Z, Cerio R, Facchetti F, Kittler H, Kutzner H *et al.* Influence of evaluation of clinical pictures on the histopathologic diagnosis of inflammatory skin disorders. *J Am Acad Dermatol* 2010; 63: 647–652.
7. Mimouni D, Ng PP, Rencic A, Nikolskaia OV, Bernstein BD, Nousari HC. Cutaneous polyarteritis nodosa in patients presenting with atrophie blanche. *Br J Dermatol* 2003;148:789–794.
8. Sellheyer K, Nelson P, Bergfeld WF. Inadequate biopsy technique and specimen size: an alarming trend that compromises patient care and an appeal to our clinical colleagues. *Arch Dermatol* 2010;146:1180–1181.
9. Holte K, McIntyre G. *The Skin (Integument): PART I*, in Perry M (Ed.) *Diseases and Injuries to the Head, Face and Neck: A Guide to Diagnosis and Management*. New York City, USA: Springer, 2021.
10. Hoang MP, High WA, Molberg KH. Secondary syphilis: a histologic and immunohistochemical evaluation. *J Cutan Pathol* 2004;31:595–599.
11. Giurdanella F, Diercks GFH, Jonkman MF, Pas HH. Laboratory diagnosis of pemphigus: direct immunofluorescence remains the gold standard. *Br J Dermatol* 2016;175:185–186.

12. Bardhan A, Bruckner-Tuderman L, Chapple ILC, Fine JD, Harper N, Has C *et al*. Epidermolysis bullosa. *Nat Rev Dis Primers* 2020;6: 78.
13. Kim RH, Brinster NK. Practical direct immunofluorescence. *Am J Dermatopathol* 2020;42:75–85.
14. Larson AR, Granter SR. Utility of immunofluorescence testing for vascular IgA in adult patients with leukocytoclastic vasculitis. *Am J Clin Pathol* 2014;142:370–374.
15. Sleiman R, Kurban M, Abbas O. Maximizing diagnostic outcomes of skin biopsy specimens. *Int J Dermatol* 2013;52:72–78.
16. Elston DM, Stratman EJ, Miller SJ. Skin biopsy: Biopsy issues in specific diseases. *J Am Acad Dermatol* 2016;.74:1–16.
17. Llamas-Velasco M, Paredes BE. Basic concepts in skin biopsy. Part I. *Actas Dermosifiliogr* 2012;103:12–20.
18. Vodegel RM, de Jong MCJM, Meijer HJ, Weytingh MB, Pas HH, Jonkman MF. Enhanced diagnostic immunofluorescence using biopsies transported in saline. *BMC Dermatol* 2004;4:10.
19. Shetty VM, Subramaniam K, Rao R. Utility of immunofluorescence in dermatology. *Indian Dermatol Online J* 2017;8:1–8.
20. Nguyen JV, Hudacek K, Whitten JA, Rubin AI, Seykora JT. The HoVert technique: a novel method for the sectioning of alopecia biopsies. *J Cutan Pathol* 2011;38:401–406.
21. Stefanato CM. Histopathologic diagnosis of alopecia: clues and pitfalls in the follicular microcosmos. *Diagn Histopathol* 2020;26:114–127.
22. Bathish N, Izhak OB, Shemer A, Bergman R. A study of serial vertical sectioning of scalp biopsies to increase the histological diagnostic yield in alopecias. *J Eur Acad Dermatol Venereol* 2010;24:709–715.
23. Elston DM, McCollough ML, Angeloni VL. Vertical and transverse sections of alopecia biopsy specimens: combining the two to maximize diagnostic yield. *J Am Acad Dermatol* 1995;32:454–457.
24. Elston D. The 'Tyler technique' for alopecia biopsies. *J Cutan Pathol* 2012;39:306.

25. Smith VV, Anderson G, Malone M, Sebire NJ. Light microscopic examination of scalp hair samples as an aid in the diagnosis of paediatric disorders: retrospective review of more than 300 cases from a single centre. *J Clin Pathol* 2005;58:1294–1298.
26. LaSenna C, Miteva M. Special Stains and Immunohistochemical Stains in Hair Pathology. *Am J Dermatopathol* 2016;38:327–337.
27. Trachsler S, Trueb RM. Value of direct immunofluorescence for differential diagnosis of cicatricial alopecia. *Dermatology* 2005;211:98–102.
28. Olsen EA, Bergfeld WF, Cotsarelis G, Price VH, Shapiro J, Sinclair R *et al*. Summary of North American Hair Research Society (NAHRS)-sponsored Workshop on Cicatricial Alopecia, Duke University Medical Center. *J Am Acad Dermatol* 2003;48:103–110.
29. Jellinek N. Nail matrix biopsy of longitudinal melanonychia: diagnostic algorithm including the matrix shave biopsy. *J Am Acad Dermatol* 2007;56:803–810.
30. Reinig E, Rich P, Thompson CT. How to submit a nail specimen. *Dermatol Clin* 2015;33:303–307.
31. Wlodek C, Lecerf P, Andre J, Ruben BS, de Berker D. An international survey about nail histology processing techniques. *J Cutan Pathol* 2017;44:749–756.
32. Rubin A, Jellinek NJ, Ralph Daniel III C, Scher RK. *Scher and Daniel's Nails: Diagnosis, Surgery, Therapy (4<sup>th</sup> edition)*. London, UK: Springer Link, 2018.
33. Grover C, Bansal S. Nail biopsy: A user's manual. *Indian Dermatol Online J* 2018;9:3–15.
34. Stewart CL, Rubin AI. Update: Nail unit dermatopathology. *Dermatol Ther* 2012;25:551–568.
35. Martin B. Nail histopathology. *Actas Dermosifiliogr* 2013;104:564–578.
36. Theunis A, Richert B, Sass U, Lateur N, Sales F, André J. Immunohistochemical study of 40 cases of longitudinal melanonychia. *Am J Dermatopathol* 2011;33:27–34.
37. Parra O, Linos K, Li Z, Yan S. PRAME expression in melanocytic lesions of the nail. *J Cutan Pathol* 2022;49:610–617.

## Appendix A Summary table – Explanation of grades of evidence

(modified from Palmer K *et al. BMJ* 2008; 337:1832)

Grade (level) of evidence	Nature of evidence
Grade A	<p>At least 1 high-quality meta-analysis, systematic review of randomised controlled trials or a randomised controlled trial with a very low risk of bias and directly attributable to the target population</p> <p>or</p> <p>A body of evidence demonstrating consistency of results and comprising mainly well-conducted meta-analyses, systematic reviews of randomised controlled trials or randomised controlled trials with a low risk of bias, directly applicable to the target cancer type.</p>
Grade B	<p>A body of evidence demonstrating consistency of results and comprising mainly high-quality systematic reviews of case-control or cohort studies and high-quality case-control or cohort studies with a very low risk of confounding or bias and a high probability that the relation is causal and which are directly applicable to the target population</p> <p>or</p> <p>Extrapolation evidence from studies described in A.</p>
Grade C	<p>A body of evidence demonstrating consistency of results and including well-conducted case-control or cohort studies and high-quality case-control or cohort studies with a low risk of confounding or bias and a moderate probability that the relation is causal and which are directly applicable to the target population</p> <p>or</p> <p>Extrapolation evidence from studies described in B.</p>
Grade D	<p>Non-analytic studies such as case reports, case series or expert opinion</p> <p>or</p> <p>Extrapolation evidence from studies described in C.</p>
Good practice point (GPP)	<p>Recommended best practice based on the clinical experience of the authors of the writing group.</p>

## Appendix B AGREE II guideline monitoring sheet

The autopsy guidelines of The Royal College of Pathologists comply with the AGREE II standards for good quality clinical guidelines. The sections of this autopsy guideline that indicate compliance with each of the AGREE II standards are indicated in the table.

AGREE standard	Section of guideline
<b>Scope and purpose</b>	
1 The overall objective(s) of the guideline is (are) specifically described	1
2 The health question(s) covered by the guideline is (are) specifically described	1
3 The population (patients, public, etc.) to whom the guideline is meant to apply is specifically described	Foreword
<b>Stakeholder involvement</b>	
4 The guideline development group includes individuals from all the relevant professional groups	Foreword
5 The views and preferences of the target population (patients, public, etc.) have been sought	N/A
6 The target users of the guideline are clearly defined	1
<b>Rigour of development</b>	
7 Systematic methods were used to search for evidence	Foreword
8 The criteria for selecting the evidence are clearly described	Foreword
9 The strengths and limitations of the body of evidence are clearly described	Foreword
10 The methods for formulating the recommendations are clearly described	Foreword
11 The health benefits, side effects and risks have been considered in formulating the recommendations	Foreword, 1
12 There is an explicit link between the recommendations and the supporting evidence	Throughout
13 The guideline has been externally reviewed by experts prior to its publication	Foreword
14 A procedure for updating the guideline is provided	Foreword
<b>Clarity of presentation</b>	
15 The recommendations are specific and unambiguous	2–7
16 The different options for management of the condition or health issue are clearly presented	2–7
17 Key recommendations are easily identifiable	2–7
<b>Applicability</b>	
18 The guideline describes facilitators and barriers to its application	Foreword
19 The guideline provides advice and/or tools on how the recommendations can be put into practice	1–7
20 The potential resource implications of applying the recommendations have been considered	Foreword
21 The guideline presents monitoring and/or auditing criteria	8
<b>Editorial independence</b>	
22 The views of the funding body have not influenced the content of the guideline	Foreword
23 Competing interest of guideline development group members have been recorded and addressed	Foreword