

## OSPE Sample questions

### Sample station 1: Questions 1-4

- 1) A specimen of serum was received from a 32-year old woman who attended the antenatal clinic with a request for syphilis serology. The results are given below.

EIA: Total Antibody	positive
EIA: IgM	negative
TPPA:	positive (>1:1280)
RPR:	positive (1:2)

- (a) How would you interpret these results? (1 mark)  
(b) What advice would you offer? (6 marks)

2) ANSWER question 1

(a) \_\_\_\_\_

(b) \_\_\_\_\_

\_\_\_\_\_

\_\_\_\_\_

- 2) A bronchoalveolar lavage (BAL) sample from a 29-year-old woman in intensive care was tested with an influenza A (H1N1) virus real time PCR assay. The assay targets the haemagglutinin (H1) gene and includes an internal positive control (IPC), added to the sample prior to extraction.

Sample & assay	PCR Target	PCR result
Negative control	H1	Negative
Negative control spiked with IPC	IPC	Positive
Positive control H1	H1	Negative
Positive control H1 spiked with IPC	IPC	Positive
BAL sample spiked with IPC	H1	Negative
BAL sample spiked with IPC	IPC	Positive

- a) What is the key finding from review of this worksheet? (2 marks)  
b) Give a possible explanation for this. (1 mark)  
c) How would you report this result? (2 marks)

- 3) ANSWER question 2

(a)

(b)

(c)

- 3) A 71-year old man receiving treatment for acute lymphoblastic leukaemia developed dry cough and fever. He was treated empirically with meropenem but his symptoms had not improved after 4 days.

A CT scan of chest revealed diffuse interstitial infiltrate with no focal nodular or cavitory lesions.

Serum was tested for fungal biomarkers (normal ranges in brackets):

beta-D-glucan (BDG)	530pg/mL	(<80).
galactomannan	0.3 index	(<0.5)

- (a) What is the most important diagnosis to consider? (1 mark)  
(b) What is the diagnostic role of serum beta-D-glucan in this context? (2 marks)  
(c) What advice would you give about confirming the diagnosis? (3 marks)

ANSWER question 3

4)

(a) \_\_\_\_\_

(b) \_\_\_\_\_

(c) \_\_\_\_\_

\_\_\_\_\_

- 4) A 3 year-old girl developed persistent fever and a widespread rash while receiving induction chemotherapy for acute lymphoblastic leukaemia. A biopsy from one of the skin lesions was cultured, from which colonies of a mould grew after 96 hours of incubation.

Microscopy of these colonies, mounted on lactophenol cotton blue (x400) are shown in the image.

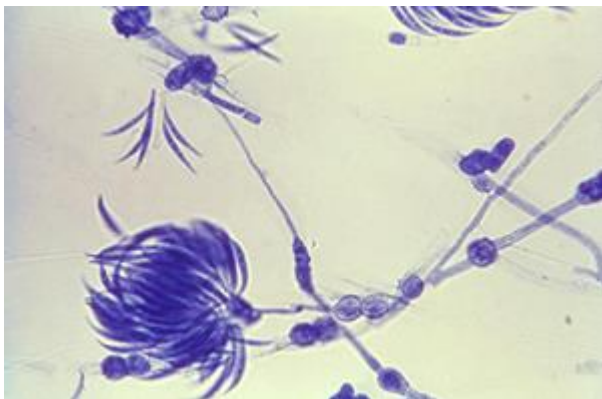
- (a) What is the identity of the organism? (2 marks)  
(b) What is the most appropriate initial antimicrobial treatment? (2 marks)

ANSWER question 4

(a)

(b)

#### IMAGE FOR Q4



## Sample station 2: Questions 1 & 2

You have been tasked with choosing the antibiotic disks to be included in a pair of 6-disk dispensers for direct antimicrobial susceptibility testing (AST) of inpatient urine specimens.

### Question 1

For each of the 6 places available in the two antibiotic disk dispensers, please choose an appropriate antimicrobial for direct antimicrobial susceptibility testing (AST) of inpatient urine specimens in your local laboratory.

### ANSWER - question 1

	<b>Antimicrobials – dispenser 1</b>	<b>Antimicrobials – dispenser 2</b>
1		
2		
3		
4		
5		
6		

