



## Standards and datasets for reporting cancers

### Dataset for the histopathological reporting of carcinomas of the hypopharynx, larynx and trachea

June 2023

**Authors:** Dr Brendan Conn (lead author), Royal Infirmary of Edinburgh (NHS Lothian)  
Dr Cordelia Howitt, University Hospitals of Derby and Burton NHS Foundation Trust  
Dr Ann Sandison, Guys & St Thomas's NHS Trust, London

<b>Unique document number</b>	G113
<b>Document name</b>	Dataset for the histopathological reporting of carcinomas of the larynx and hypopharynx
<b>Version number</b>	2
<b>Produced by</b>	Dr Brendan Conn is a consultant pathologist at the Royal Infirmary of Edinburgh, NHS Lothian. Dr Cordelia Howitt is a consultant pathologist at University Hospitals of Derby and Burton NHS Foundation Trust. Dr Ann Sandison is a consultant pathologist at Guys and St Thomas's NHS Trust, London.
<b>Date active</b>	June 2023 <b>(to be implemented within 3 months)</b>
<b>Date for full review</b>	June 2026
<b>Comments</b>	<p>This document will replace the <i>Dataset for histopathology reporting of mucosal malignancies of the larynx</i> published in November 2013.</p> <p>In accordance with the College's pre-publications policy, this document was on The Royal College of Pathologists' website for an abridged consultation from 20 April to 18 May 2023. Responses and authors' comments are available to view on final publication.</p> <p><b>Dr Brian Rous</b> <b>Clinical Lead for Guideline Review</b></p>

The Royal College of Pathologists  
6 Alie Street, London E1 8QT  
Tel: 020 7451 6700  
Fax: 020 7451 6701  
Web: [www.rcpath.org](http://www.rcpath.org)

Registered charity in England and Wales, no. 261035  
© 2023, The Royal College of Pathologists

This work is copyright. You may download, display, print and reproduce this document for your personal, non-commercial use. Requests and inquiries concerning reproduction and rights should be addressed to The Royal College of Pathologists at the above address. First published: 2023.



## Contents

Foreword .....	3
1 Introduction .....	4
2 Clinical information required for the diagnosis of carcinomas of the larynx and hypopharynx.	5
3 Receipt and preparation of specimens before dissection .....	6
4 Specimen handling and block selection .....	7
5 Data items .....	13
6 Diagnostic coding and staging .....	22
7 Reporting of small biopsy specimens .....	22
8 Frozen section diagnosis .....	23
9 Support of research and clinical trials .....	23
10 Specific aspects of individual tumours not covered elsewhere .....	23
11 Criteria for audit .....	23
12 References .....	25
Appendix A SNOMED coding.....	31
Appendix B TNM classification .....	33
Appendix C Reporting proforma for carcinomas of the larynx and hypopharynx .....	35
Appendix D Reporting proforma for carcinomas of the larynx and hypopharynx in list format ....	38
Appendix E Summary table – explanation of grades of evidence.....	46
Appendix F AGREE II guideline monitoring sheet .....	47



NICE has accredited the process used by the Royal College of Pathologists to produce its cancer datasets. Accreditation is valid for five years from 25 July 2017. More information on accreditation can be viewed at [www.nice.org.uk/accreditation](http://www.nice.org.uk/accreditation).

For full details on our accreditation visit: [www.nice.org.uk/accreditation](http://www.nice.org.uk/accreditation).

## Foreword

The Cancer datasets published by The Royal College of Pathologists (RCPATH) are a combination of textual guidance, educational information and reporting proformas. The datasets enable pathologists to grade and stage cancers in an accurate, consistent manner in compliance with international standards and provide prognostic information thereby allowing clinicians to provide a high standard of care for patients and appropriate management for specific clinical circumstances. This guideline has been developed to cover most common circumstances. However, we recognise that guidelines cannot anticipate every pathological specimen type and clinical scenario. Occasional variation from the practice recommended in this guideline may therefore be required to report a specimen in a way that maximises benefit to the patient. Pathologists should be able to justify any variation.

Each dataset contains core data items (see Appendices C and D) that are mandated for inclusion in the Cancer Outcomes and Services Dataset (COSD) v9.0 in England. Core data items are those that are supported by robust published evidence and are required for cancer staging, optimal patient management and prognosis. Core data items meet the requirements of professional standards (as defined by the Information Standards Board for Health and Social Care [ISB]) and it is recommended that at least 95% of reports on cancer resections should record a full set of core data items. Other non-core data items are described. These may be included, with appropriate patient consent, to provide a comprehensive report or to meet local clinical or research requirements. All data items should be clearly defined to allow the unambiguous recording of data.

The following stakeholders were contacted to consult on this document:

- The British Society for Oral and Maxillofacial Pathology (BSOMP)
- The British Association of Head and Neck Oncologists (BAHNO)
- ENT-UK
- The British Association of Oral and Maxillofacial Surgeons
- The UK and Ireland Association of Cancer Registries
- National Cancer Registration and Analysis Service.

The information used by the authors to develop this dataset was obtained by undertaking a search of the PubMed database for relevant primary research evidence and systematic reviews on head and neck mucosal malignancies, either specifically in the larynx and hypopharynx or generally in the head and neck where these subsites can be separately identified, from January 2010 to June 2022 (inclusive). Key search terms searched included larynx, hypopharynx, clinical trial, prognosis, survival, surgery, chemotherapy and radiotherapy. The recommendations are in line with those of other national pathology organisations (College of American Pathologists, The Royal College of Pathologists of Australasia) and the [ENT-UK Consensus document for the management of patients with head and neck malignancies](#). They incorporate the core data items and commentary from the International Collaboration on Cancer Reporting (ICCR).<sup>1,2</sup> The level of evidence for the recommendations has been summarised according to modified SIGN guidance (see Appendix E) and the grade of evidence is indicated in the text. No major conflicts in the evidence have been identified and minor discrepancies between studies have been resolved by expert consensus. Gaps in the evidence were identified by College members via feedback received during consultation.

No major organisational changes or cost implications have been identified that would hinder the implementation of the dataset.

A formal revision cycle for all cancer datasets takes place on a three-yearly basis. However, each year, the College will ask the author of the dataset, in conjunction with the relevant sub-specialty adviser to the College, to consider whether or not the dataset needs to be updated or revised. A full consultation process will be undertaken if major revisions are required. Major revisions to core data

items, apart from changes to international tumour grading and staging schemes that have been approved by the Specialty Advisory Committee on Cellular Pathology and affiliated professional bodies. These changes will be implemented without further consultation). If minor revisions or changes to non-core data items are required, an abridged consultation process will be undertaken whereby a short note of the proposed changes will be placed on the College website for two weeks for members' attention. If members do not object to the changes, the short notice of change will be incorporated into the dataset and the full revised version (incorporating the changes) will replace the existing version on the College website.

The dataset has been reviewed by the Professional Guidelines team, Lay Network and Working Group on Cancer Services. It was placed on the College website for consultation with the membership from 20 April to 18 May 2023. All comments received from the Working Group and membership have been addressed by the authors to the satisfaction of the Chair of the Working Group and the Clinical Lead for Guideline Review.

This dataset was developed without external funding to the writing group. The College requires the authors of datasets to provide a list of potential conflicts of interest; these are monitored by the Professional Guidelines team and are available on request. The authors have declared that they have no conflicts of interest.

## 1 Introduction

The dataset has been developed for the reporting of biopsy and resection specimens of the larynx and hypopharynx. The protocol applies to all invasive carcinomas of the larynx and hypopharynx including: supraglottis, glottis, subglottis, piriform sinus, lateral and posterior hypopharyngeal wall and post cricoid region extending from the level of the arytenoid cartilage to the inferior border of the cricoid cartilage. This dataset does not apply to the reporting of lymphoma, malignant melanoma and sarcoma and relevant datasets for these tumour groups should be consulted where available. Nodal excisions and neck dissection specimens are dealt with in a separate dataset, *Dataset for the Histopathological Reporting of Nodal Excisions and Neck Dissection Specimens Associated with Head and Neck Carcinomas*, which should be used in conjunction, where applicable.<sup>3</sup>

The primary purpose of this document is twofold:

- to define the set of data necessary for the uniform recording and staging of the core pathological features in cancers of the larynx and hypopharynx
- to describe its application in sufficient detail and clarity that reports from different departments will contain equivalent information, allowing comparison of clinical practice and outcomes to ultimately improve patient care.

Optimal reporting of specimens from the head and neck area requires a partnership between the pathologist and surgeon/oncologist. The surgeon can help the pathologist to provide the information necessary for patient management by the appropriate handling and labelling of the specimen in the operating theatre. The regular discussion of cases at multidisciplinary team (MDT) (and other clinicopathological) meetings and correlation with pre-operative imaging studies are important in maintaining and developing this partnership and improving patient outcomes.

The core pathological data are summarised as proformas that may be used as the main reporting format or may be combined with free text as required. The core data does not differ between larynx and hypopharynx and therefore a common proforma for these primary sites, in keeping with the ICCR dataset, has been employed. The lymph node dataset is common to all head and neck sites. Individual centres may wish to expand the detail in some sections, e.g. for sites and subsites, to facilitate the recording of data for particular tumour types.

The guidelines within this dataset should be implemented for the following reasons:

- certain features of invasive mucosal carcinomas (type, size and grade of the primary carcinoma, the anatomical extent of invasion and proximity of carcinoma to resection margins) have been shown to be related to clinical outcome<sup>1,2</sup>
  - these features may therefore be important in: deciding on the most appropriate treatment for particular patients, including the extent of surgery and the use and choice of adjuvant radiotherapy, chemotherapy or targeted therapies;<sup>1,2</sup> monitoring changing patterns of disease, particularly by cancer registries
  - these features provide sufficiently accurate pathological information that can be used, together with clinical data, for the patient to be given a prognosis
- to allow correlation of resection specimens with preoperative imaging
- to allow the accurate and equitable comparison of surgeons in different surgical units
- to identify good surgical and pathological practice
- to allow selection and comparison of patients in clinical trials.

## 1.1 Design of this protocol

RCPATH recognises the authority of internationally accepted guidance documents (WHO, American Joint Committee for Cancer [AJCC], Union for Cancer Control [UICC] TNM and ICCR)<sup>1,2,4-6</sup> and promotes consistent reporting practice while adopting the recommendations of these organisations. This structured reporting protocol has been developed using the framework and data items specified in the ICCR dataset on cancers of the larynx, hypopharynx & trachea (published in 2018).<sup>1</sup> This protocol includes all the ICCR cancer dataset elements as well as additional information, elements and commentary. Core references have been updated to include relevant new information from 2018 to October 2021.

ICCR dataset elements for these cancers have been included verbatim and are indicated by the blue ICCR logo. ICCR core elements are mandatory, form part of the COSD data and are therefore represented as standards in this document. ICCR (and RCPATH) non-core elements are recommended and may be included as guidelines or used routinely according to local practice.

## 1.2 Target users and health benefits of this guideline

The dataset is primarily intended for the use of consultant and trainee pathologists when reporting biopsies and resection specimens of mucosal malignancies of the head and neck region and has been developed to aid a consistent approach to the reporting of these cancers. Surgeons and oncologists may refer to the dataset when interpreting histopathology reports and core data should be available at MDT meetings to inform discussions on the management of head and neck cancer patients. The core data items are incorporated into the COSD data and are collected for epidemiological analysis by Cancer Registries on behalf of the National Cancer Intelligence Network.

## 2 Clinical information required for the diagnosis of carcinomas of the larynx and hypopharynx

The request form should include patient demographic data, which includes:

- name
- date of birth

- sex
- hospital and NHS number (where appropriate) or other patient identification number.

Clinical information should include:

- duration of symptoms
- details of surgery and whether the intent is curative or palliative
- details of previous pathology reports
- core clinical data items (see section 5)
- Clinical TNM stage (for correlation with pathological findings).
- history of previous biopsy, resection, radiotherapy or chemotherapy as this may influence the interpretation of histological changes and should prompt a comment on the extent of any response to treatment.

The request form should provide the opportunity for surgeons to provide annotated diagrams of specimens, either as freehand drawings or on standard diagrams. Copies of reports that are sent to the Cancer Registries should include the patient's address if possible.

The following should also be recorded:

- name of the clinician requesting the investigation
- date and time of the operation
- date and time of fixation
- date and time of specimen receipt by the laboratory.

### **3 Receipt and preparation of specimens before dissection**

Resection specimens should be orientated by the surgeon and may be pinned or sutured to an appropriate mount (e.g. cork board, polystyrene block, foam sponge, KliniTray™). The surgeon may send annotated photographs of the resection specimen to aid the pathologist with orientation. The surgeon should indicate surgically critical margins using metal tags, sutures or ink. The surgeon should state clearly on the request form if ink has been used as this may fade during the fixation process. Fixation is in neutral buffered formalin for 24–48 hours in a container of adequate size. Resection specimens identified as a biohazard risk should be fixed for at least 48 hours (e.g. HIV, tuberculosis). If tissue is sent fresh from theatres, this should reach the pathology laboratory promptly. Refer to the [COVID-19 Resources Hub](#) for the latest COVID-19 related guidance.

Photography and radiography of the specimen may be used to record the extent of the disease and the sites from which tissue blocks are selected. Surgical margins should be painted with Indian ink or an appropriate dye to facilitate the later recording of the proximity of carcinoma to the margin. Identifying laterality (left and right) with two different coloured inks is advised, particularly if mega blocks are to be employed.

## 4 Specimen handling and block selection

### 4.1 Introduction

The specimen handling and preparation protocol described below is based on contemporary practice and should be regarded as a guide only; it may need to be modified in individual cases. A detailed dissection protocol is beyond the scope of these guidelines, but a brief summary of dissection methods and block selection is included to facilitate recording of the core data items. More detail can be found in the relevant sections of the RCPATH document *Tissue Pathways for Head and Neck Pathology*.<sup>7</sup> It is particularly important to record the macroscopic dimensions of the tumour, the closest margins and any gross invasion of laryngeal cartilage.<sup>8,9</sup>

It is important to identify if the patient has been enrolled in clinical trials prior to engaging in a trimming procedure as the clinical trial protocol may dictate specific requirements with regards to sampling.

The following commentary is intended to assist pathologists to understand the complex anatomy of the larynx and related structures.<sup>1</sup>

The supraglottis includes the epiglottis, aryepiglottic fold (laryngeal aspect), arytenoid, ventricular bands (false cords) and laryngeal ventricles.

The glottis extends from the ventricle to approximately 1 cm below the free level of the true vocal cord and includes the vocal cords, anterior commissure and posterior commissure.

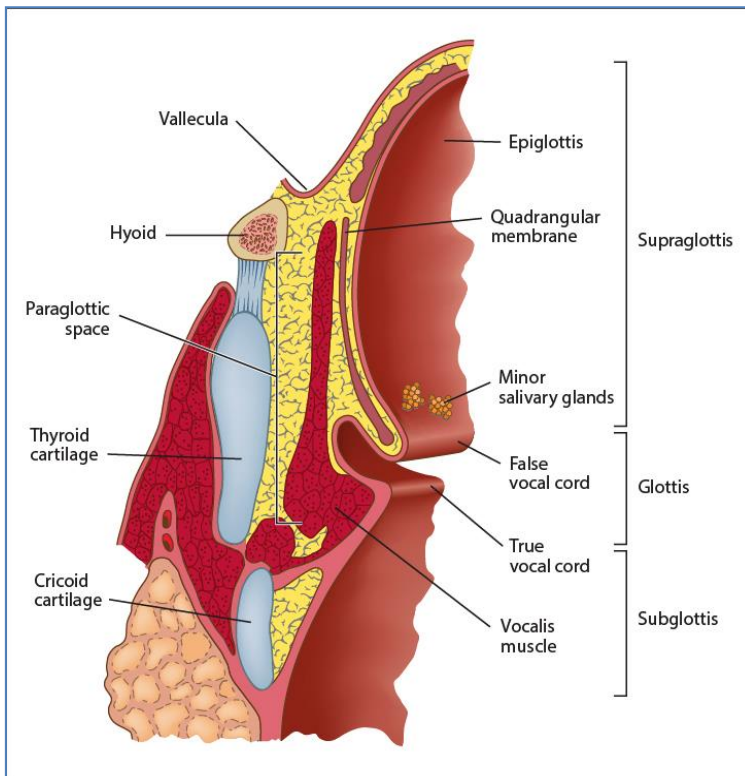
The subglottis extends from approximately 1 cm below the level of the true vocal cord to the inferior rim of the cricoid cartilage.

Note that transglottic carcinomas cross the ventricles in a vertical direction arising in either the glottis and/or supraglottic larynx.

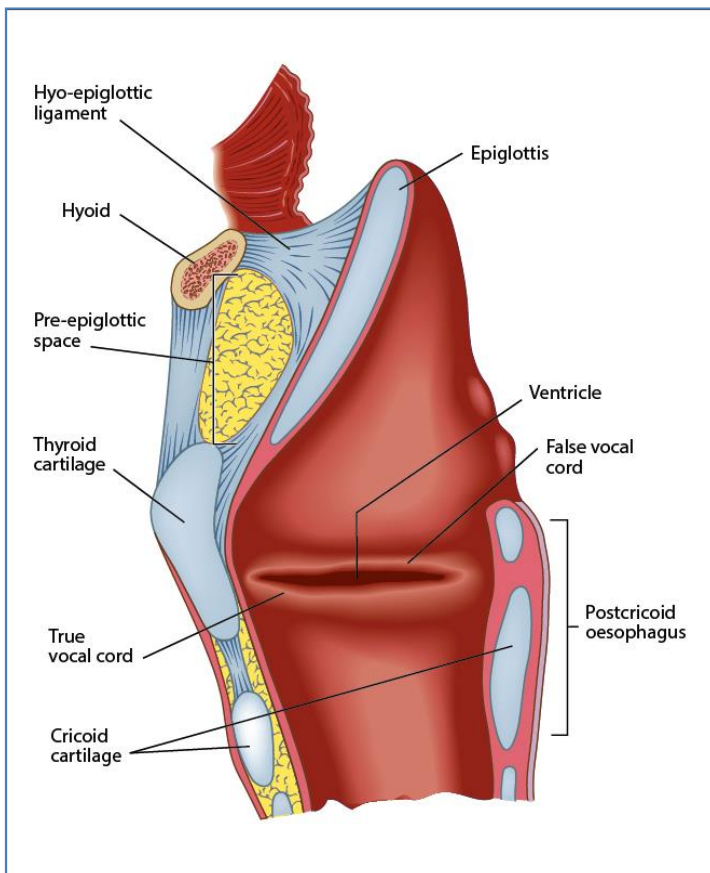
The hypopharynx is the part of the pharynx extending from the plane of the superior border of the hyoid bone (or floor of the vallecula) to the plane corresponding to the lower border of the cricoid cartilage. The contents of the hypopharynx include left and right piriform sinuses which expand bilaterally and forward around the sides of the larynx and lie between the larynx and the thyroid cartilage; the lateral and posterior hypopharyngeal walls and postcricoid region extend from the level of the arytenoid cartilages to the inferior border of the cricoid cartilage.

The paraglottic space is a fat-containing space antero-lateral and deep to the ventricles and saccules and filled with adipose tissue and connective tissue (see Figure 1); it is bounded by the conus elasticus inferiorly, the thyroid cartilage laterally, the quadrangular membrane medially and the piriform sinus posteriorly.

The pre-epiglottic space is anterior to the base of the epiglottis and is filled with adipose tissue and connective tissue (see Figure 2); it is triangular and is bounded by the thyroid cartilage and thyrohyoid membrane anteriorly, the epiglottis and thyroepiglottic ligament posteriorly and the hyoepiglottic ligament at its base.



**Figure 1.** Coronal section through the larynx to show the main structures and paraglottic space. © 2023 International Collaboration on Cancer Reporting Limited (ICCR).



**Figure 2.** Sagittal section through the larynx to show main structures and the pre-epiglottic space. © 2023 International Collaboration on Cancer Reporting Limited (ICCR).



## 4.2 Laryngectomy and pharyngolaryngectomy specimens

Horizontal slices 3–5 mm thick provide optimal demonstration of the relationship between the tumour and the laryngeal cartilages and other relevant anatomical spaces, although thicker slices may be required if megablocks are used. For supraglottic carcinomas, blocks should include the relationship between the carcinoma and the anterior (submucosal) resection margin at the base of the tongue; blocks taken in the sagittal plane are more appropriate to demonstrate this feature. The description should include the principle site of origin of carcinoma (including any subsites), the extent of involvement of laryngeal cartilages and extra-laryngeal tissues as well as the maximum tumour diameter.<sup>7–10</sup> In the case of a large tumour involving all anatomical subsites of the larynx, it is appropriate to describe the primary site as transglottic. Partial laryngectomy may be performed for smaller tumours and trimming procedures for these specimens should follow the same principle as larger resections.

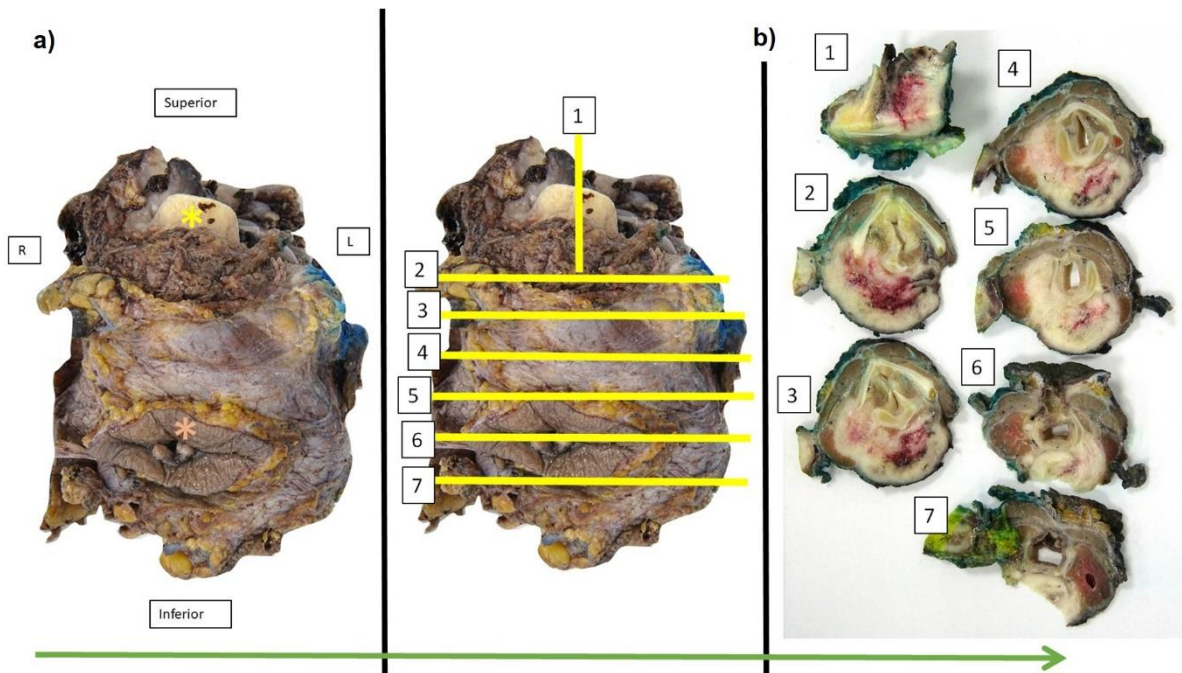
## 4.3 Selection of blocks for histology of laryngectomy and pharyngolaryngectomy specimens

- One specified tumour block for molecular testing, in which tumour content should be formally assessed.
- Tumour: at least one block per 10 mm diameter of tumour, including one selected to demonstrate the deepest involved tissue plane. The whole tumour should be processed if it is less than 10 mm in size. Megablocks are useful for demonstrating the relationship of tumour with important structures for staging. While they reduce the number of blocks taken it should be noted that the technical complexity for biomedical scientists is high and laboratories may have limited capacity for the processing of megablocks. Taking blocks of fixed tumour prior to decalcification is advised to ensure there is optimum quality tissue for immunohistochemistry and molecular testing if required.
- Blocks should include defined mucosal and soft tissue margins.
- Non-neoplastic mucosa (one block).
- Bone or cartilage if grossly involved by tumour.
- Thyroid if present in laryngectomy. One block is sufficient if the thyroid appears normal. If the thyroid is abnormal, one or more blocks should be taken to confirm or exclude invasion by carcinoma or other pathology.
- Tracheostomy site, if present.

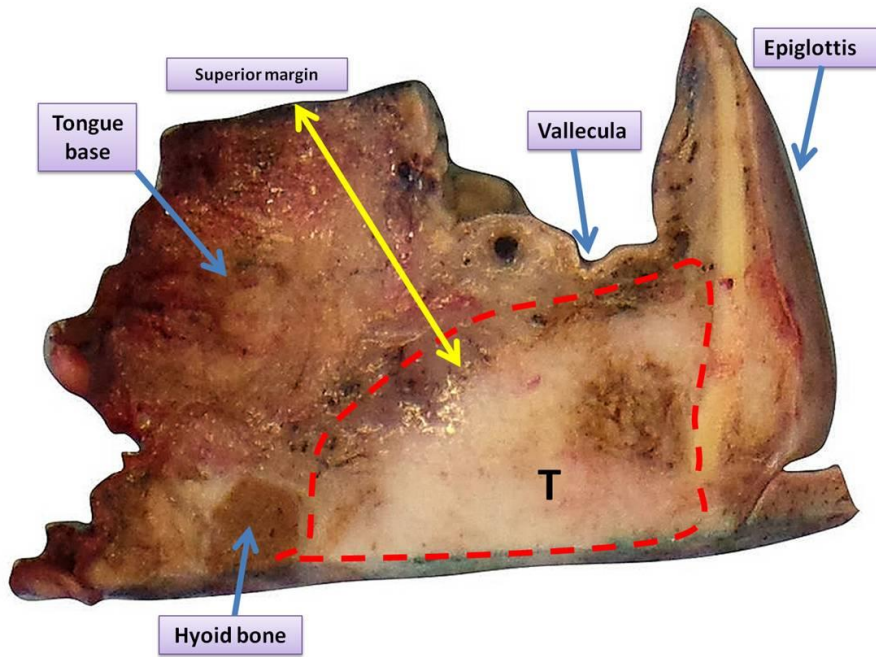
A methodical text-based block key, and/or photographic record of blocks taken should be included either as a print-out or on the laboratory macroscopic photograph archive folder.

Examples of cut up procedures and sampling of key margins and anatomical features are given in Figures 3–7.

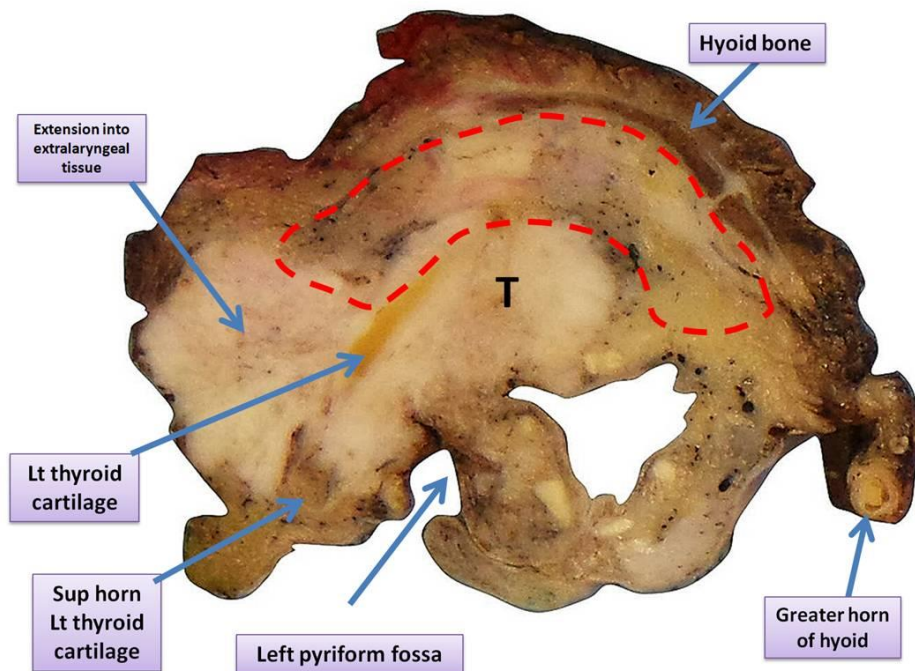
*[Level of evidence – GPP.]*



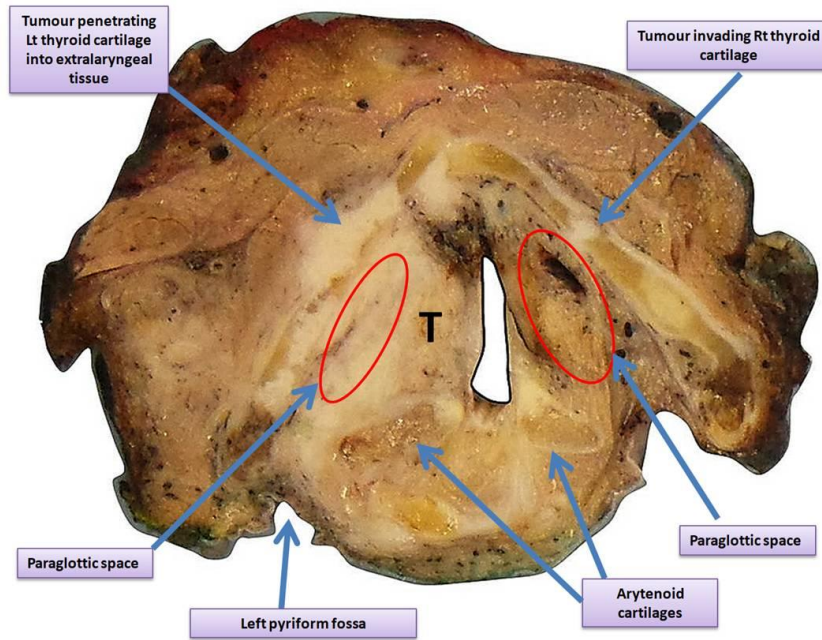
**Figure 3.** Sampling of laryngopharyngectomy specimen. **3a.** Specimen viewed from the anterior aspect. Epiglottis (yellow star) and tracheostomy site including skin (orange star) are highlighted. **3b.** In this example, the specimen has been sectioned on band saw prior to decalcification in the planes shown in yellow. The resultant slices are seen on the right. If preferred, the specimen can be sectioned on the bench following a period of decalcification in exactly the same planes. Prior to decalcification, it would be prudent to select a block of fixed tumour for embedding prior to decalcification in anticipation of potential immunohistochemistry or molecular testing. The epiglottis is sampled in sagittal plane (slice 1) which allows optimum assessment of the pre-epiglottic space invasion and tongue base margin at the superior aspect of the specimen. Slices 2–7 are taken in transverse plane. The supraglottis corresponds to slice 2. The vocal cords (glottis) are seen in slice 3 and the subglottis corresponds to slices 4–7. The left lobe of thyroid is seen in slices 4–7. The right lobe of thyroid is seen in slices 5–7. In slice 7, the trachea is seen. A more detailed account of the anatomy of each particular laryngeal subsite is given in Figures 4–7. The specimen shows a large hypopharyngeal tumour present in all slices. The tumour is midline/bilateral appears to extend in continuity with the inked posterior specimen limit. Blocks should be selected to determine all core dataset items in particular extent of invasiveness of key anatomical structures and margins. In this example interpretation of the posterior specimen limit is challenging as the surgical ability to resect normal tissue beyond the tumour is hindered by prevertebral fascia.



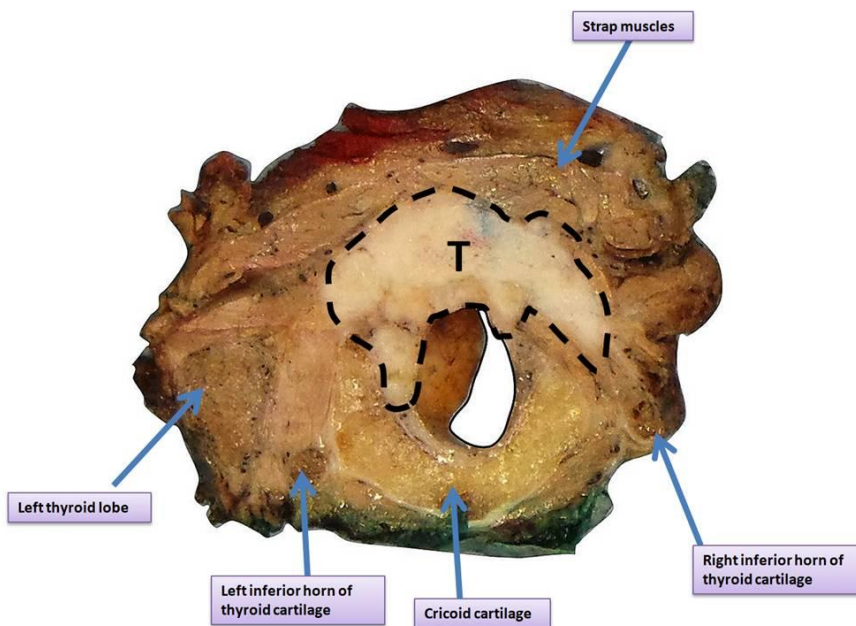
**Figure 4.** Epiglottis, pre-epiglottic space: key anatomical features. Sagittal section through epiglottis at superior aspect of a laryngopharyngectomy specimen. The pre-epiglottic space (red dashed line) shows invasion by squamous cell carcinoma (T). The yellow arrow demonstrates the nearest superior margin from tumour to the inked tongue base. Epiglottis, hyoid bone, vallecula and tongue base are shown.



**Figure 5.** Supraglottis: key anatomical features. Transverse section through the supraglottis of the same specimen. Tumour takes origin from the left pyriform fossa and shows extensive spread into extralaryngeal soft tissue including strap muscle on the left side. The pre-epiglottic space is outlined in red. Tumour is seen infiltrating beyond the left thyroid cartilage. Laryngeal tumours showing extension into extralaryngeal tissues beyond the thyroid cartilage are considered at least pT4a on TNM8 (UICC).



**Figure 6.** Glottis: key anatomical features. Transverse section through the glottis of the same specimen. There is anatomical distortion with the laryngeal lumen deviated to the right due to extensive tumour mass affecting the left side of the larynx. There is full thickness penetration of the left thyroid cartilage lamina with extension into extralaryngeal soft tissue. The right thyroid cartilage also shows invasion although the external lamina is intact. Both arytenoids are involved by tumour. The left and right paraglottic spaces are highlighted in red.



**Figure 7.** Subglottis: key anatomical features. Transverse section through the subglottis of laryngopharyngectomy specimen. Anteriorly placed tumour mass extends into strap muscles. Cricoid cartilage, left and right inferior horns of thyroid cartilage and left thyroid lobe are also included.

#### 4.4 Trans-oral laser resection specimens

The handling of trans-oral laser resection specimens requires particularly close collaboration between surgeon and pathologist. The main tumour resection may be in one or more parts and it is usual for separate biopsies from resection margins to be submitted for examination. The specimens should be pinned onto a board so that the anatomical relationships between the pieces are maintained and an annotated diagram should indicate the nature of each piece of tissue. The radial and deep margins should be inked to facilitate assessment of the histological sections.

The main tumour should be serially sliced and blocked in its entirety. If possible, biopsies from resection margins should be sliced perpendicular to the margin and blocked in their entirety. Small biopsies of the vocal cord are often difficult to orientate and may be pinned onto cork board or affixed to strips of dehydrated cucumber<sup>11</sup> to facilitate handling in the laboratory.


Small excisions may be received in biopsy cassettes sandwiched between small squares of sponge – this technique helps prevent tissue distortion during fixation and keeps specimens flat for easier sectioning. The biopsy cassette technique requires especially close communication between surgeon and pathologist to ensure orientation is preserved.


*[Level of evidence – GPP.]*

### 5 Data items

We have set out to use the ICCR dataset in its current form with appropriate qualifications and clarifications for implementation in UK clinical practice. In addition to the main dataset items, as outlined below, demographic and clinical data should be collected as per the ICCR dataset. This includes the patient's name, date of birth, sex, hospital and NHS number (where appropriate) or other patient identification number.

#### 5.1 Core data

1	Descriptor	Core/Non-core	Responses
	Operative procedure	Core	Biopsy Resection Other Not specified
	<p><b>Operative procedure commentary:</b> The nature of the operative procedure will influence the required level of detail in the pathological report. Diagnostic/incisional biopsies will usually generate a limited set of data items compared to excision/resection specimens: for example, the status of resection margins does not require detailed consideration for diagnostic biopsies except for very small carcinomas where the entire cancer may be present in the diagnostic specimen.</p> <p><b>RCPATH additional comments:</b> If a neck dissection specimen is submitted, please use the separate RCPATH dataset: <i>Dataset for Histopathology Reporting of Nodal Excisions and Neck Dissection Specimens Associated with Head and Neck Carcinomas</i>.<sup>3</sup></p> <p><i>[Level of evidence C – The basis in evidence for inclusion is well-conducted case-control or cohort studies.]</i></p>		


2	Descriptor	Core/Non-core	Responses
	Specimens submitted	Core	Hypopharynx Laryngopharyngectomy Other, specify Larynx Endolaryngeal excision Transoral laser excision Supraglottic laryngectomy Supracricoid laryngectomy Total laryngectomy Vertical hemilaryngectomy, specify side Partial laryngectomy, specify type Other, specify Not specified*

**Specimens submitted commentary:** The pathologist needs to be informed about the nature of surgery (type of specimen) so that their description and dissection are focused on selecting appropriate tissues to guide accurate cancer staging.<sup>7-10</sup>

\*'Not specified' should be used rarely and only after good effort has been employed to obtain the requisite information.

**RCPATH additional comments:** None.

*[Level of evidence C – The basis in evidence for inclusion is well-conducted case-control or cohort studies.]*


3	Descriptor	Core/Non-core	Responses
	Specimen dimensions	Core	Maximum dimension__ mm

**Specimen dimensions:** The size of a resection specimen is useful as it places the size of the tumour into the operative context. In those rare instances where specimens may be mislabelled, the size of the tissue may help to resolve any discrepancies.

**RCPATH additional comments:**

It is sufficient to record the maximum specimen dimensions in the macroscopic description only. Additional specimen dimensions (in mm) may be recorded as a non-core item.

*[Level of evidence D – The basis in evidence for inclusion is expert opinion.]*

4	Descriptor	Core/Non-core	Responses
	Tumour site	Core	Cannot be assessed No macroscopically visible tumour OR Hypopharynx Piriform sinus Postcricoid Pharyngeal wall (posterior and/or lateral) Larynx, supraglottis Epiglottis

			Lingual aspect Laryngeal aspect Aryepiglottic fold Arytenoid False vocal cord/fold Ventricle Larynx, glottis True vocal cord/fold Anterior commissure Posterior commissure Larynx, subglottis Left Right Midline Laterality not specified Other, specify
	Tumour laterality	Core	Left Right Bilateral/midline


**Tumour site comments:**

Accurate documentation of the laterality and site of the tumour avoids errors in the delivery of therapy. The site of the primary tumour is a key determinant in clinicopathological staging systems for hypopharynx and larynx.

For carcinomas that involve more than one site, the principal site of involvement should be recorded and coded; this may not be the site of origin. If required, the involvement of associated sites can be noted to help in later data analysis. Sites and subsites should be recorded according to the Union for International Cancer Control (UICC) nomenclature.<sup>5</sup>

**RCPATH additional comments:** None.

*[Level of evidence C – The basis in evidence for inclusion is well-conducted case-control or cohort studies.]*

5	Descriptor	Core/Non-core	Responses
	Tumour dimensions	Core	Maximum tumour dimension (largest tumour) ___ mm


**Tumour dimensions comments:**

The macroscopic diameter (in millimetres) should be used unless the histological extent is greater than macroscopically apparent, in which case the microscopic dimension is used. As for other tissues, measurements are made pragmatically, acknowledging distortion of tissues by fixation and processing.<sup>5,6,12–14</sup>

For larynx, several sites rely on the presence or absence of vocal cord mobility to determine T stage; in these circumstances, only a provisional pT stage can be offered (at least pT1a, for example).

**RCPATH additional comments:** Additional tumour dimensions (in mm) may be recorded as a non-core item.

[Level of evidence C – The basis in evidence for inclusion is well-conducted case-control or cohort studies.]

6	Descriptor	Core/Non-core	Responses
	Histological tumour type	Core	Squamous cell carcinoma, conventional type Squamous cell carcinoma, variant types Adenosquamous carcinoma Basaloid squamous cell carcinoma Papillary squamous cell carcinoma Spindle cell squamous cell carcinoma Verrucous squamous cell carcinoma Lymphoepithelial carcinoma Neuroendocrine carcinoma Well differentiated neuroendocrine carcinoma Moderately differentiated neuroendocrine carcinoma Poorly differentiated neuroendocrine carcinoma Small cell neuroendocrine carcinoma Large cell neuroendocrine carcinoma Combined (or composite) neuroendocrine carcinoma, with squamous or adenosquamous component Carcinomas of minor salivary glands Adenoid cystic carcinoma, specify grade Mucoepidermoid carcinoma, specify grade Other, specify

**Histological tumour type comments:**

Histopathological type is important for cancer registration and prognosis, with strength of evidence varying for different types. Verrucous and papillary carcinomas tend to have a good prognosis while adenosquamous carcinomas have a worse prognosis than conventional and spindle cell carcinomas. For most of the variants of squamous cell carcinoma, surgery with adequate margins is the main treatment. In some tumours, such as large cell neuroendocrine carcinomas, a combination of irradiation and chemotherapy is indicated.


All tumours of the hypopharynx, larynx and trachea should be typed based on the most recent edition of the World Health Organization (WHO) Classification of Head and Neck Tumours.<sup>4,15-24</sup>

**RCPATH additional comments:**


For mucosal melanoma, please refer to the current ICCR dataset.<sup>25</sup> It is envisaged that an RCPATH dataset will follow in due course.

[Level of evidence C – The basis in evidence for inclusion is well-conducted case-control or cohort studies.]



7	Descriptor	Core/Non-core	Responses
	Histological tumour grade	Core	Not applicable GX: Cannot be assessed G1: Well differentiated G2: Moderately differentiated G3: Poorly differentiated Other, specify
<p><b>Histological grade comments:</b></p> <p>Although human papillomavirus (HPV)-associated carcinomas arising in the oropharynx are graded differently from conventional (non-HPV) carcinomas (see ICCR <i>Carcinomas of the nasopharynx and oropharynx</i> dataset),<sup>26</sup> there is insufficient evidence to justify this approach in the hypopharynx and larynx. The recommendation is that HPV assessment should not be performed except for basaloid carcinomas. The conventional grading system for classical squamous cell carcinomas should be used for all tumours at these sites.</p> <p>Grading is based on the degree of resemblance of the carcinoma to the normal epithelium and follows the descriptions in the WHO classification.<sup>4</sup> The most aggressive area is graded as well, moderately or poorly differentiated. This system is widely used and prognostically useful, even though it suffers from inter-observer variability and sampling problems. While most squamous cell carcinomas will be moderately differentiated, it is important for prognostication to separate tumours based on differentiation. Where a tumour has a varied appearance, then the highest grade (poorest differentiation) is recorded as a core data item, while the predominant pattern may be recorded as non-core data.</p> <p>Squamous cell carcinoma variants (basaloid, adenosquamous, spindle cell) are considered to have intrinsic biological potential and are not graded.</p> <p>For the grading of salivary-type tumour arising from mucosal glands, please refer to the ICCR <i>Carcinomas of the major salivary glands</i> dataset for descriptors.<sup>27</sup></p> <p><b>RCPATH additional comments:</b> Grading is based on the degree of resemblance of the carcinoma to the normal epithelium and follows the descriptions in the WHO classification.<sup>4</sup> The most aggressive area (at x100 magnification field) is graded as well, moderately or poorly differentiated. This system is widely used and prognostically useful although it suffers from inter-observer variability, sampling problems and does not always correspond to prognosis.<sup>1,24,27-29</sup> While most squamous cell carcinomas will be moderately differentiated, it is important for prognostication to separate well-differentiated and poorly differentiated tumours. Where a tumour has a varied appearance, then the highest grade (poorest differentiation) is recorded as a core data item, while the predominant pattern may be recorded as non-core data.<sup>30-35</sup></p> <p>Although human papillomavirus (HPV)-associated carcinomas arising in the oropharynx are graded differently from conventional (non-HPV) carcinomas there is insufficient evidence to justify this approach in the hypopharynx and larynx. The recommendation is that HPV assessment should not be performed except for basaloid carcinomas, particularly in the upper hypopharynx in which the disease may represent regional extension of an oropharyngeal primary.<sup>36-39</sup></p> <p>Squamous cell carcinoma variants (basaloid, adenosquamous, spindle cell) are considered to have intrinsic biological potential and are not graded.<sup>40,41</sup></p> <p>For the grading of salivary-type tumour arising from mucosal glands, please refer to the ICCR <i>Carcinomas of the major salivary glands</i> dataset<sup>27</sup> for descriptors.</p>			

[Level of evidence C – The basis in evidence for inclusion is well-conducted case-control or cohort studies.]

8	Descriptor	Core/Non-core	Responses
	Extent of invasion	Core	Not identified OR Involves mucosa Involves paraglottic space Involves pre-epiglottic space Partial thickness invasion of cartilage Full thickness invasion of cartilage


**Extent of invasion comments:**

In the larynx, the invasion of tissue compartments deep to the mucosa is important for staging. The important tissues for staging purposes are the paraglottic space, the pre-epiglottic space and the thyroid and cricoid cartilages. One of the points of distinction between T3 and T4a carcinomas is whether cartilage invasion is minor (partial) or full thickness. The absolute tumour thickness is non-core for larynx and hypopharynx.

**RCPATH additional comments:**

Knowledge of the radiological staging and judicious macroscopic sampling of key structures may aid determination of the greatest extent of microscopic invasion for a given case. The extent of invasion of the thyroid/cricoid cartilages (inner table only, or full thickness) should be recorded.<sup>1,5,6,43–48</sup> Infiltration of the arytenoid and/or epiglottic cartilage does not influence the T stage. If desired, tumour thickness may be recorded as a non-core data.<sup>49–51</sup>

[Level of evidence C – The basis in evidence for inclusion is well-conducted case-control or cohort studies.]

9	Descriptor	Core/Non-core	Responses
	Perineural invasion	Core	Not identified Present Cannot be assessed


**Perineural invasion comments:**

The presence or absence of perineural invasion should be recorded, regardless of the size of the nerve.<sup>52–64</sup> Invasion of the perineural plane is a predictor of local recurrence and nodal metastasis and may prompt consideration of adjuvant chemoradiotherapy.

The perineural plane is a potential space between the bundles of axons and the perineurium; the presence of carcinoma around a nerve (external to the perineurium) is not regarded as perineural invasion. There is some evidence that extratumoural perineural invasion is of more importance than intratumoural perineural invasion but this requires confirmation. For this dataset, either intratumoural or extratumoural invasion is regarded as a positive finding.

**RCPATH additional comments:** Quantitative assessment of perineural invasion (particularly the size of affected nerve), as recommended in other RCPATH datasets, is not routine practice in reporting of head and neck cancer.

[Level of evidence C/D – The basis in evidence for inclusion is case-control or cohort studies.]


10	Descriptor	Core/Non-core	Responses
	Lymphovascular invasion	Core	Not identified Present Cannot be assessed

**Lymphovascular invasion comments:**

Lymphovascular invasion is a relatively weak predictor of nodal metastasis.<sup>65,66</sup> The presence of carcinoma cells within an endothelial-lined space is the essential criterion and should be distinguished from retraction artefact. It is not necessary to distinguish between small lymphatics and venous channels.

**RCPATH additional comments:** While it is important to distinguish between small lymphatics and venous channels in tumours in RCPATH datasets relating to different body systems, it is not necessary to differentiate between vessel types in tumours of the larynx and hypopharynx.

*[Level of evidence C – The basis in evidence for inclusion is well-conducted case-control or cohort studies.]*

11	Descriptor	Core/Non-core	Responses
	Margin status: invasive carcinoma	Core	Involved – Specify margin(s), if possible Not involved Distance from closest margin ___ mm Distance not assessable Specify closest margin, if possible
	Margin status: in situ carcinoma/High grade dysplasia	Core	Involved – Specify margin(s), if possible Not involved Distance from closest margin ___ mm Distance not assessable Specify closest margin, if possible Not applicable Cannot be assessed

**Margin status comments:** Margin status is a predictor of local recurrence and may require consideration of adjuvant therapy.<sup>67-79</sup> The status of the surgical resection margin should include assessment of both invasive and in situ carcinoma.

A positive margin is one in which the carcinoma is present at the margin while the definition of a 'close margin' varies between published series, typically being regarded as between 3 and 5 mm. For laser resections of glottic carcinomas even 1 mm may be adequate due to the thermal damage of tissue at the margin. It is recommended that the distance from in situ or invasive carcinoma to the closest margin is recorded, if assessable. Note that comment on the deep resection margin of a laryngectomy specimen may be inapplicable unless the tumour extends close to the base of tongue or into the soft tissues of the neck.<sup>80</sup>

**RCPATH additional comments:** Interpretation of the posterior surgical margin in the hypopharynx can be challenging since the true anatomical posterior margin may comprise pre-vertebral fascia thus rendering further surgical excision (or margin revision) impossible. Similarly, interpretation of the posterior margin of laryngectomy specimens can also be complicated particularly in large glottic tumours. Interpretation requires an appropriate level of anatomical knowledge as well correlation with pre-operative radiological images by the pathologist. Close communication between the surgical team and the pathologist would also be advisable. In such instances, it may be more appropriate to refer to the 'posterior specimen limit' rather than the posterior margin.

An alternative method for recording the margin status is to use the UICC Residual Tumour (R) Classification:<sup>5</sup>


- RX Presence of residual tumour cannot be assessed
- R0 No residual tumour
- R1 Microscopic residual tumour
- R2 Macroscopic residual tumour.


Whichever system is used, it should be by local agreement, with the surgical and pathology teams clear as to interpretation.

On occasion, additional descriptive comments on the margins will be required, for example where the tumour is 0 mm from the margin in the main specimen, but additional margin biopsies are clear.


*[Level of evidence C – The basis in evidence for inclusion is well-conducted case-control or cohort studies.]*

## 5.2 Non-core data items

1	Descriptor	Core/Non-core	Responses
	Neoadjuvant therapy	Non-Core	Administered Not administered Not known
		Non-core	Type of neoadjuvant therapy
<p><b>Neoadjuvant therapy commentary:</b> Information from the surgeon about the use of neoadjuvant therapy will help the pathologist interpret correctly the histologic findings. While the extent of tumour necrosis or post-therapy fibrosis are not currently used as an important guide to management for most types of laryngeal/hypopharyngeal cancer, it is good practice to document the effects of previous treatment as part of a free text report. Pragmatically, an estimate of the amount (% tumour volume) of necrosis or fibrosis can be provided as free text.</p> <p><b>RCPATH additional comments:</b> None.</p> <p><i>[Level of evidence C – The basis in evidence for inclusion is well-conducted case-control or cohort studies.]</i></p>			

2	Descriptor	Core/Non-core	Responses
	Tumour focality	Non-core	Unifocal Bilateral Multifocal, specify number of tumours in specimen Cannot be assessed, specify
<p><b>Tumour focality comments:</b> Tumour focality is described as unifocal or multifocal to allow the pathologist to describe the complexity of the disease in some patients.<sup>2</sup></p> <p><b>RCPATH additional comments:</b> None.</p>			

[Level of evidence C – The basis in evidence for inclusion is well-conducted case-control or cohort studies.]


3	Descriptor	Core/Non-core	Responses
	Pattern of invasive front	Non-core	Cohesive Non-cohesive Difficult to determine

**Pattern of invasive front comments:**

The pattern of invasion by the carcinoma at its deep margin is of proven prognostic value for oral and oropharyngeal carcinomas (non-HPV-associated) and there is limited evidence that a similar approach may be of value to predict nodal metastasis for hypopharyngeal and laryngeal carcinomas. Note that the response for this data item is based on the most complex ('worst') area of the carcinoma. The pattern of invasion is included as a non-core data item as many head and neck pathologists include this in their personal descriptive assessment of carcinomas at all sites and it is convenient to use it for larynx and pharynx as well, for consistency with national dataset, even though this is not supported by robust evidence of clinical impact.

**RCPATH additional comments:** Pattern of invasion may be difficult to adequately assess in small laser resection specimens of limited depth. The 'difficult to determine' option should be reserved for such cases.<sup>81,82</sup>


[Level of evidence C – The basis in evidence for inclusion is well-conducted case-control or cohort studies.]

4	Descriptor	Core/Non-core	Responses
	Co-existent pathology	Non-core	None identified OR Necrotizing sialometaplasia Infection, specify Dysplasia, specify type and grade Hyperplasia, specify Other, specify

**Coexistent pathology comments:** This is a non-core data item to provide the pathologist with the flexibility to record any other diseases that potential impact on clinical management, such as infections, epithelial dysplasia, hyperplastic processes and necrotising sialometaplasia.

**RCPATH additional comments:** None.

[Level of evidence D – The basis in evidence for inclusion is expert opinion.]

5	Descriptor	Core/Non-core	Responses
	Ancillary studies	Non-core	Not performed Performed (specify)

**Ancillary studies comments:**

This is a non-core data item that is intended to allow pathologists to record the use of additional relevant investigations, in particular molecular testing, the prognostic and predictive significance of which is uncertain. A section of fixed tumour taken before decalcification processes is recommended to facilitate ancillary studies.

The literature recognises that a very few HPV associated carcinomas may occur in the hypopharynx and larynx, but prognostic relevance is uncertain.<sup>37-40</sup>

**RCPATH additional comments:** None.

*[Level of evidence C – The basis in evidence for inclusion is well-conducted case-control or cohort studies.]*

## 6 Diagnostic coding and staging

Pathological staging, using the most recent edition of the AJCC/UICC Classification of malignant tumours, is a core item for all cancers of the larynx and hypopharynx<sup>5,6</sup> (currently the 8th edition is employed).

By convention, the designation 'T' refers to a primary tumour that has not been previously treated. The symbol 'p' refers to the pathologic classification of the stage and, as opposed to the clinical classification, is based on gross and microscopic examination. pT entails a resection of the primary tumour adequate to evaluate the highest pT category, pN entails removal of nodes adequate to validate lymph node metastasis and pM implies microscopic examination of distant lesions. There is no pathologic M0 category as this designation requires clinical evaluation and imaging. Clinical classification (cTNM) is usually carried out by the referring physician before treatment during initial evaluation of the patient or when pathologic classification is not possible.

Pathological staging is usually performed after surgical resection of the primary tumour and depends on documentation of the anatomic extent of disease, whether or not the primary tumour has been completely removed. If a biopsied tumour is not resected for any reason (e.g. when technically unfeasible) and if the highest T and N categories or the M1 category of the tumour can be confirmed microscopically, then this is sufficient for recording the stage and classification.

For identification of special cases of TNM or pTNM classifications, 'y' and 'r' prefixes are used. Although they do not affect the stage grouping, they indicate cases needing separate analysis. The 'y' prefix indicates those cases in which classification is performed during or following initial multimodality therapy (i.e. neoadjuvant chemotherapy, radiation therapy, or both chemotherapy and radiation therapy). The cTNM or pTNM category is identified by a 'y' prefix. The ycTNM or ypTNM categorizes the extent of tumour actually present at the time of that examination. The 'y' categorization is not an estimate of tumour prior to multimodality therapy (i.e. before initiation of neoadjuvant therapy). The 'r' prefix indicates a recurrent tumour when staged after a documented disease-free interval and is identified by the 'r' prefix: rTNM.

*[Level of evidence C – The basis in evidence for inclusion is well-conducted case-control or cohort studies.]*

## 7 Reporting of small biopsy specimens

When a biopsy specimen is all that is received, elements specific to the biopsy should be reported and the remaining items that are applicable to surgically resected tumours omitted. The data that can be obtained from small biopsy specimens will be determined, in part, by their size. The type of carcinoma and its grade are the minimum data, as these may determine treatment. It is recognised that, in large tumours, the grade in superficial biopsy material may not be representative of the most aggressive part of the invasive front. If severe dysplasia is present, this should be recorded as it may influence the siting of excision margins. It is not

realistic to assess reliably the tumour thickness or presence of vascular invasion in small biopsies.

## 8 Frozen section diagnosis

The initial diagnosis of carcinoma will usually be made before definitive surgery is performed. On occasions, intra-operative frozen section diagnosis of the nature of a neoplasm will be required. While it is usually possible to identify the presence of neoplastic tissue, the nature of a poorly differentiated neoplasm may be impossible to determine on frozen sections. The assessment of the presence or absence of carcinoma at surgical resection margins is the most common indication for intra-operative frozen section diagnosis. The surgeon should select the tissue for frozen section diagnosis with care, bearing in mind that it is not usually possible to section material more than 10 mm in diameter. The report on the frozen section specimen(s) should normally form part of, or accompany, the final diagnostic report on the case.

## 9 Support of research and clinical trials

It is important to be aware of local protocols for tissue banking and engagement with national initiatives for the further classification of tumours, (such as was implemented in the [100,000 Genomes Project](#)). Other features, such as assessment of the effects of biological therapy/immunotherapy may be important but are currently beyond the remit of this dataset.

## 10 Specific aspects of individual tumours not covered elsewhere

Regarding PD-L1 testing, immunohistochemical assessment for PD-L1 expression can predict response to anti-PD-L1 immunotherapy, although this is variable and has certain limitations.<sup>83,84</sup> However, a number of different anti-PD-L1 clones are available from different manufacturers and the published trials have examined specific clones linked to the activity of specific anti-PD-L1 immunotherapy agents. Moreover, these tests use different algorithms and cut-offs to identify which patients are more likely to benefit from each immunotherapeutic agent.<sup>83</sup> Since PD-L1 testing is required only for some patients with advanced head and neck cancer and each immunotherapeutic agent needs a different PD-L1 test; reflex testing of all specimens is not recommended at present. However, individual departments should set up a process to enable prompt PD-L1 testing by a trained pathologist in an accredited laboratory for any patient requiring this test. Participation in relevant immunohistochemistry external quality assessment (EQA) is mandatory for laboratories involved in PD-L1 assessment. The results of such testing should be incorporated into the pathology report (including the antibody used) when it is available; such testing should not delay the primary report.

## 11 Criteria for audit

The key assurance indicators (see [Key assurance indicators for pathology services](#), November 2019) and key performance indicators (see [Key Performance Indicators – Proposals for implementation](#), July 2013) as recommended by RCPATH are:

- cancer resections should be reported using a template or proforma, including items listed in the English COSD, which are, by definition, core data items in RCPATH cancer datasets. English trusts were required to implement the structured recording of core pathology data in the COSD
  - standard: 95% of reports must contain structured data
- histopathology cases must be reported, confirmed and authorised within seven and ten calendar days of the procedure

- standard: 80% of cases must be reported within seven calendar days and 90% within ten calendar days.

**Further suggested audit standard:**

- The inclusion of SNOMED or SNOMED-CT codes:
  - standard: 95% reports should have T, M and P codes.
- The availability of pathology reports and data at MDT meetings:
  - standard: 90% of cases discussed at MDT meetings where biopsies or resections have been taken should have pathology reports/core data available for discussion
  - standard: 90% of cases where pathology has been reviewed for the MDT meeting should have the process of review recorded.



## 12 References

1. Helliwell T, Chernock R, Dahlstrom J, Gale N, McHugh J, Perez-Ordóñez B *et al.* *Carcinomas of the Hypopharynx, Larynx and Trachea, Histopathology Reporting Guide (1st edition)*. Sydney, Australia: International Collaboration on Cancer Reporting, 2018.
2. Helliwell T, Chernock R, Dahlstrom J, Gale N, McHugh J, Perez-Ordóñez B *et al.* Data set for the reporting of carcinomas of the hypopharynx, larynx, and trachea: Explanations and recommendations of the guidelines from the International Collaboration on Cancer Reporting. *Arch Pathol Lab Med* 2019;143:432–438.
3. The Royal College of Pathologists. *Dataset for Histopathology Reporting of Nodal Excisions and Neck Dissection Specimens Associated with Head and Neck Carcinomas*. London, UK: The Royal College of Pathologists, 2016. Accessed March 2022. Available at: [www.rcpath.org/uploads/assets/2babb476-472b-4008-997c6a1074fddb23/ataset-for-histopathology-reporting-of-nodal-excisions-and-neck-dissection-specimens-associated-with-head-and-neck-carcinomas.pdf](http://www.rcpath.org/uploads/assets/2babb476-472b-4008-997c6a1074fddb23/ataset-for-histopathology-reporting-of-nodal-excisions-and-neck-dissection-specimens-associated-with-head-and-neck-carcinomas.pdf)
4. El-Naggar A, Chan J, Grandis J, Takata T, Slootweg P. *WHO Classification of Head and Neck Tumours (4th edition)*. Lyon, France: International Agency for Research on Cancer, 2017.
5. Head and Neck Tumours: Pharynx & Larynx. *In: Brierley DJ, Gospodarowicz KM, Wittekind C (eds.) TNM Classification of Malignant Tumours (8th edition)*. New Jersey, US: Wiley-Blackwell, 2016.
6. Amin M, Edge S, Greene F, Byrd D, Brookland R, Washington M *et al.* *AJCC Cancer Staging Manual (8th edition)*. New York, USA: Springer, 2017.
7. The Royal College of Pathologists. *Tissue Pathways for Head and Neck Pathology*. London, UK: The Royal College of Pathologists, 2016. Accessed March 2022. Available at: [www.rcpath.org/uploads/assets/8f94d6b0-48d9-4ccc-93a966c705863e4c/g077-headnecktp-jan16.pdf](http://www.rcpath.org/uploads/assets/8f94d6b0-48d9-4ccc-93a966c705863e4c/g077-headnecktp-jan16.pdf)
8. Helliwell T. ACP Best Practice No 157. Guidelines for the laboratory handling of laryngectomy specimens. *J Clin Pathol* 2000;53:171–176.
9. Napier SS, Devlin B. Pharynx and Larynx. *In: Allen D, Cameron R (eds.) Histopathology Specimens. Clinical, Pathological and Laboratory Aspects. (3rd edition)*. Cham, Switzerland: Springer, 2018.
10. Royal College of Pathologists of Australasia (RCPA). *Macroscopic Cut-up Manual*. Accessed March 2022. Available from: [www.rcpa.edu.au/Manuals/Macroscopic-Cut-Up-Manual/Head-and-neck/Larynx](http://www.rcpa.edu.au/Manuals/Macroscopic-Cut-Up-Manual/Head-and-neck/Larynx)
11. Murray C, Cooper, Handa K, MacLeod T, MacKenzie K. A technique for the orientation of endoscopically resected laryngeal lesions. *Clin Otolaryngol* 2007;32:201–203.
12. Gong H, Zhou L, Hsueh C, Wu H, Tao L, Zhang M *et al.* Prognostic value of pathological tumor size in patients with supraglottic carcinoma. *Am J Otolaryngol* 2021;42:1:102757.
13. Helliwell T. ACP Best Practice No 169. Evidence based pathology: squamous carcinoma of the hypopharynx. *J Clin Pathol* 2003;56:81–85.
14. Jang J, Kim M, Ryu G, Choi N, Ko Y, Jeong H. Prediction of lymph node metastasis by tumor dimension versus tumor biological properties in head and neck squamous cell carcinomas. *Cancer Res Treat* 2016;48:54–62.

15. Wenig B. Squamous cell carcinoma of the upper aerodigestive tract: precursors and problematic variants. *Mod Pathol* 2002;15:229–254.
16. Chute D, Stelow E. Cytology of head and neck squamous cell carcinoma variants. *Diagn Cytopathol* 2010;38:65–80.
17. Lopez F, Williams M, Cardesa A, Hunt J, Strojan P, Rinaldo A *et al.* How phenotype guides management of non-conventional squamous cell carcinomas of the larynx? *Eur Arch Otorhinolaryngol* 2017;274:2709–2726.
18. Thompson L. Laryngeal dysplasia, squamous cell carcinoma, and variants. *Surg Pathol Clin* 2017;10:15–33.
19. Jumaily M, Faraji F, Zhang D, Walker R, Ward G. Basaloid squamous cell carcinoma of the larynx: A National Cancer Database analysis. *Otolaryngol Head Neck Surg* 2019;160: 847–854.
20. Chen L, Deng W, Li C, Lau H, Tao L, Wang S *et al.* Clinical outcome and comparison between squamous and non-squamous cell carcinoma of the larynx. *Acta Otolaryngol* 2020;140:195–201.
21. Chen L, Chen Q, Li C, Zhou L, Wang S, Zhang M. Clinical analysis of laryngeal spindle cell carcinoma. *ORL J Otorhinolaryngol Relat Spec* 2020;82:310–317.
22. Xie C, Liao J, Huang C, Wei F, Liu T, Wen W *et al.* Basaloid squamous cell carcinoma of the hypopharynx: an analysis of 213 cases. *Eur Arch Otorhinolaryngol* 2022;279:2099–2107.
23. Perez-Ordoñez B. Neuroendocrine carcinomas of the larynx and head and neck: Challenges in classification and grading. *Head Neck Pathol* 2018;12:1–8.
24. Gale N, Poljak M, Zidar N. Update from the 4th Edition of the World Health Organization Classification of Head and Neck Tumours: What is new in the 2017 WHO Blue Book for tumours of the hypopharynx, larynx, trachea and parapharyngeal space. *Head Neck Pathol* 2017;11:23–32.
25. Thompson LDR, Franchi A, Helliwell T, Müller S, Williams MD. *Mucosal Melanomas of the Head and Neck, Histopathology Reporting Guide (1st edition)*. Sydney, Australia: International Collaboration on Cancer Reporting, 2018.
26. Lewis JS Jr, Adelstein DJ, Agaimy A, Carlson D, Faquin WC, Helliwell T *et al.* *Carcinomas of the Nasopharynx and Oropharynx, Histopathology Reporting Guide, (1st edition)*. Sydney, Australia: International Collaboration on Cancer Reporting, 2018.
27. Seethala R, Altemani A, Ferris R, Fonseca I, Gnepp D, Ha P *et al.* *Carcinomas of the Major Salivary Glands, Histopathology Reporting Guide (1st edition)*. Sydney, Australia: International Collaboration on Cancer Reporting, 2018.
28. Geelen C, Hordijk G, Ravasz L, Terhaard C. Degree of tumour differentiation as a prognostic factor in advanced laryngeal cancer. *Acta Otorhinolaryngol Belg* 1995;49:1–4.
29. Anderson E, Luu M, Balzer LB, Scher K, Mita CA, Lu JD *et al.* Variations in the association of grade with survival across the head and neck cancer landscape. *Head Neck* 2021;43:1105–1115.

30. Wiernik G, Millard P, Haybittle J. The predictive value of histological classification into degrees of differentiation of squamous cell carcinoma of the larynx and hypopharynx compared with the survival of patients. *Histopathology* 1991;19:411–417.
31. Jakobsson P, Eneroth C, Killander D, Moberger G, Martensson B. Histologic classification, and grading of malignancy in carcinoma of the larynx. *Acta Radiol Ther Phys Biol* 1973;12:1–8.
32. Roland JN, Caslin A, Nash J, Stell P. Value of grading squamous cell carcinoma of the head and neck. *Head Neck* 1992;14:224–229.
33. Kearsley J, Thomas S. Prognostic markers in cancers of the head and neck region. *Anticancer Drugs* 1993;4:419–429.
34. Snow G, Annyas A, van Slooten E, Bartelink H, Hart A. Prognostic factors of neck node metastasis. *Clin Otolaryngol Allied Sci* 1982;7:185–192.
35. Henson D. The histological grading of neoplasms. *Arch Pathol Lab Med* 1988;112:1091–1096
36. Sethi S, Lu M, KA, BSM, Worsham JM. Patient and tumor factors at diagnosis in a multi-ethnic primary head and neck squamous cell carcinoma cohort. *J Surg Oncol* 2009;99:104–108.
37. Torrente M, Rodrigo J, Haigentz M JR, Dikkers GF, Rinaldo A, Takes PR *et al.* Human papillomavirus infections in laryngeal cancer. *Head Neck* 2011;33:581–586.
38. Rooper L, Windon M, Hernandez T, Miles B, Ha P, Ryan W *et al.* HPV-positive squamous cell carcinoma of the larynx, oral cavity, and hypopharynx: Clinicopathologic characterization with recognition of a novel warty variant. *Am J Surg Pathol* 2020;44:691–702.
39. Erkul E, Yilmaz I, Narli G, Babayigit M, Gungor A, Demirel D. The presence and prognostic significance of human papillomavirus in squamous cell carcinoma of the larynx. *Eur Arch Otorhinolaryngol* 2017;274:2921–2926.
40. Schmitt N. HPV in non-oropharyngeal head and neck cancer: does it matter? *Ann Transl Med* 2020;8:1120.
41. Heidarian A, Wenig B. The most common mistake in laryngeal pathology and how to avoid it. *Head Neck Pathol* 2021;15:130–137.
42. Dai L, Fang Q, Li P, Liu F, Zhang X. Oncologic outcomes of patients with sarcomatoid carcinoma of the hypopharynx. *Front Oncol* 2019;24:950.
43. Damiani M, Mercante G, Abdellaoui M, Guerlain J, Moya-Plana A, Casiraghi O *et al.* Prognostic features in intermediate-size supraglottic tumors treated with open supraglottic laryngectomy. *Laryngoscope* 2021;doi:10.1002.
44. Locatello L, Pietragalla M, Taverna C, Bonasera L, Massi D, Mannelli G. A critical reappraisal of primary and recurrent advanced laryngeal cancer staging. *Ann Otol Rhinol Laryngol* 2019;128:36–43.
45. Vilaseca I, Aviles-Jurado F, Valduvico I, Berenguer J, Grau J, Baste N *et al.* Transoral laser microsurgery in locally advanced laryngeal cancer: Prognostic impact of anterior versus posterior compartments. *Head Neck* 2021;12:3832–3842.

46. Marchi F, Missale F, Sampieri C, Filauro M, Landelli A, Parrinello G *et al.* Laryngeal compartmentalization does not affect the prognosis of T3-T4 laryngeal cancer treated by upfront total laryngectomy. *Cancers Basel* 2020;11:2241.
47. Gómez Serrano M, Lglesias Moreno M, Gimeno Hernández J, Ortega Medina L, Martín Villares C, Poch Broto J. Cartilage invasion patterns in laryngeal cancer. *Eur Arch Otorhinolaryngol* 2016;7:1863–1869.
48. Mangussi-Gomes J, Danelon-Leonhardt F, Moussalem G, Ahumada N, Oliveira C, Hojaij F. Thyroid gland invasion in advanced squamous cell carcinoma of the larynx and hypopharynx. *Braz J Otorhinolaryngol* 2017;83:269–275.
49. Alkureishi L, Ross G, Shoaib T, Soutar D, Robertson A, Sorensen J *et al.* Does tumor depth affect nodal upstaging in squamous cell carcinoma of the head and neck? *Laryngoscope* 2008;118:629–634.
50. Tomifuji M, Imanishi Y, Araki K, Yamashita T, Yamamoto S, Kameyama K *et al.* Tumor depth as a predictor of lymph node metastasis of supraglottic and hypopharyngeal cancers. *Ann Surg Oncol* 2011;18:490–496.
51. Iritani K, Del Mundo D, Iwaki S, Masuda K, Kanzawa M, Furukawa T *et al.* Prognostic factors after transoral resection of early hypopharyngeal cancer. *Laryngoscope Investig Otolaryngol* 2021;17:756–763.
52. Fagan J, Collins B, Barnes L, D'Amico F, Myers NE, Johnson J. Perineural invasion in squamous cell carcinoma of the head and neck. *Arch Otolaryngol Head Neck Surg* 1998;124:637–640.
53. Miller M, Palla B, Chen Q, Elashoff D, Abemayor E, St John MA *et al.* A novel classification system for perineural invasion in noncutaneous head and neck squamous cell carcinoma: histologic subcategories and patient outcomes. *Am J Otolaryngol* 2012;3:212–215.
54. Cooper J, Pajak T, Forastiere A, Jacobs J, Campbell B, Saxman S *et al.* Postoperative concurrent radiotherapy and chemotherapy for high-risk squamous-cell carcinoma of the head and neck. *N Engl J Med* 2004;6:1937–1944.
55. Bernier J, Domenge C, Ozsahin M, Matuszewska K, Lefebvre J, Greiner R *et al.* Postoperative irradiation with or without concomitant chemotherapy for locally advanced head and neck cancer. *N Engl J Med* 2004;6:1945–1952.
56. Strojjan P, Ferlito A, Langendijk J, Silver C. Indications for radiotherapy after neck dissection. *Head Neck* 2012;1:113–119.
57. Sethi S, Lu M, Kapke A, Benninger M, Worsham M. Patient and tumor factors at diagnosis in a multi-ethnic primary head and neck squamous cell carcinoma cohort. *J Surg Oncol* 2009;2:104–108.
58. Fletcher K, Gal T, Ebelhar A, Valentino J, Brill Y, Dressler E *et al.* Prognostic indicators and survival in salvage surgery for laryngeal cancer. *Head Neck* 2017;39:2021–2026.
59. Mesolella M, Lorio B, Misso G, Luce A, Cimmino M, Lengo M *et al.* Role of perineural invasion as a prognostic factor in laryngeal cancer. *Oncol Lett* 2016;11:2595–2598.
60. Hughes R, Farris J, Steber C, Frizzell BA, Greven KM. Perineural invasion as the sole pathologic risk factor after surgical resection for head and neck squamous cell carcinoma. *Cureus* 2021;3:13094.

61. Mimica X, Hanson M, Patel S, McGill M, McBride S, Lee N *et al.* Salvage surgery for recurrent larynx cancer. *Head Neck* 2019;41:3906–3915.
62. Leszczyńska M, Tokarski M, Jarmołowska-Jurczyszyn D, Kosikowski P, Szyfter W, Wierzbicka M. Adverse histopathological findings in glottic cancer with anterior commissure involvement. *Eur Arch Otorhinolaryngol* 2015;8:1973–81.
63. Mattioli F, Fermi M, Molinari G, Capriotti V, Melegari G, Bertolini F *et al.* pT3 N0 Laryngeal squamous cell carcinoma: Oncologic outcomes and prognostic factors of surgically treated patients. *Laryngoscope* 2021;131:2262–2268.
64. Brandwein-Gensler M, Teixeira M, Lewis C, Lee B, Rolnitzky L, Hille J *et al.* Oral squamous cell carcinoma: histologic risk assessment, but not margin status, is strongly predictive of local disease-free and overall survival. *Am J Surg Pathol* 2005;2:167–178.
65. Suzuki M, Suzuki T, Asai M, Ichimura K, Nibu K, Sugasawa M *et al.* Clinicopathological factors related to cervical lymph node metastasis in a patient with carcinoma of the oral floor. *Acta Otolaryngol Suppl* 2007;559:129–135.
66. Poleksic S, Kalwaic H. Prognostic value of vascular invasion in squamous cell carcinoma of the head and neck. *Plast Reconstr Surg* 1978;61:234–240.
67. Laramore G, Scott C, Schuller D, Haselow R, Ervin T, Wheeler R *et al.* Is a surgical resection leaving positive margins of benefit to the patient with locally advanced squamous cell carcinoma of the head and neck: a comparative study using the intergroup study 0034 and the Radiation Therapy Oncology Group head and neck database. *Int J Radiat Oncol Biol Phys* 1993;27:1011–1016.
68. Zelefsky M, Harrison L, Fass ED, Armstrong GJ, Shah JP, Strong EW. Postoperative radiation therapy for squamous cell carcinomas of the oral cavity and oropharynx: impact of therapy on patients with positive surgical margins. *Int J Radiat Oncol Biol Phys* 1993;1:17–21.
69. Jacobs J, Ahmad K, Casiano R, Schuller D, Scott C, Laramore G *et al.* Implications of positive surgical margins. *Laryngoscope* 1993;103:64–68.
70. Slootweg P, Hordijk G, Schade Y, van Es Rand Koole R. Treatment failure and margin status in head and neck cancer. A critical view on the potential value of molecular pathology. *Oral Oncol* 2002;38:500–503.
71. Bradley P, MacLennan K, Brakenhoff R, Leemans C. Status of primary tumour surgical margins in squamous head and neck cancer: prognostic implications. *Curr Opin Otolaryngol Head Neck Surg* 2007;4:74–81.
72. Laskar S, Agarwal J, Srinivas C, Dinshaw K. Radiotherapeutic management of locally advanced head and neck cancer. *Expert Rev Anticancer Ther* 2006;3:405–417.
73. Langendijk J, Ferlito A, Takes R, Rodrigo J, Suarez C, Strojan P *et al.* Postoperative strategies after primary surgery for squamous cell carcinoma of the head and neck. *Oral Oncol* 2010;46:577–585.
74. Hinni M, Ferlito A, Gensler M, Takes R, Silver C, Westra W *et al.* Surgical margins in head and neck cancer: a contemporary review. *Head Neck* 2013;35:1362–1370.
75. Alicandri-Ciufelli M, Bonali M, Piccinini A, Marra L, Ghidini A, Cunsolo E *et al.* Surgical margins in head and neck squamous cell carcinoma: what is 'close'? *Eur Arch Otorhinolaryngol* 2013;270:2603–2609.

76. Ansarin M, Santoro L, Cattaneo A, Massaro M, Calabrese L, Giugliano G *et al.* Laser surgery for early glottic cancer: impact of margin status on local control and organ preservation. *Arch Otolaryngol Head Neck Surg* 2009;135:385–390.
77. Liao C, Chang J, Wang H, Ng S, Hsueh C, Lee L *et al.* Analysis of risk factors of predictive local tumor control in oral cavity cancer. *Ann Surg Oncol* 2008;15:915–922.
78. Beibei Y, Rong Y, Yunfei Y, Wenchao Z. Research progress regarding surgical margins, molecular margins, and prognosis of laryngeal carcinoma. *Ear Nose Throat J* 2021;100:597–603.
79. Jumaily M, Faraji F, Osazuwa-Peters N, Walker R, Ward G. Prognostic significance of surgical margins after transoral laser microsurgery for early-stage glottic squamous cell carcinoma. *Oral Oncol* 2019;97:105–111.
80. Sarioglu S, Ikiz A. Radial/circumferential surgical margin in laryngectomy specimens. *Head Neck Pathol* 2017;11:413–415.
81. Meulemans J, Debacker J, Demarsin H, Vanclooster C, Neyt P, Mennes T *et al.* Oncologic outcomes after salvage laryngectomy for squamous cell carcinoma of the larynx and hypopharynx: A multicenter retrospective cohort study. *Ann Surg Oncol* 2021;28:1751–1761.
82. Imai T, Ito S, Oikawa T, Asada Y, Matsumoto K, Miyazaki T *et al.* Risk factors for cervical lymph node metastasis in endoscopically resected superficial hypopharyngeal cancers. *Auris Nasus Larynx* 2019;46:424–430.
83. Davis AA, Patel VG. The role of PD-L1 expression as a predictive biomarker: an analysis of all US Food and Drug Administration (FDA) approvals of immune checkpoint inhibitors. *J Immunother Cancer* 2019;7:278.
84. Gibney GT, Weiner LM, Atkins MB. Predictive biomarkers for checkpoint inhibitor-based immunotherapy. *Lancet Oncol* 2016;17:e542–e551.

## Appendix A SNOMED coding

SNOMED topography should be recorded for the site of the tumour. SNOMED morphology codes should be recorded for the diagnosis/tumour morphology.

Versions of SNOMED prior to SNOMED CT have ceased to be licenced by the International Health Terminology Standards Development Organisation from 26 April 2017. It is recognised that versions of SNOMED 2, SNOMED 3/RT and SNOMED CT are in use in the UK.

SNOMED Procedure codes (P codes in SNOMED 2/3/RT) should be recorded for the procedure. P codes vary according to the SNOMED system in use in different organisations, therefore local P codes should be recorded and used for audit purposes.

A list of applicable SNOMED morphology and topography codes should be provided.

Morphological item	SNOMED code	SNOMED CT terminology	SNOMED CT code
Squamous cell carcinoma in situ	M-80702	Squamous cell carcinoma in situ, no International Classification of Diseases for Oncology subtype (morphologic abnormality)	59529006
Squamous cell carcinoma	M-80703	Squamous cell carcinoma, no International Classification of Diseases for Oncology subtype (morphologic abnormality)	28899001
		Squamous cell carcinoma of oral cavity	733343005
Microinvasive squamous carcinoma	M-80705	Squamous cell carcinoma, microinvasive (morphologic abnormality)	12478003
Keratinising squamous carcinoma	M-80713	Squamous cell carcinoma, keratinizing (morphologic abnormality)	18048008
Non-keratinising squamous carcinoma	M-80723	Squamous cell carcinoma, large cell, nonkeratinizing (morphologic abnormality)	45490001
Spindle cell squamous carcinoma	M-80743	Squamous cell carcinoma, spindle cell (morphologic abnormality)	10288008
Adenoid squamous carcinoma	M-80753	Adenoid squamous cell carcinoma (morphologic abnormality)	85956000
Adenosquamous carcinoma	M-85603	Adenosquamous carcinoma (morphologic abnormality)	59367005

Note: This is not a comprehensive list of all malignancies and other codes should be used as necessary.

<b>Topography item</b>	<b>SNOMED code</b>	<b>SNOMED CT terminology</b>	<b>SNOMED CT code</b>
Larynx	T-24100	Larynx, not otherwise specified	
Epiglottis	T-24010	Epiglottis	
Aryepiglottic fold	T-24310	Aryepiglottic fold, laryngeal aspect	
False cords	T-24320	Ventricular bands (false cords)	
Glottis	T-24440	Glottis	
Vocal cords	T-24400	Vocal cords	
Anterior commissure	T-24470	Commissures	
Subglottis	T-24450	Subglottis	
Larynx and pharynx	T-24920	Larynx and pharynx, cs	
Hypopharynx	T-60300	Hypopharynx	
Post cricoid	T-24080	Pharyngo-oesophageal junction (post-cricoid area)	
Piriform fossa	T-60320	Piriform sinus	
Posterior pharyngeal wall	T-60350	Posterior pharyngeal wall	
Pharynx	T-60000	Pharynx	

### **Procedure codes (P)**

These are used in SNOMED 2 and SNOMED 3 to distinguish biopsies, partial resections and radical resections to indicate the nature of the procedure. Local P codes should be recorded. At present, P codes vary according to the SNOMED system in use in different institutions.



## Appendix B      TNM classification

This provides information on staging using UICC TNM 8.

### Primary tumour (T)

#### Supraglottis

- T1    Tumour limited to one subsite of supraglottis with normal vocal cord mobility
- T2    Tumour invades mucosa of more than one adjacent subsite of supraglottis or glottis or region outside the supraglottis (e.g., mucosa of base of tongue, vallecula, medial wall of pyriform sinus) without fixation of the larynx
- T3    Tumour limited to larynx with vocal cord fixation and/or invades any of the following: postcricoid area, preepiglottic space, paraglottic space, and/or inner cortex of thyroid cartilage
- T4    T4a    Tumour invades through the thyroid cartilage and/or invades tissues beyond the larynx, e.g., trachea, soft tissues of neck including deep/extrinsic muscles of tongue (genioglossus, hypoglossus, palatoglossus, and styloglossus), strap muscles, thyroid, or oesophagus  
  
      T4b    Tumour invades prevertebral space, encases carotid artery, or mediastinal structures.

#### Glottis

- T1    Tumour limited to the vocal cord(s) (may involve anterior or posterior commissure) with normal mobility
  - T1a    Tumour limited to one vocal cord
  - T1b    Tumour involves both vocal cords
- T2    Tumour extends to supraglottis and/or subglottis, and/or with impaired vocal cord mobility
- T3    Tumour limited to the larynx with vocal cord fixation and/or invasion of paraglottic space and /or inner cortex of the thyroid cartilage
- T4    T4a    Tumour invades through the outer cortex of the thyroid cartilage, and/or invades tissue beyond the larynx, e.g., trachea, soft tissues of neck including deep/extrinsic muscles of tongue (genioglossus, hypoglossus, palatoglossus, and styloglossus), strap muscles, thyroid, or oesophagus  
  
      T4b    Tumour invades prevertebral space, encases carotid artery, or mediastinal structures.

#### Subglottis

- T1    Tumour limited to the subglottis
- T2    Tumour extends to vocal cord(s) with normal or impaired mobility
- T3    Tumour limited to larynx with vocal cord fixation
- T4    T4a    Tumour invades cricoid or thyroid cartilage and/or invades tissues beyond the larynx e.g., trachea, soft tissues of neck including deep/extrinsic muscles of tongue (genioglossus, hypoglossus, palatoglossus, and styloglossus), strap muscles, thyroid, or oesophagus

T4b Very advanced local disease, tumour invades prevertebral space, encases carotid artery, or invades mediastinal structures.

### **Hypopharynx**

- T1 Tumour limited to one subsite of hypopharynx and/or 2 cm or smaller in greatest dimension
- T2 Tumour invades more than one subsite of hypopharynx or an adjacent site, or measures larger than 2 cm but not larger than 4 cm in greatest dimension without fixation of hemilarynx
- T3 Tumour more than 4 cm in greatest dimension, or with fixation of hemilarynx or extension to oesophagus
- T4
  - T4a Tumour invades any of the following: thyroid/cricoid cartilage, hyoid bone, thyroid gland, oesophagus, central compartment soft tissue\*
  - T4b Tumour invades prevertebral fascia, encases carotid artery, or involves mediastinal structures.

\*Central compartment soft tissue includes prelaryngeal strap muscles and subcutaneous fat.

## Appendix C Reporting proforma for carcinomas of the larynx and hypopharynx

Surname..... Forenames..... Date of birth.....  
Hospital..... Hospital no..... Sex.....  
Date of receipt..... Date of reporting..... NHS/CHI no.....  
Pathologist..... Surgeon..... Report no.....

---

### Operative procedure (core) (select all that apply)

Not specified  Resection, specify  Transoral laser microsurgical resection   
Transoral robotic surgical resection  Other, specify  .....  
Biopsy (excisional, incisional),  specify .....  
Neck (lymph node) dissection<sup>1</sup>, specify ..... Other  specify.....

### Specimens submitted (core) (select all that apply)

Not specified   
Hypopharynx   
    Laryngopharyngectomy   
    Other, specify .....  
  
Larynx   
    Endolaryngeal excision  Transoral laser excision  Supraglottic laryngectomy   
    Supracricoid laryngectomy  Total laryngectomy   
    Vertical hemilaryngectomy (specify side) .....,  
    Partial laryngectomy (specify type) .....,  
    Other, specify .....

### Specimen dimensions

Maximum dimension (core) .....mm

### Tumour site (core) (select all that apply)

Cannot be assessed   
No macroscopically visible tumour   
Hypopharynx  Left  Right  Midline  Laterality not specified   
    Piriform sinus  Postcricoid  Pharyngeal wall (posterior and/or lateral)   
    Other, specify  .....  
Larynx, supraglottis  Left  Right  Midline  Laterality not specified   
    Epiglottis  (Lingual aspect  Laryngeal aspect   
    Aryepiglottic fold  Arytenoid  False vocal cord/fold   
    Ventricle   
Larynx, glottis  Left  Right  Midline  Laterality not specified   
    True vocal cord/fold  Anterior commissure  Posterior commissure   
Larynx, subglottis  Left  Right  Midline  , Laterality not specified   
    Other  , specify including laterality .....  
Trachea  Left  Right  Midline  Laterality not specified   
Tumour laterality  
    Left  Right  Bilateral/midline

**Tumour dimensions (core)**

Maximum tumour dimension (largest tumour) .....mm

Cannot be assessed, specify .....

**Histological tumour type (core)**

Squamous cell carcinoma, conventional type

Squamous cell carcinoma, variant types  .....

Adenosquamous carcinoma  Basaloid squamous cell carcinoma

Papillary squamous cell carcinoma  Spindle cell squamous cell carcinoma

Verrucous squamous cell carcinoma

Lymphoepithelial carcinoma

Neuroendocrine carcinoma

Well differentiated neuroendocrine carcinoma  Moderately differentiated neuroendocrine carcinoma

Poorly differentiated neuroendocrine carcinoma  (Small cell type  Large cell type

Combined (or composite) neuroendocrine carcinoma, with squamous or adenosquamous component

Carcinomas of minor salivary glands

Adenoid cystic carcinoma  Mucoepidermoid carcinoma  Other, specify .....

Other, specify .....

**Histological tumour grade (core)**

GX: Cannot be assessed

G1: Well differentiated

G2: Moderately differentiated

G3: Poorly differentiated

Not applicable  Other, specify .....

**Extent of invasion (core)**

Larynx

Not identified  Involves mucosa  Involves paraglottic space  Involves pre-epiglottic space

Partial thickness invasion of cartilage  Full thickness invasion of cartilage

Hypopharynx

Tissue layers involved, specify (core) .....

**Perineural invasion (core)**

Not identified  Present  Cannot be assessed, specify  .....

**Lymphovascular invasion (core)**

Not identified  Present  Cannot be assessed, specify  .....

**Margin status (core)**

Invasive carcinoma

Involved  specify margin(s) if possible .....

Not Involved  Distance of tumour from closest margin ..... mm Distance not assessable

Specify closest margin if possible .....

Carcinoma in situ/high-grade dysplasia

Involved  specify margin(s) if possible .....

Not Involved  Distance of tumour from closest margin ..... mm Distance not assessable

Specify closest margin if possible .....

Not applicable  Cannot be assessed, specify  .....

**Pathological staging (core) (UICC TNM 8<sup>th</sup> edition)**

**TNM Descriptors (only if applicable) specify:**

m – multiple primary tumours  r – recurrent  y – post-therapy

**Appendix D Reporting proforma for carcinomas of the larynx and hypopharynx in list format**

<b>Core/ Non-Core</b>	<b>Element name</b>	<b>Values</b>	<b>Implementation notes</b>
Core	Operative procedure	Multi selection value list (select all that apply): <ul style="list-style-type: none"> <li>• Not specified</li> </ul> OR <ul style="list-style-type: none"> <li>• Biopsy (excisional, incisional), specify</li> <li>• Resection, specify</li> <li>• Neck (lymph node) dissection*, specify</li> <li>• Other, specify</li> </ul>	*If a neck dissection is submitted, then a separate dataset is used to record the information.
Core	Specimens submitted	Multi selection value list (select all that apply): <ul style="list-style-type: none"> <li>• Not specified</li> </ul> OR <ul style="list-style-type: none"> <li>• Trachea</li> <li>• Hypopharynx               <ul style="list-style-type: none"> <li>– Laryngopharyngectomy</li> <li>– Other, specify</li> </ul> </li> <li>• Larynx               <ul style="list-style-type: none"> <li>– Endolaryngeal excision</li> <li>– Transoral laser excision</li> <li>– Supraglottic laryngectomy</li> <li>– Supracricoid laryngectomy</li> <li>– Total laryngectomy</li> <li>– Vertical hemilaryngectomy, specify side</li> <li>– Partial laryngectomy, specify type</li> <li>– Other, specify</li> </ul> </li> </ul>	.
Core	Specimen dimensions	Numeric: <ul style="list-style-type: none"> <li>• Maximum dimension ___ mm</li> </ul>	
Core	Tumour site	Multi selection value list (select all that apply): <ul style="list-style-type: none"> <li>• Cannot be assessed</li> </ul>	

Core/ Non-Core	Element name	Values	Implementation notes
		<ul style="list-style-type: none"> <li>• No macroscopically visible tumour</li> <li>OR</li> <li>• Trachea <ul style="list-style-type: none"> <li>– Left</li> <li>– Right</li> <li>– Midline</li> <li>– Laterality not specified</li> </ul> </li> <li>• Hypopharynx <ul style="list-style-type: none"> <li>– Left</li> <li>– Right</li> <li>– Midline</li> <li>– Laterality not specified</li> </ul> </li> <li>• Piriform sinus</li> <li>• Postcricoid</li> <li>• Pharyngeal wall (posterior and/or lateral)</li> <li>• Other, specify</li> <li>• Larynx supraglottis <ul style="list-style-type: none"> <li>– Left</li> <li>– Right</li> <li>– Midline</li> <li>– Laterality not specified</li> </ul> </li> <li>• Epiglottis <ul style="list-style-type: none"> <li>– Lingual aspect</li> <li>– Laryngeal aspect</li> </ul> </li> <li>• Aryepiglottic fold</li> <li>• Arytenoid</li> <li>• False vocal cord/fold</li> <li>• Ventricle</li> <li>• Larynx, glottis <ul style="list-style-type: none"> <li>– Left</li> <li>– Right</li> <li>– Midline</li> <li>– Laterality not specified</li> </ul> </li> </ul> <p>Single selection value list:</p>	

Core/ Non-Core	Element name	Values	Implementation notes
		<ul style="list-style-type: none"> <li>• True vocal cord/fold</li> <li>• Anterior commissure</li> <li>• Posterior commissure</li> <li>• Larynx, subglottis <ul style="list-style-type: none"> <li>– Left</li> <li>– Right</li> <li>– Midline</li> <li>– Laterality not specified</li> </ul> </li> <li>• Tumour laterality <ul style="list-style-type: none"> <li>– Left</li> <li>– Right</li> <li>– Bilateral/midline</li> </ul> </li> <li>• Other, specify including laterality</li> </ul>	
Core	Tumour dimensions	<p>Numeric:</p> <ul style="list-style-type: none"> <li>• Maximum tumour dimension (largest tumour) ___ mm</li> <li>• Cannot be assessed, specify</li> </ul>	
Core	Histological tumour type	<p>Multi selection value list (select all that apply):</p> <ul style="list-style-type: none"> <li>• Squamous cell carcinoma, conventional type</li> <li>• Squamous cell carcinoma, variant types</li> </ul> <p>Single selection value list:</p> <ul style="list-style-type: none"> <li>• Adenosquamous carcinoma</li> <li>• Basaloid squamous cell carcinoma</li> <li>• Papillary squamous cell carcinoma</li> <li>• Spindle cell squamous cell carcinoma</li> <li>• Verrucous squamous cell carcinoma</li> <li>• Lymphoepithelial carcinoma</li> <li>• Neuroendocrine carcinoma</li> </ul> <p>Single selection value list:</p> <ul style="list-style-type: none"> <li>• Well differentiated neuroendocrine carcinoma</li> </ul>	<p>Value list from the WHO Classification of Head and Neck Tumours (2017). Note that permission to publish the WHO classification of tumours may be needed in your implementation. It is advisable to check with the International Agency on Cancer research (IARC).</p>



Core/ Non-Core	Element name	Values	Implementation notes
		<ul style="list-style-type: none"> <li>• Moderately differentiated neuroendocrine carcinoma</li> <li>• Poorly differentiated neuroendocrine carcinoma</li> <li>• Small cell neuroendocrine carcinoma</li> <li>• Large cell neuroendocrine carcinoma</li> <li>• Combined (or composite) neuroendocrine carcinoma, with squamous or adenosquamous component</li> <li>• Carcinomas of minor salivary glands</li> </ul> <p>Single selection value list:</p> <ul style="list-style-type: none"> <li>– Adenoid cystic carcinoma, specify grade</li> <li>– Mucoepidermoid carcinoma, specify grade</li> <li>– Other, specify</li> </ul> <ul style="list-style-type: none"> <li>• Other, specify</li> </ul>	
Core	Histological tumour grade	<p>Single selection value list:</p> <ul style="list-style-type: none"> <li>• Not applicable</li> <li>• GX: Cannot be assessed</li> <li>• G1: Well differentiated</li> <li>• G2: Moderately differentiated</li> <li>• G3: Poorly differentiated</li> <li>• Other, specify</li> </ul>	
Core	Extent of invasion	<p><b>Larynx</b></p> <p>Multi selection value list (select all that apply)/numeric:</p> <ul style="list-style-type: none"> <li>• Not identified</li> </ul> <p>OR</p> <ul style="list-style-type: none"> <li>• Involves mucosa</li> <li>• Involves paraglottic space</li> <li>• Involves pre-epiglottic space</li> <li>• Partial thickness invasion of cartilage</li> <li>• Full thickness invasion of cartilage</li> </ul> <p><b>Hypopharynx</b></p>	

Core/ Non-Core	Element name	Values	Implementation notes
		<ul style="list-style-type: none"> <li>Tissue layers involved, specify</li> </ul>	
Core	Perineural invasion	Single selection value list: <ul style="list-style-type: none"> <li>Not identified</li> <li>Present</li> <li>Cannot be assessed, specify</li> </ul>	
Core	Lymphovascular invasion	Single selection value list: <ul style="list-style-type: none"> <li>Not identified</li> <li>Present</li> <li>Cannot be assessed, specify</li> </ul>	
Core	Margin status	Single selection value list/text/numeric: <b>Invasive carcinoma</b> <ul style="list-style-type: none"> <li>Involved               <ul style="list-style-type: none"> <li>Specify margin(s), if possible</li> </ul> </li> <li>Not involved               <ul style="list-style-type: none"> <li>Distance from closest margin ___ mm</li> <li>Distance not assessable</li> <li>Specify closest margin, if possible</li> </ul> </li> </ul> <b>Carcinoma in situ/high-grade dysplasia**</b> <ul style="list-style-type: none"> <li>Involved               <ul style="list-style-type: none"> <li>Specify margin(s), if possible</li> </ul> </li> <li>Not involved               <ul style="list-style-type: none"> <li>Distance from closest margin ___ mm</li> <li>Distance not assessable</li> <li>Specify closest margin, if possible</li> </ul> </li> <li>Cannot be assessed, specify</li> </ul>	**High-grade dysplasia is synonymous with moderate/ severe dysplasia.
Core	Pathological staging (UICC TNM 8th edition) TNM descriptors	Choose if applicable: <ul style="list-style-type: none"> <li>m – multiple primary tumours</li> <li>r – recurrent</li> <li>y – post-therapy</li> </ul>	Reproduced with permission. Source: Brierley, James D, Gospodarowicz Mary K, Wittekind, Christian. <i>UICC TNM Classification</i>

Core/ Non-Core	Element name	Values	Implementation notes
			<i>of Malignant Tumours (8th edition)</i> , Chichester, UK: Wiley-Blackwell, 2017.
Core	Primary tumour (pT)	Single selection value list: <ul style="list-style-type: none"> <li>• TX Primary tumour cannot be assessed</li> <li>• Tis Carcinoma in situ</li> </ul>	Note that the results of lymph node/neck dissection are derived from a separate dataset.
Core	Primary tumour: Hypopharynx	Single selection value list: <ul style="list-style-type: none"> <li>• T1 Tumour limited to one subsite of hypopharynx and/or 2 cm or less in greatest dimension</li> <li>• T2 Tumour invades more than one subsite of hypopharynx or an adjacent site, or measures more than 2 cm but not more than 4 cm in greatest dimension without fixation of hemilarynx</li> <li>• T3 Tumour more than 4 cm in greatest dimension, or with fixation of hemilarynx or extension to oesophageal mucosa</li> <li>• T4a Moderately advanced local disease: tumour invades any of the following: thyroid/cricoid cartilage, hyoid bone, thyroid gland, oesophagus, or central compartment soft tissue#</li> <li>• T4b Very advanced local disease: tumour invades prevertebral fascia, encases carotid artery, or invades mediastinal structures</li> </ul>	# Central compartment soft tissue includes prelaryngeal strap muscles and subcutaneous fat.
Core	Primary tumour: Supraglottis	Single selection value list: <ul style="list-style-type: none"> <li>• T1 Tumour limited to one subsite of supraglottis with normal vocal cord mobility</li> <li>• T2 Tumour invades mucosa of more than one adjacent subsite of supraglottis or glottis or region outside the supraglottis (e.g. mucosa of base of tongue, vallecula, medial wall of piriform</li> </ul>	

Core/ Non-Core	Element name	Values	Implementation notes
		<p>sinus) without fixation of the larynx</p> <ul style="list-style-type: none"> <li>• T3 Tumour limited to larynx with vocal cord fixation and/or invades any of the following: postcricoid area, pre-epiglottic space, paraglottic space, and/or inner cortex of thyroid cartilage</li> <li>• T4a Moderately advanced local disease: tumour invades through the thyroid cartilage and/or invades tissues beyond the larynx e.g. trachea, soft tissues of neck including deep/extrinsic muscle of tongue (genioglossus, hyoglossus, palatoglossus and styloglossus), strap muscles, thyroid, or oesophagus</li> <li>• T4b Very advanced local disease: tumour invades prevertebral space, encases carotid artery, or mediastinal structures.</li> </ul>	
	Primary tumour: Glottis	<p>Single selection value list:</p> <ul style="list-style-type: none"> <li>• T1 Tumour limited to the vocal cord(s) (may involve anterior or posterior commissure) with normal mobility</li> <li>• T1a Tumour limited to one vocal cord</li> <li>• T1b Tumour involves both vocal cords</li> <li>• T2 Tumour extends to supraglottis and/or subglottis and/or with impaired vocal cord mobility</li> <li>• T3 Tumour limited to the larynx with vocal cord fixation and/or invades paraglottic space, and/or inner cortex of the thyroid cartilage</li> <li>• T4a Tumour invades through the outer cortex of the thyroid cartilage and/or invades tissues beyond the larynx e.g. trachea, soft tissues of neck including deep/extrinsic muscle of the tongue</li> </ul>	

Core/ Non-Core	Element name	Values	Implementation notes
		<p>(genioglossus,hyoglossus, palatoglossus and styloglossus), strap muscles, thyroid, oesophagus</p> <ul style="list-style-type: none"> <li>• T4b Tumour invades prevertebral space, encases carotid artery, or mediastinal structures.</li> </ul>	
Core	Primary tumour: Subglottis	<p>Single selection value list:</p> <ul style="list-style-type: none"> <li>• T1 Tumour limited to subglottis</li> <li>• T2 Tumour extends to vocal cord(s) with normal or impaired mobility</li> <li>• T3 Tumour limited to larynx with vocal cord fixation</li> <li>• T4a Tumour invades cricoid or thyroid cartilage and/or invades tissues beyond the larynx e.g. trachea, soft tissues of neck including deep/extrinsic muscles of tongue (genioglossus,hyoglossus, palatoglossus and styloglossus), strap muscles, thyroid, oesophagus</li> <li>• T4b Tumour invades prevertebral space, encases carotid artery, or mediastinal structures.</li> </ul>	

**Appendix E**      **Summary table – explanation of grades of evidence**  
(modified from Palmer K *et al. BMJ* 2008;337:1832)

Grade (level) of evidence	Nature of evidence
Grade A	<p>At least one high-quality meta-analysis, systematic review of randomised controlled trials or a randomised controlled trial with a very low risk of bias and directly attributable to the target cancer type</p> <p>or</p> <p>A body of evidence demonstrating consistency of results and comprising mainly well-conducted meta-analyses, systematic reviews of randomised controlled trials or randomised controlled trials with a low risk of bias, directly applicable to the target cancer type.</p>
Grade B	<p>A body of evidence demonstrating consistency of results and comprising mainly high-quality systematic reviews of case-control or cohort studies and high-quality case-control or cohort studies with a very low risk of confounding or bias and a high probability that the relation is causal, and which are directly applicable to the target cancer type</p> <p>or</p> <p>Extrapolation evidence from studies described in A.</p>
Grade C	<p>A body of evidence demonstrating consistency of results and including well-conducted case-control or cohort studies and high-quality case-control or cohort studies with a low risk of confounding or bias and a moderate probability that the relation is causal, and which are directly applicable to the target cancer type</p> <p>or</p> <p>Extrapolation evidence from studies described in B.</p>
Grade D	<p>Non-analytic studies such as case reports, case series or expert opinion</p> <p>or</p> <p>Extrapolation evidence from studies described in C.</p>
Good practice point (GPP)	<p>Recommended best practice based on the clinical experience of the authors of the writing group.</p>

## Appendix F AGREE II guideline monitoring sheet

The cancer datasets of The Royal College of Pathologists comply with the AGREE II standards for good quality clinical guidelines ([www.agreetrust.org](http://www.agreetrust.org)). The sections of this dataset that indicate compliance with each of the AGREE II standards are indicated in the table below.

<b>AGREE standard</b>	<b>Section of guideline</b>
<b>Scope and purpose</b>	
1 The overall objective(s) of the guideline is (are) specifically described	Introduction
2 The health question(s) covered by the guideline is (are) specifically described	Introduction
3 The population (patients, public, etc.) to whom the guideline is meant to apply is specifically described	Foreword
<b>Stakeholder involvement</b>	
4 The guideline development group includes individuals from all the relevant professional groups	Foreword
5 The views and preferences of the target population (patients, public, etc.) have been sought	Foreword
6 The target users of the guideline are clearly defined	Introduction
<b>Rigour of development</b>	
7 Systematic methods were used to search for evidence	Foreword
8 The criteria for selecting the evidence are clearly described	Foreword
9 The strengths and limitations of the body of evidence are clearly described	Foreword
10 The methods for formulating the recommendations are clearly described	Foreword
11 The health benefits, side effects and risks have been considered in formulating the recommendations	Foreword and Introduction
12 There is an explicit link between the recommendations and the supporting evidence	All sections
13 The guideline has been externally reviewed by experts prior to its publication	Foreword
14 A procedure for updating the guideline is provided	Foreword
<b>Clarity of presentation</b>	
15 The recommendations are specific and unambiguous	All sections
16 The different options for management of the condition or health issue are clearly presented	All sections
17 Key recommendations are easily identifiable	All sections
<b>Applicability</b>	
18 The guideline describes facilitators and barriers to its application	Foreword
19 The guideline provides advice and/or tools on how the recommendations can be put into practice	Appendices A–D
20 The potential resource implications of applying the recommendations have been considered	Foreword
21 The guideline presents monitoring and/or auditing criteria	Section 11
<b>Editorial independence</b>	
22 The views of the funding body have not influenced the content of the guideline	Foreword
23 Competing interest of guideline development group members have been recorded and addressed	Foreword