



# Guidelines on autopsy practice

## Traumatic brain injury

**December 2023**

**Series authors:** Dr David Bailey, Clinical Lead for Autopsy Guidelines  
Dr Ben Swift, Forensic Pathology Services, Oxon

**Specialist authors:** Dr Rob Goldspring, Nottingham University Hospitals NHS Trust  
Dr Ian Scott, The Walton Centre NHS Foundation Trust

<b>Unique document number</b>	G188
<b>Document name</b>	Guidelines on autopsy practice: Traumatic brain injury
<b>Version number</b>	2
<b>Produced by</b>	The specialist content of this guideline has been produced by Dr Rob Goldspring, Consultant Neuropathologist, Nottingham University Hospitals NHS Trust, and Dr Ian Scott, Consultant Neuropathologist, The Walton Centre NHS Foundation Trust.
<b>Date active</b>	December 2023 <b>(to be implemented within 3 months)</b>
<b>Date for full review</b>	December 2028
<b>Comments</b>	In accordance with the College's pre-publications policy, this document was on the Royal College of Pathologists' website for consultation from 29 March to 26 April 2023. Responses and authors' comments are available to view on publication of the final document.  <b>Dr Brian Rous</b> <b>Clinical Lead for Guideline Review</b>

The Royal College of Pathologists  
6 Alie Street, London E1 8QT  
Tel: 020 7451 6700  
Fax: 020 7451 6701  
Web: [www.rcpath.org](http://www.rcpath.org)

Registered charity in England and Wales, no. 261035  
© 2023, the Royal College of Pathologists



## Contents

1	Introduction.....	5
2	The role of the autopsy.....	5
3	Brain pathology encountered at post-mortem examination .....	6
4	Specific health and safety aspects .....	9
5	Clinical information relevant to the autopsy .....	9
6	The autopsy procedure .....	10
7	Specific organ systems to be considered .....	11
8	Organ retention .....	11
9	Histological examination.....	13
10	Paediatric head injury <sup>13,14</sup> .....	15
11	Toxicology and other relevant samples .....	15
12	Imaging.....	15
13	Clinicopathological summary.....	16
14	Summary of post-mortem brain examination with head injury .....	16
15	Examples of cause of death opinions/statements .....	17
16	Criteria for audit.....	18
17	References .....	19
Appendix A	Recommended blocks to assess diffuse traumatic brain injury .....	21
Appendix B	Summary table – Explanation of grades of evidence.....	22
Appendix C	AGREE II guideline monitoring sheet .....	23



NICE has accredited the process used by the Royal College of Pathologists to produce its autopsy guidelines. Accreditation is valid for 5 years from 25 July 2017. More information on accreditation can be viewed at [www.nice.org.uk/accreditation](http://www.nice.org.uk/accreditation).

For full details on our accreditation visit: [www.nice.org.uk/accreditation](http://www.nice.org.uk/accreditation).

## Foreword

The autopsy guidelines published by the Royal College of Pathologists (RCPATH) are guidelines that enable pathologists to deal with non-forensic consented and Coroner's/Procurators Fiscal's post-mortem examinations in a consistent manner and to a high standard.

The guidelines are systematically developed statements to assist the decisions of practitioners and are based on the best available evidence at the time the document was prepared. Given that much autopsy work is single observer and one-time only in reality, it has to be recognised that there is no reviewable standard that is mandated beyond that of the FRCPath Part 2 exam or the Certificate of Higher Autopsy Training (CHAT).

Nevertheless, much of this can be reviewed against ante-mortem imaging and other data. This guideline has been developed to cover most common circumstances. However, we recognise that guidelines cannot anticipate every pathological specimen type and clinical scenario. Occasional variation from the practice recommended in this guideline may therefore be required to report a case in a way that that maximises benefit to pathologists, Coroners/Procurators Fiscal and the deceased's family. Pathologists should be able to justify any departure from recommended practice.

There is a general requirement from the General Medical Council (GMC) to have continuing professional development (CPD) in all practice areas and this will naturally encompass autopsy practice. Those wishing to develop expertise/specialise in pathology are encouraged to seek appropriate educational opportunities and participate in the relevant external quality assurance (EQA) scheme.

The guidelines themselves constitute the tools for implementation and dissemination of good practice.

The following stakeholders were consulted for this document:

- Human Tissue Authority, which includes representatives from:
  - Association of Anatomical Pathology Technology
  - Institute of Biomedical Science
  - The Coroners' Society of England and Wales
  - Home Office Forensic Science Regulation Unit
  - Forensic Pathology Unit

- British Medical Association
- British Neuropathological Society.

The information used to develop this guideline was obtained by undertaking a systematic search of PubMed. Previous versions of this guideline were also used to inform this update. Key terms searched included traumatic brain injury, cerebral contusion, diffuse axonal injury, diffuse vascular injury, post mortem and autopsy between January 2010 and December 2022. Much of the content of the document represents custom and practice and is based on substantial clinical experience. Consensus of evidence in the guideline was achieved by expert review. Gaps in the evidence will be identified by College members via feedback received during consultation. The sections of this autopsy guideline that indicate compliance with each of the AGREE II standards are indicated in Appendix B.

No major organisational changes or cost implications have been identified that would hinder the implementation of the guidelines.

A formal revision cycle for all guidelines takes place on a 5-yearly cycle. The College will ask the authors of the guideline, to consider whether the guideline needs to be revised. A full consultation process will be undertaken if major revisions are required. If minor revisions or changes are required, whereby a short note of the proposed changes will be placed on the College website for 2 weeks for members' attention. If members do not object to the changes, the short notice of change will be incorporated into the guideline and the full revised version (incorporating the changes) will replace the existing version on the College website.

The guideline has been reviewed by the Professional Guidelines team, Death Investigation Committee, Specialty Advisory Committee and Lay Advisory Group. It was placed on the College website for consultation with the membership from 29 March to 26 April 2023. All comments received from the membership were addressed by the author to the satisfaction of the Clinical Lead for Guideline Review.

This guideline was developed without external funding to the writing group. The College requires the authors of guidelines to provide a list of potential conflicts of interest; these are monitored by the Professional Guidelines team and are available on request. The authors of this document have declared that there are no conflicts of interest.

# 1 Introduction

Traumatic brain injury (TBI) is a significant cause of morbidity and mortality. Each year, ~1.4 million patients attend emergency departments in England and Wales with a recent head injury.<sup>1</sup>

Traumatic brain injuries encompass a range of pathologies, which can be classified, pathologically, as anatomical or pathophysiological; the former will be used in this guideline, which separates pathologies into focal and diffuse. Focal injuries include scalp contusions and lacerations, skull fractures, brain contusions and lacerations and intracranial haemorrhages. Diffuse injuries include diffuse traumatic axonal injuries, diffuse vascular injuries, ischaemia and brain swelling.<sup>2-4</sup>

Post-mortem cases of TBI will usually fall under the jurisdiction of the Coroner or Procurator Fiscal and the examination will be under their instruction. In many instances, the post-mortem examination will be performed by a histopathologist or forensic pathologist. However, referral of the brain +/- spinal cord to a neuropathologist is of benefit to gather information about the nature of trauma, mechanism and timing.

This guideline does not cover repetitive traumatic injury as seen in chronic traumatic encephalopathy.

## 1.1 Target users and health benefits of this guideline

The target primary users of this guideline are histopathologists and neuropathologists performing consented and Coroner's/Procurators Fiscal's post-mortem examinations in persons with TBI. The recommendations will also be of value to specialty registrars, especially those in histopathology considering the Certificate of Higher Autopsy Training (CHAT) and those in diagnostic neuropathology preparing for the FRCPath Part 2. In addition, the guideline will be of use to those undertaking forensic post-mortem examinations.

# 2 The role of the autopsy

- To establish a cause of death.
- To establish whether death is related to TBI.
- To provide a detailed description of the intracranial, intracerebral and spinal pathologies.

- To provide, in cases of criminality, additional information relating to the mechanism and timing of the injuries.
- To provide correlation with clinical and radiological information.
- To provide accurate national statistical information regarding the incidence of the various pathologies seen in TBI.
- To support research into the mechanisms of pathology seen in TBI.
- To provide closure to the family.

*[Level of evidence D – Evidence from case series.]*

### 3 Brain pathology encountered at post-mortem examination

As described above, the typical neuropathological classification separates the head injury pathology into focal and diffuse (Table 1).

**Table 1: Pathological classification of TBI.<sup>2-4</sup>**

<b>Focal</b>	<b>Diffuse</b>
Scalp contusions and lacerations	Diffuse traumatic axonal injury
Skull fractures	Diffuse vascular injury
Brain contusions and lacerations	Diffuse ischaemic brain injury
Intracranial haemorrhage	Brain swelling

#### 3.1 Focal

##### 3.1.1 Scalp injuries

The distribution of bruising and lacerations is important to document in relation to the face and cranium. Photography may be a useful aid for documentation purposes. Bruising suggests a contact injury and, dependent on location, may provide information to any underlying intracranial lesions. In addition, there may be surgical incisions if there has been neurosurgical intervention.

##### 3.1.2 Skull fractures

The frequency of skull fractures is associated with the severity of the head injury. Skull fractures are commonly seen in fatal traumatic head injuries.

### **3.1.3 Contusions and lacerations**

A contusion represents a localised injury and is seen by bruising to the surface of the brain, wherein the pia mater remains intact, in comparison to a laceration where it is disrupted. There are two types of contusion – direct (coup) and indirect (contrecoup) contusions, which can be distinguished by their relation to the site of impact. In direct (coup) contusions, the damaged brain tissue is seen beneath the point of impact and can be anywhere in the brain. It is usually associated with some scalp bruising and sometimes with a skull fracture. In indirect (contrecoup) contusions, the damaged brain tissue is said to occur in an area directly opposite to the point of impact and commonly is seen at the base of the brain in the anterior and inferior aspects of the frontal and temporal lobes.

### **3.1.3 Intracranial haemorrhage**

Intracranial haemorrhages can be classified as extradural, subdural, subarachnoid, intracerebral and intraventricular.

Extradural haematomas are frequently associated with scalp contusions and skull fractures. They typically occur following fractures to the squamous temporal bone that damage the underlying middle meningeal artery.

Subdural haematomas (SDHs) are usually associated with damage to the bridging veins and can occur following mild trauma.

The size (volume) and site of the extradural and/or SHD should be measured. A volume exceeding 40–50 ml is usually associated with pressure effect on the brain. More than 100–120 ml is usually fatal and associated with macroscopic brain midline shift with herniation. The examination should also investigate whether there are any secondary features such as pressure-effects causing midline shift, brain herniation or brainstem haemorrhage.

Traumatic subarachnoid haemorrhages are commonly seen in cases of TBI and may be associated with contusions and lacerations. They can also arise from traumatic injury to the vertebral arteries in the form of rupture or dissection. Of course, they should not be confused with other causes of subarachnoid haemorrhage, including rupture of a berry aneurysm or vascular malformation.

At post mortem, a comprehensive examination of the cerebral blood vessels is essential and should be done at the time of autopsy examination to exclude any aneurysm or vascular malformation. The intracranial and intraspinal parts of the vertebral arteries

should then be examined for any traumatic tear or damage. The vertebral arteries are best examined in situ by careful dissection of the vertebral canal in the cervical spinal column, the dissection extending all the way upwards to the point where the artery enters through the dura at the foramen magnum and downwards to the subclavian artery.<sup>5,6</sup> Any fresh blood should be carefully cleared. The arteries should be carefully removed and processed for serial sectioning.

*[Level of evidence – C.]*

### **3.2 Diffuse injuries**

A range of diffuse injuries may be seen, some of which are obvious macroscopically while others require microscopy.

#### **3.2.1 Diffuse traumatic axonal injury**

Diffuse traumatic axonal injury is seen in relation to both linear acceleration-deceleration and/or rotational mechanical forces of the head. The severity can range from focal injury with a few scattered axons to widespread axonal damage.<sup>3,7</sup> In either case, microscopy is required to make a diagnosis. Diffuse traumatic axonal injury is graded as described in Table 2.

**Table 2: Grading of diffuse traumatic axonal injury.<sup>2-4</sup>**

<b>Grade 1</b>	Microscopic axonal damage in the supra- or infratentorium
<b>Grade 2</b>	As Grade 1, with additional small haemorrhages in the corpus callosum
<b>Grade 3</b>	As Grade 2, with additional small haemorrhages in the brainstem

#### **3.2.2 Diffuse vascular injury**

This is an extreme form of linear or rotational injury in which there is damage to the small white matter vessels, particularly in the frontal and temporal lobes and brainstem structures. Larger haemorrhages may be seen in parasagittal white matter (gliding contusions) and in relation to the basal ganglia. White matter petechial haemorrhage is seen macroscopically. The clinical picture is often that of immediate unconsciousness without neurological recovery.

#### **3.2.3 Diffuse ischaemic brain injury**

This is a common finding in fatal TBI and results from reduced or absent cerebral perfusion. This may be secondary to cardiac arrest associated with other injuries or may be secondary to raised intracranial pressure preventing adequate cerebral perfusion. If



there has been survival of at least several days, laminar necrosis may be seen macroscopically. If there has been a survival of less than a few hours, microscopic examination is unlikely to show any definite neuronal ischaemic injury.

### **3.2.4 Diffuse brain swelling**

Most commonly, brain swelling is secondary to ischaemic injury, although swelling may also be seen in relation to contusions or in the setting of diffuse traumatic axonal injury.

As can be seen from the above discussion, the diagnosis of head injury, while sufficient for national data, gives little information regarding the actual pathology responsible for, or significantly contributing to, the death of the individual.

*[Level of evidence – C.]*

## **4 Specific health and safety aspects**

No specific precautions beyond standard protocols are generally required in TBI post-mortem examinations. Local guidelines for the mortuary should be followed in each case to assess the risk based on available clinical information from the Coroner or Procurator Fiscal and medical records. Personal protective equipment should be used as appropriate to minimise risks. There may be incidental medical devices present, which should be dealt with in line with local guidelines.

*[Level of evidence – GPP.]*

## **5 Clinical information relevant to the autopsy**

Most of the information will come from the Coroner's or Procurator Fiscal's office and through police reports. In some circumstances, this may be supplemented by GP and hospital records.

As with any post-mortem examination, knowledge of past medical history is important. It is useful to have details in relation to the following:

- previous head injury: it is useful to know if there have been one or many episodes of previous head injury, their significance and whether they required neurosurgical intervention. Chronic subdural membranes are more prone to bleed with lesser trauma due to the fragile macro-capillaries found within these membranes.

- social and medical history: recurrent falls are more common among the elderly and alcoholic populations, which may lead to a range of bruises and cuts. Patients on warfarin treatment or with liver disorders are more prone to greater bleeding. Any significant medical history, such as hypertension, should be noted.
- circumstances at the time of death: it is important to have as much detail as possible relating to the incident that caused the fatal head injury. In the setting of a road traffic collision, for example, was the deceased the driver, a passenger or a pedestrian? If within a vehicle, was the deceased wearing a seatbelt? It is important to be aware of other injuries documented at the time of autopsy examination and the results from any studies during life, including any radiological and neurosurgical interventions.
- in criminal cases, information via the police about witnesses or other findings may be very important. All available information should be documented or recorded in the neuropathology report.

*[Level of evidence – GPP.]*

## 6 The autopsy procedure

The post-mortem examination should be performed in the standard way. If tissue is referred for further neuropathological examination, a draft copy of the autopsy report should be provided. If available, a set of photographs of the autopsy may be informative and neuroradiology, if available, should be examined.

The College has produced a useful document outlining an approach to [medicolegal specimens and preserving the chain of evidence](#).

### 6.1 External examination

There should be thorough documentation of any external injuries; for example, in road traffic collisions, there may be bruising indicating that a seatbelt was worn or there may be bruising related to the head or face indicating a point of impact. Photography is strongly recommended for future reference, particularly in criminal cases. Any surgical intervention should also be documented.

### 6.2 Internal examination

There should be consideration for the use of post-mortem imaging, whether this is in conjunction with or in place of a standard invasive post mortem. Imaging can often

demonstrate the nature and extent of skeletal injuries better than an invasive autopsy.<sup>8</sup> Please see section 12 below for further information.

When an invasive post mortem is performed, there should be a standard macroscopic description for each organ system, including documentation of the organ weights. Morbid anatomical causes of death that are visible at the time of post mortem should be sought and, where necessary, supported by histological confirmation; for example, a road traffic collision may have been secondary to a myocardial infarction. It is important to realise that cases of head injury are frequently associated with injury to other organs, soft tissue and bone. All these should be carefully recorded.

*[Level of evidence – GPP.]*

## **7 Specific organ systems to be considered**

### **7.1 Head and neck**

The scalp and skull should be carefully examined for signs of impact injury. Any skull fractures should be carefully documented and, if appropriate, an illustration should be recorded, either photographic or drawn. When reflecting the dura, the bridging veins should be studied and any obvious tears documented.

The spinal column and in particular the cervical spine should be carefully examined. Any soft tissue haemorrhages or fractures to the spinal column should be documented and the underlying cord should be examined.

Where available, we would encourage radiological imaging of the neck in cases of suspected bony injury.

*[Level of evidence – GPP.]*

## **8 Organ retention**

The optimum process is for brain retention to allow complete neuropathological examination. Ordinarily, this involves brain fixation in 10% formalin for a minimum of 2 weeks, but preferably for 4–6 weeks;<sup>6</sup> however, it is understood that current practice may involve a modified approach. It remains that in all cases of criminality, involving significant head injury, the recommendation remains that the brain is retained for prolonged fixation prior to examination. The Coroner/Procurator Fiscal and, through their office, the

deceased's family should be informed that a completed neuropathological examination will be provided within a period of approximately 3 months from the time of death.

The following are offered as compromises in situations where there is no consent for retention of the brain for prolonged fixation.

- There are many situations where the macroscopic pathology alone is informative and allows a confident discussion of the pathophysiology of the cause of death. An example would be an accidental fall with SDH and mass effect associated with axial displacement.
- The brain may be retained in fixative for a period of not more than 24 hours and then sliced in the standard way and samples taken for histological analysis. This provides a reasonable degree of fixation and makes sectioning of the brain easier than in the fresh state. The brain can then be returned to the body for burial or cremation.<sup>9</sup>
- Retention of a mid-region coronal section of brain and sections of brainstem and cerebellum. In this scenario, the brain is examined and sectioned in the fresh state. A single section of the cerebrum beginning approximately 1 cm caudal to the mamillary bodies is retained. This section should be approximately 1 cm in thickness. A block of anterior corpus callosum, a section of left and right cerebellar hemispheres and sections of midbrain, pons and medulla should also be retained for histological examination. It should be made clear to the Coroner/Procurator Fiscal that all tissue retained in this slice will be processed for histological examination and that no tissues will be retained out with paraffin blocks, or that any retained small fragments of tissue will be disposed of in line with Human Tissue Act/Human Tissue (Scotland) Act. Histology blocks should also be taken from any other pathological lesion. If the spinal cord has been retained, representative sections of cervical, thoracic, lumbar and sacral regions should be put directly into histology cassettes for fixation.

In whichever method is used, it is preferable that the brain is photographed. The photographs should be labelled and stored with case files for future reference (within standard record retention periods).

*[Level of evidence – GPP.]*

## 9 Histological examination

In many cases, histology is not required as the macroscopic examination can provide all the information required. Histology is most useful in the assessment of diffuse injury, or where assessment of a focal lesion may provide additional information regarding timing of an injury.

The following is suggested for a minimum approach to the investigation of TBI.

### 9.1 General histology

Representative histology should be taken, if relevant to the cause of death, as felt appropriate and determined by the findings at the post-mortem examination; for example, myocardium may be taken if there has been a suspected myocardial infarction.

### 9.2 Neuropathology

#### 9.2.1 Focal pathology

Any focal pathology identified at the time of post-mortem may be examined microscopically. Extradural or SDHs should be sampled in the form of a dural roll. This requires a section of dura to be rolled up and cut to a thickness of no more than 1 cm before being placed into a histology cassette. Sampling of these lesions may allow a rough estimate at timing if the clinical history is incomplete. Take extra blocks from different regions if more than 1 episode of bleeding is suspected by the history or gross examination.

#### 9.2.2 Diffuse pathology

Diffuse lesions should always be considered when the patient has been unconscious in the absence of any focal mass lesion. The commonest diffuse pathologies are diffuse traumatic axonal injury and global ischaemic injury. The following is recommended as part of the assessment of diffuse lesions within the brain (Table 3). The blocks should be taken from both the right and left side (see Appendix A).

**Table 3: Recommended blocks to be taken in cases of diffuse TBI.<sup>2,4,10</sup>**

<b>1</b>	Parasagittal anterior frontal white matter and genu of the corpus callosum (at the level of the head of the caudate nucleus)
<b>2</b>	Anterior watershed
<b>3</b>	Deep grey watershed
<b>4</b>	Basal ganglia, including the posterior limb of the internal capsule (at the level of the mid thalamus)
<b>5</b>	Temporal lobe to include the hippocampus (at the level of the lateral geniculate body)
<b>6</b>	Parasagittal parietal white matter and splenium of the corpus callosum
<b>7</b>	Posterior watershed
<b>8</b>	Occipital cortex
<b>9</b>	Midbrain, including the decussation of the superior cerebellar peduncle
<b>10</b>	Pons, including the superior or middle cerebellar peduncles
<b>11</b>	Cerebellar hemisphere
<b>Also consider</b>	Medulla Spinal cord (cervical, thoracic, lumbar, sacral) – if retained Focal lesions – if present

If large blocks cannot be processed, two or more smaller contiguous samples could be taken from a particular region.

### 9.2.3 Spinal cord

The most common scenario where the spinal cord is examined is in the setting of cervical spine injury with damage to the underlying cord. Only a small segment of cervical cord should be examined in this setting and the sampling should be related to the areas of bony injury.

### 9.3 Staining

In extra- or SDHs, the sections of dura may be stained with H&E, Perls' stain and CD68, which are useful to age the haematoma.

The brain sections may be stained with H&E and, when required, beta amyloid precursor protein ( $\beta$ APP) and CD68.

Diffuse axonal injury is best demonstrated by  $\beta$ APP immunohistochemical staining.  $\beta$ APP staining for traumatic axonal injury should be differentiated from staining associated with ischaemic injury (vascular axonal injury), such as those seen in cases of a space occupying lesion (e.g. SDH) with increase in the intracranial pressure and brain shifting.<sup>2-4,11,12</sup>

*[Level of evidence – D.]*

## 10 Paediatric head injury<sup>13,14</sup>

Neuropathologists may face cases of paediatric head injury, including non-accidental child death with head injury. The same clinical rules of examination of the brain in child head trauma as in adults should be followed with the following additional recommendations:

- the dura should be examined thoroughly and sampled from different locations if SDH is present
- the brainstem and cervicomedullary region should be sampled extensively to investigate axonal injury
- the whole spinal cord should be examined and sampled thoroughly (blocks are taken as mentioned in 9.2.2) and examined for focal lesions, axonal injury in the white matter and spinal nerve roots. Subdural and subarachnoid haemorrhage in the spinal cord also needs to be documented.

*[Level of evidence – D.]*

## 11 Toxicology and other relevant samples

Toxicology and other relevant samples may be required in discussion with the Coroner or Procurator Fiscal. In deaths following assaults or road traffic collisions, alcohol and other drugs may need to be assessed.

*[Level of evidence – GPP.]*

## 12 Imaging

Imaging post-mortems have been implemented by some coronial jurisdictions to supplement or replace the standard invasive post mortem.<sup>15</sup> They are useful in documenting the nature and extent of traumatic injuries, for example skull fractures and

intracranial haemorrhage; however, base of skull fractures may be difficult to detect if they are non-displaced.

Imaging post mortems should never be undertaken without an external examination performed by a GMC-registered pathologist.<sup>8</sup>

*[Level of evidence – D.]*

## 13 Clinicopathological summary

The clinicopathological summary needs to be clear and concise and the pathologist must remember that this is likely to form part of a medicolegal document. Therefore, only relevant statements of fact should be provided. The pathologist should clearly outline their macroscopic and microscopic observations. This should be considered in light of the clinical history provided. An overall summary should be made to correlate the pathological findings with the clinical history provided and, in particular, to highlight consistencies or inconsistencies between them. It is important for the pathologist to highlight areas of certainty and uncertainty, in particular in relation to mechanism and timing of injuries.

*[Level of evidence – D.]*

## 14 Summary of post-mortem brain examination with head injury

- Contusions
  - site: temporal, frontal, other site (coup and countercoup)
  - measurement: may be related to severity of head injury.
- Subarachnoid haemorrhage
  - distribution (diffuse or localised)
  - if basal, exclude possibility of berry aneurysm and examine vertebral arteries (intracranial and intraspinal courses) for traumatic tear.
- Brain herniation
  - uncal herniation (remove brainstem and cerebellum for better assessment), bilateral or unilateral



- tonsillar herniation, usually associated with haemorrhage and necrosis rather than only bulging
- subfalcine herniation
- brain shifting – corpus callosum and lateral ventricle.
- Brain swelling.
- Corpus callosum and fornix.
- Infarction and ischaemia
  - site
  - arterial territory.
- Intracranial haemorrhage
  - related to an expanding contusion
  - deep structure of brain like white matter and basal ganglia.
- Brainstem
  - diffuse traumatic axonal injury (small bleeding: dorso-lateral quadrants and superior cerebellar peduncle)
  - diffuse vascular injury (small bleeding: subependymal and around fourth ventricles and aqueduct)
  - ↑ ICP (haemorrhage in midline).

*[Level of evidence – D.]*

## **15 Examples of cause of death opinions/statements**

1a) Head injuries following a fall from height.

1a) Raised intracranial pressure with brainstem compression.

1b) SDH.

1c) Traumatic head injury.

1a) Subarachnoid haemorrhage.

1b) Vertebral artery dissection.

1c) Rotational head injury.

1a) Diffuse axonal injury.

1b) Road traffic collision.

## 16 Criteria for audit

The following standards are suggested criteria that might be used in periodic reviews to ensure a post-mortem report for coronial autopsies conducted at an institution comply with the national recommendations provided by the 2006 NCEPOD study:

- supporting documentations:
  - standards: 95% of supporting documentation was available at the time of the autopsy
  - standards: 95% of autopsy reports documented are satisfactory, good or excellent.
- reporting internal examination:
  - standards: 100% of the autopsy report must explain the description of internal appearance
  - standards: 100% of autopsy reports documented are satisfactory, good or excellent.
- reporting external examination:
  - standards: 100% of the autopsy report must explain the description of external appearance
  - standards: 100% of autopsy reports documented are satisfactory, good or excellent.

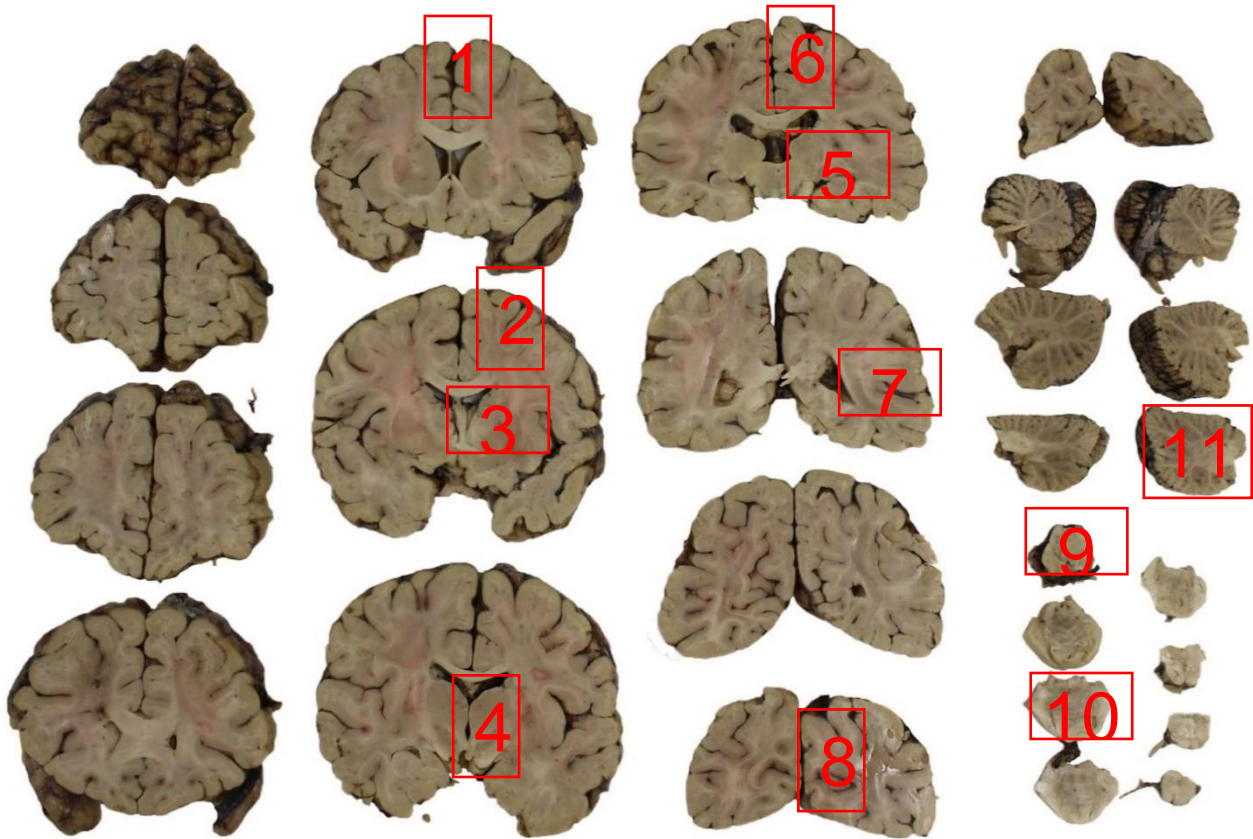
A [template for coronial autopsy audit](#) can be found on The Royal College of Pathologists' website.

## 17 References

1. National Institute for Health and Clinical Excellence. *Guidance. Head injury: triage, assessment, investigation and early management of head injury in children, young people and adults*. London, UK: National Institute for Health and Care Excellence, 2014.
2. Al-Sarraj S. The pathology of traumatic brain injury (TBI): a practical approach. *Diagn Histopathol* 2016;22:318–326.
3. Ellison D, Love S, Lowe J, Vinters H, Harding BN, Chimelli L *et al*. *Neuropathology: a Reference Text of CNS Pathology (3rd edition)*. Edinburgh, UK: Mosby/Elsevier, 2013.
4. Love S, Budka H, Ironside JW, Perry A. *Greenfield's Neuropathology (9th edition)*. Boca Raton, USA: CRC Press Routledge, 2015.
5. Bromilow A, Burns J. Technique for removal of the vertebral arteries. *J Clin Pathol* 1985;38:1400–1402.
6. Dawson TP, Llewellyn L, Thomas C, Neal JW. *Neuropathology Techniques*. London, UK: Arnold, 2003.
7. McKee AC, Daneshvar DH. The neuropathology of traumatic brain injury. *Handb Clin Neurol* 2015;127:45–66.
8. Osborn M, Roberts I, Ruttly G, Traill Z, Morgan B. *Guidelines for post-mortem cross-sectional imaging in adults for non-forensic deaths*. London, UK: The Royal College of Pathologists, 2021. Available at: [www.rcpath.org/profession/guidelines/autopsy-guidelines-series.html](http://www.rcpath.org/profession/guidelines/autopsy-guidelines-series.html)
9. Scott IS, MacDonald AW. An evaluation of overnight fixation to facilitate neuropathological examination in Coroner's autopsies: our experience of over 200 cases. *J Clin Pathol* 2013;66:50–53.
10. Geddes JF, Whitwell HL, Graham DI. Traumatic axonal injury: practical issues for diagnosis in medico-legal cases. *Neuropathol Appl Neurobiol* 2000;26:105–116.
11. Reichard RR, Smith C, Graham DI. The significance of  $\beta$ APP immunoreactivity in forensic practice. *Neuropathol Applied Neurobiol* 2005;31;304–313.

12. Graham DI, Smith C, Reichard R, Leclercq PD, Gentleman SM. Trials and tribulations of using beta-amyloid precursor protein immunohistochemistry to evaluate traumatic brain injury in adults. *Forensic Sci Int* 2004;146:89–96.
13. Geddes JF, Hackshaw AK, Vowles GH, Nickols CD, Whitwell HL. Neuropathology of inflicted head injury in children. I: Patterns of brain damage. *Brain* 2001;124:1290–1298.
14. Geddes JF, Vowles GH, Hackshaw AK, Nickols CD, Scott IS, Whitwell HL. Neuropathology of inflicted head injury in children. II: Microscopic brain injury in infants. *Brain* 2001;124:1299–1306.
15. The Coroner’s Society of England and Wales. *Chief Coroner. Guidance No.32 Post-mortem examinations including second post-mortem examinations*. Accessed April 2022. Available at: <https://www.coronersociety.org.uk/announcements/chief-coroner-guidance-32--post-mortem-examination-including-2nd-post-mortems/>

## Appendix A Recommended blocks to assess diffuse traumatic brain injury



- 1 Anterior frontal white matter and genu of the corpus callosum.
- 2 Anterior watershed.
- 3 Deep grey watershed.
- 4 Basal ganglia, including the posterior limb of the internal capsule.
- 5 Temporal lobe to include the hippocampus.
- 6 Parietal white matter and splenium of the corpus callosum.
- 7 Posterior watershed.
- 8 Occipital cortex.
- 9 Midbrain.
- 10 Pons.
- 11 Cerebellar hemisphere.

## Appendix B Summary table – Explanation of grades of evidence

(modified from Palmer K *et al. BMJ* 2008; 337:1832)

Grade (level) of evidence	Nature of evidence
Grade A	<p>At least one high-quality meta-analysis, systematic review of randomised controlled trials or a randomised controlled trial with a very low risk of bias and directly attributable to the target population</p> <p>or</p> <p>A body of evidence demonstrating consistency of results and comprising mainly well-conducted meta-analyses, systematic reviews of randomised controlled trials or randomised controlled trials with a low risk of bias, directly applicable to the target cancer type.</p>
Grade B	<p>A body of evidence demonstrating consistency of results and comprising mainly high-quality systematic reviews of case-control or cohort studies and high-quality case-control or cohort studies with a very low risk of confounding or bias and a high probability that the relation is causal and which are directly applicable to the target population</p> <p>or</p> <p>Extrapolation evidence from studies described in A.</p>
Grade C	<p>A body of evidence demonstrating consistency of results and including well-conducted case-control or cohort studies and high-quality case-control or cohort studies with a low risk of confounding or bias and a moderate probability that the relation is causal and which are directly applicable to the target population</p> <p>or</p> <p>Extrapolation evidence from studies described in B.</p>
Grade D	<p>Non-analytic studies such as case reports, case series or expert opinion</p> <p>or</p> <p>Extrapolation evidence from studies described in C.</p>
Good practice point (GPP)	<p>Recommended best practice based on the clinical experience of the authors of the writing group.</p>

## Appendix C AGREE II guideline monitoring sheet

The autopsy guidelines of The Royal College of Pathologists comply with the AGREE II standards for good quality clinical guidelines. The sections of this autopsy guideline that indicate compliance with each of the AGREE II standards are indicated in the table.

AGREE standard	Section of guideline
<b>Scope and purpose</b>	
1 The overall objective(s) of the guideline is (are) specifically described	Introduction
2 The health question(s) covered by the guideline is (are) specifically described	Introduction
3 The population (patients, public, etc.) to whom the guideline is meant to apply is specifically described	Foreword
<b>Stakeholder involvement</b>	
4 The guideline development group includes individuals from all the relevant professional groups	Foreword
5 The views and preferences of the target population (patients, public, etc.) have been sought	Foreword
6 The target users of the guideline are clearly defined	Introduction
<b>Rigour of development</b>	
7 Systematic methods were used to search for evidence	Foreword
8 The criteria for selecting the evidence are clearly described	Foreword
9 The strengths and limitations of the body of evidence are clearly described	Foreword
10 The methods for formulating the recommendations are clearly described	Foreword
11 The health benefits, side effects and risks have been considered in formulating the recommendations	Foreword and Introduction
12 There is an explicit link between the recommendations and the supporting evidence	2–15
13 The guideline has been externally reviewed by experts prior to its publication	Foreword
14 A procedure for updating the guideline is provided	Foreword
<b>Clarity of presentation</b>	
15 The recommendations are specific and unambiguous	2–15
16 The different options for management of the condition or health issue are clearly presented	2–15
17 Key recommendations are easily identifiable	2–15
<b>Applicability</b>	
18 The guideline describes facilitators and barriers to its application	Foreword
19 The guideline provides advice and/or tools on how the recommendations can be put into practice	2–15
20 The potential resource implications of applying the recommendations have been considered	Foreword
21 The guideline presents monitoring and/or auditing criteria	16
<b>Editorial independence</b>	
22 The views of the funding body have not influenced the content of the guideline	Foreword
23 Competing interest of guideline development group members have been recorded and addressed	Foreword