



# Standards and datasets for reporting cancers

## Dataset for histopathological reporting of cancer of unknown primary and malignancy of unknown primary origin

**DRAFT January 2024**

**Authors:** Professor John B Schofield, Maidstone and Tunbridge Wells NHS Trust  
Professor Karin A Oien, Institute of Cancer Sciences, University of Glasgow

<b>Unique document number</b>	G167
<b>Document name</b>	Dataset for histopathological reporting of cancer of unknown primary and malignancy of unknown origin
<b>Version number</b>	2
<b>Produced by</b>	Both of the authors are consultant histopathologists with a special interest in the pathology of malignant disease. JB Schofield is a former member of the Working Group on Cancer Services and has co-authored over 80 publications, mostly in the field of oncological pathology. KA Oien has research and clinical expertise in the field of cancer of unknown primary.
<b>Date active</b>	January 2024 <b>(to be implemented within 3 months)</b>
<b>Date for full review</b>	January 2027
<b>Comments</b>	<p>This document replaces the 1st edition of Dataset for histopathological reporting of cancer of unknown primary (CUP) and malignancy of unknown primary origin (MUO), published in 2018.</p> <p>In accordance with the College's pre-publications policy, this document will be on the Royal College of Pathologists' website for consultation from 31 January to 28 February 2024. Responses and authors' comments will be available to view on final publication.</p> <p><b>Dr Brian Rous,</b> <b>Clinical Lead for Guideline Review</b></p>



## Contents

Foreword.....	4
1 Introduction.....	5
2 Clinical information required on the specimen request form.....	13
3 Preparation of specimens before dissection.....	14
4 Specimen handling and block selection .....	15
5 Evaluation of potential CUP specimens by morphology and immunohistochemistry (see Appendices C–E) .....	16
6 Core data items .....	32
7 Non-core data items .....	34
8 Diagnostic coding and staging.....	34
9 Reporting of small biopsy specimens .....	34
10 Reporting of frozen sections.....	35
11 Report content.....	35
12 Criteria for audit.....	35
13 Acknowledgements .....	36
14 References .....	37
Appendix A SNOMED codes .....	45
Appendix B TNM staging for squamous cell carcinoma of unknown primary involving cervical lymph nodes <sup>78</sup> .....	47
Appendix C Reporting proforma for cancer of unknown primary (CUP).....	49

Appendix D	Reporting proforma for cancer of unknown primary (CUP) in list format ..	51
Appendix E	Histopathology worksheet for metastatic carcinoma of uncertain primary site .....	55
Appendix F	Summary table – Explanation of grades of evidence .....	57
Appendix G	AGREE II guideline monitoring sheet .....	58



NICE has accredited the process used by the Royal College of Pathologists to produce its guidelines. Accreditation is valid for 5 years from 25 July 2017. More information on accreditation can be viewed at [www.nice.org.uk/accreditation](http://www.nice.org.uk/accreditation).

For full details on our accreditation visit: [www.nice.org.uk/accreditation](http://www.nice.org.uk/accreditation).

## Foreword

The cancer datasets published by the Royal College of Pathologists (RCPATH) are a combination of textual guidance, educational information and reporting proformas. The datasets enable pathologists to grade and stage cancers in an accurate, consistent manner in compliance with international standards and provide prognostic information, thereby allowing clinicians to provide a high standard of care for patients and appropriate management for specific clinical circumstances. On rare occasions, it may be necessary or even desirable to depart from the guidelines in the interests of specific patients and special circumstances. The guideline has been developed to cover most common scenarios. However, it is recognised that guidelines cannot accommodate every pathological specimen type and clinical scenario. Occasional variation from the practice recommended in the guideline may therefore be required to report the specimen in a way that maximises the benefit to the patient.

Each dataset contains core data items that are mandated for inclusion in the Cancer Outcomes and Services Dataset (COSD – previously the National Cancer Data Set) in England. Core data items are items that are supported by robust published evidence and are required for cancer staging, optimal patient management and prognosis. Core data items meet the requirements of professional standards (as defined by the Information Standards Board for Health and Social Care [ISB]) and it is recommended that at least 90% of reports should record a full set of core data items. All data items should be clearly defined to allow the unambiguous recording of data.

The following stakeholder was contacted to consult on this document:

- Cancer of Unknown Primary Foundation – Jo's Friends.<sup>1</sup>

The information used to develop this dataset was obtained by undertaking a systematic search of the literature using PubMed search of MEDLINE and related databases. Key terms searched included: cancer, carcinoma, adenocarcinoma, metastasis, metastases or malignancy; and unknown origin or unknown primary. Publications from January 2016 to September 2023 were included. The search yielded 2,650 publications, from which a smaller number of studies met the selection criteria and were considered for review. Published evidence was evaluated using modified SIGN guidance (see Appendix F). Consensus of evidence in the guideline was achieved by expert review. Gaps in the evidence were identified by College members via feedback received during consultation. 2 key prior publications include: the National Institute of Health and Care Excellence (NICE)

*Improving Outcomes Guidance, 2010, and the National Cancer Peer Review (NCPR) Standards for Cancer of Unknown Primary/Malignancy of Unknown Origin, 2014.*<sup>2,3</sup>

No major organisational changes or cost implications have been identified that would hinder the implementation of the dataset.

A formal revision cycle for all cancer datasets takes place on a 3-yearly basis. However, each year, the College will ask the authors of the dataset, in conjunction with the relevant subspecialty adviser to the College, to consider whether or not the dataset needs to be revised. A full consultation process will be undertaken if major revisions are required, i.e. revisions to core data items (the only exception being changes to international tumour grading and staging schemes that have been approved by the Specialty Advisory Committee on Cellular Pathology and affiliated professional bodies; these changes will be implemented without further consultation). If minor revisions or changes to non-core data items are required, an abridged consultation process will be undertaken, whereby a short note of the proposed changes will be placed on the College website for 2 weeks for Fellows' attention. If Fellows do not object to the changes, the short notice of change will be incorporated into the dataset and the full revised version (incorporating the changes) will replace the existing version on the College website.

The dataset has been reviewed by the Professional Guidelines team, Working Group on Cancer Services and Lay Advisory Group and will be placed on the College website for consultation with the membership from 31 January to 28 February 2024. All comments received from the above groups and membership will be addressed by the authors to the satisfaction of the Chair of the Working Group and the Clinical Lead for Guideline Review.

This dataset was developed without external funding to the writing group. The College requires the authors of datasets to provide a list of potential conflicts of interest; these are monitored by the Professional Guidelines team and are available on request. The authors have declared that they have no conflicts of interest.

## 1 Introduction

2 This is the second edition of these guidelines. While the general approach to diagnosis of  
3 cancer of unknown primary (CUP)/malignancy of unknown origin (MUO) has not altered  
4 significantly, there are several changes in this version. References have been updated to  
5 reflect papers and guidelines published in the last 4 years. A number of newer  
6 immunohistochemical (IHC) markers have been adopted into or become more established

1 in routine clinical practice, such as GATA3, PAX8, NKX3.1 and SOX10. The anticipated  
 2 wider use of molecular profiling has been slow to arrive, but with the development of the  
 3 national Genomic Laboratory Hubs (GLHs) in England and their equivalents in devolved  
 4 nations, this may become more widespread over the next few years.<sup>5</sup> However,  
 5 randomised prospective clinical trials have not yet demonstrated a clinical benefit for CUP  
 6 patients from the use of molecularly directed therapies; furthermore, international and  
 7 national guidelines do not currently recommend routine use of molecular tissue-of-origin  
 8 predictors in CUP management.<sup>6</sup> It is interesting to note that the incidence of CUP is  
 9 gradually declining in the UK and worldwide, perhaps at least in part because of multi-  
 10 disciplinary management and investigation and techniques enabling a more type- and/or  
 11 site-specific cancer diagnosis in some.<sup>7</sup>

12 The majority of patients with cancer present with a clearly defined primary tumour that  
 13 manifests with local symptoms. However, about 10–15% of patients present initially with  
 14 metastatic disease. In many of these patients, the site of origin initially will not be obvious  
 15 and in about one third of these cases the primary tumour site may never be found.<sup>8</sup>  
 16 CUP/MUO is thus a common and important clinical problem and represents one of the 10  
 17 most common cancer diagnoses. As described in clinical reviews, 2–5% of new cancer  
 18 diagnoses are classified as CUP after full investigation.<sup>9–11</sup> While these tumours are  
 19 commonly encountered in routine clinical practice, by their nature they provide significant  
 20 diagnostic challenges to the pathologist. Terminology and definitions vary in different  
 21 publications and we advise using the NICE-agreed terms (Table 1), as originally  
 22 developed for the 2010 NICE guidelines on CUP (metastatic malignant disease of  
 23 unknown primary origin).<sup>2,12</sup>

24 **Table 1: NICE guidance on metastatic malignant disease of unknown primary origin.**  
 25 **(Based on NICE guidelines on CUP.)<sup>2</sup>**

<b>MUO</b>	Metastatic malignancy identified on the basis of a limited number of tests, without an obvious primary site, before comprehensive investigation.
<b>Provisional CUP</b>	Metastatic epithelial or neuroendocrine malignancy identified on the basis of histology or cytology, with no primary site detected despite a selected initial screen of investigations, before specialist review and possible further specialised investigations.
<b>Confirmed CUP</b>	Metastatic epithelial or neuroendocrine malignancy identified on the basis of final histology, with no primary site detected despite a selected initial screen of investigations, specialist review and further specialised investigations as appropriate.

## 1 **1.1 Epidemiology and clinical context**

2 According to recent Cancer Research UK incidence and mortality data, CUP formed 2% of  
3 all new cancer diagnoses in the UK in 2016–2018; and CUP was the diagnosis in 6% of  
4 cancer deaths in 2017–2019.<sup>13</sup> Interestingly, and encouragingly, over the last decade,  
5 incidence rates for CUP have decreased by a third (33%) in the UK,<sup>13</sup> in keeping with  
6 trends worldwide.<sup>7</sup> CUP incidence increases with age, with more than half of cases (57%)  
7 of CUP in the UK diagnosed in people aged 75 and over.<sup>13</sup> The overall median survival of  
8 patients with CUP/MUO within oncology services has been widely quoted as 8–11 months;  
9 however, population-wide the figure may be lower, with data from Scotland suggesting an  
10 overall median survival nearer to 1–3 months.<sup>9,10,14</sup>

11 Conversely, there are subgroups of patients with much longer survival times and/or  
12 disease subtypes that respond well to available treatment, especially chemotherapy; the  
13 identification of this subgroup of patients is the major goal of the pathological workup.<sup>8,15</sup>  
14 These ‘favourable’ tumours account for approximately 20% of clinical CUP and include  
15 lymphoma, germ cell tumour, neuroendocrine tumour/carcinoma, squamous carcinoma  
16 involving only local lymph nodes and adenocarcinomas for which specific therapy is  
17 available.<sup>16,17</sup> The diagnosis of provisional CUP is usually based on a clinical scenario in  
18 which no primary tumour is apparent on initial workup by examination or initial imaging, as  
19 described in the CUP guidelines from NICE, the European Society of Medical Oncology  
20 (ESMO), the Spanish Societies of Pathology and Medical Oncology and the National  
21 Comprehensive Cancer Network (NCCN) in North America, and where biopsy of a  
22 presumed metastatic deposit does not show clear evidence of a primary site.<sup>2,18–20</sup> As  
23 more information becomes available, a significant proportion of these provisional  
24 metastatic CUPs will become identified as a specific tumour type and the site of origin will  
25 be confirmed clinically; in some cases, the apparent metastasis will be shown to be a  
26 primary tumour at that site, often with atypical morphology.

27 When the pathologist is faced with a provisional CUP biopsy, it is crucial that they obtain  
28 all relevant clinical information and check for a past history of malignancy by all possible  
29 routes including interrogation of the laboratory information management system.<sup>16</sup> This  
30 can be helpful, for example, in the identification of a previously removed melanocytic  
31 lesion, which may require histological review. Occupational history should be sought as  
32 well as results of appropriate imaging modalities.<sup>15</sup> Knowledge of serum cancer marker  
33 status is also highly valuable.<sup>21</sup>

34 *[Level of evidence – C.]*

## 1 **1.2 Pathological approach**

2 The pathological approach to exclusion or diagnosis of CUP/MUO is stepwise and uses  
3 clinical context, morphology, immunohistochemistry and, occasionally, other techniques  
4 including molecular analysis.

5 After optimising the tissue biopsy submitted, which must be embedded entirely to ensure  
6 no better differentiated component can be seen on morphology, the specimen needs to be  
7 subjected to careful morphological analysis. Sufficient tissue needs to be retained for a  
8 detailed evaluation, sometimes involving several rounds of IHC staining and potentially  
9 molecular studies. Retention of serial spare sections on coated slides helps maximise the  
10 tissue available from small biopsies. Where there are multiple fragments, embedding in  
11 separate blocks can also maximise tissue availability. To enable optimal handling of  
12 scarce tissue, it is helpful to know in advance that the biopsy is from a provisional CUP  
13 case, from the clinical history provided by the referring clinician or from previous  
14 multidisciplinary team (MDT) discussions. Should molecular studies be judged likely and if  
15 material is limited, a selective approach to immunohistochemistry may be necessary  
16 based on tumour morphology and clinical presentation, to avoid the need for a second  
17 biopsy.

18 *[Level of evidence – D.]*

19 The first step is the confirmation of malignancy and then consideration and/or exclusion of  
20 carcinoma, melanoma, lymphoma or sarcoma. Once germ cell tumours and mesothelioma  
21 have been excluded, carcinomas need to be subtyped into squamous, neuroendocrine,  
22 solid organ (including liver, renal, thyroid and adrenal) and adenocarcinoma. The final step  
23 for metastatic carcinoma diagnosis is the determination of the likely primary tumour site,  
24 e.g. in adenocarcinoma these may include lung, breast, pancreas, stomach, colon, ovary,  
25 kidney and prostate.

26 *[Level of evidence – D.]*

27 By definition, microscopic examination of the morphology in a provisional CUP case shows  
28 a pattern that is not associated specifically with a single tumour type (and site, if  
29 appropriate). For undifferentiated tumours, varied patterns may be seen such as small  
30 round blue cell tumour, epithelioid tumour, spindle cell tumour, large cell undifferentiated  
31 cell tumour or a combination of these.<sup>8</sup> In this dataset, for each tumour type (and site, if  
32 appropriate), potential morphologic features are presented with a description of useful  
33 ancillary markers, their staining characteristics and some common diagnostic dilemmas.



1 While immunohistochemistry plays a major role, histochemistry for neutral mucin and  
2 glycogen can be helpful in some cases. We recommend combined Alcian Blue PAS stain,  
3 with and without diastase (AB/PAS+/-D) for this purpose. The demonstration of neutral  
4 mucin can be very valuable in the identification of adenocarcinoma.

5 *[Level of evidence – C.]*

### 6 **1.3 Immunohistochemistry**

7 The process of elimination of primary tumour type in provisional CUP cases requires a  
8 careful pathological workup based usually on immunohistochemistry as well as  
9 morphology.<sup>4</sup> Different IHC markers will be employed depending on the morphology of the  
10 provisional CUP case and the majority of these tumours turn out to be carcinomas. The  
11 exclusion of a 'non-carcinoma' diagnosis is crucial, particularly germ cell tumour, malignant  
12 melanoma, lymphoma, leukaemia and various sarcomas.<sup>22</sup> Depending on morphology, a  
13 primary panel to exclude these tumours from carcinomas is often employed. If this panel  
14 confirms epithelial differentiation, a secondary panel to determine type and likely primary  
15 site is employed.<sup>23,24</sup>

16 *[Level of evidence – D.]*

17 Comprehensive review articles have been published in the last few years describing IHC,  
18 including newer and emerging markers, for a wide range of tumours of unknown origin<sup>22</sup>  
19 and for CUP in particular.<sup>4,23–26</sup> Our dataset describes the strategic approach and these  
20 reviews include more extensive bibliographies for consultation. Other useful sources  
21 include IHC online databases, for example, Elsevier's ImmunoQuery.<sup>27</sup> The use of  
22 cytokeratin profiling, lineage-specific cytoplasmic and membranous markers and lineage-  
23 restricted transcription factors, together with other nuclear markers, allows a definitive  
24 diagnosis of a specific tumour in many cases of provisional CUP.

25 Although generally reproducible and reliable, there are many factors that can contribute to  
26 incorrect IHC results, both false positive and false negative.<sup>8,28</sup> These include pre-analytic  
27 tissue variables, analytic variables affecting the technical performance of  
28 immunohistochemistry and issues around IHC interpretation. Tumour, and thus biomarker,  
29 heterogeneity may be marked especially with small samples and can cause diagnostic  
30 issues. Thresholds for categorising staining as positive or negative in a binary fashion may  
31 vary between biomarkers, corresponding antibodies and previous studies. It is important to  
32 be aware of the staining expected in terms of cell and tissue location and tissue type;  
33 some antibodies may be relatively unfamiliar and yield unexpected staining patterns,

1 potentially contributing to misinterpretation and misclassification. Overall, the  
2 recommendation is to use antibodies in panels, interpret results, especially focal staining  
3 or with less familiar biomarkers, with caution and in clinicopathological context. Discussion  
4 and consultation with colleagues should be considered in most cases, including the  
5 possibility of referral for specialist opinion.

6 *[Level of evidence – D.]*

## 7 **1.4 Molecular testing**

8 Molecular testing in CUP is more expensive and less widely available than IHC and is not  
9 in widespread use in the UK; such profiling is used more commonly in North America and  
10 elsewhere.<sup>20,29–32</sup> Molecular testing in CUP is not currently recommended by NICE for  
11 diagnostic purposes, outside clinical trials and translational studies.<sup>2</sup>

12 With further technical advances, it is likely that molecular testing will play a role in the  
13 future. Such approaches encompass both molecular profiling for enhanced tumour  
14 classification by type and tissue of origin, for example gene expression profiling and  
15 testing for actionable mutations to predict therapeutic benefit.<sup>29–36</sup> Reviews have  
16 suggested that expression and genomic profiling may be equally or more relevant in  
17 guiding personalised precision cancer therapy in CUP than empiric chemotherapy based  
18 on tissue/organ of origin information.<sup>29,37</sup>

19 *[Level of evidence – D.]*

20 Ideally, further comparative studies and demonstration of utilities would be needed and  
21 have been eagerly anticipated to determine which diagnostic approaches could impact the  
22 clinical outcome of patients with CUP.<sup>31,38–40</sup> More recently, these approaches have been  
23 analysed in detail but general adoption of molecular testing in CUP for diagnostic purposes  
24 has not yet become widespread.<sup>6,11,41,42</sup>

25 The National Genomic Test Directory published on 31 October 2022 by NHS England lists  
26 testing for CUP as follows: M226.1 Multi-target NGS panel – structural variant (NTRK1,  
27 NTRK2, NTRK3), M226.3 DPYD hotspot, and M226.4 WGS Germline and Tumour.<sup>43</sup>  
28 Incidence of potentially druggable targets in CUP is relatively low. Application of these  
29 testing modalities is under evaluation but may be helpful in a small proportion of cases.  
30 This is a rapidly evolving area and it is not yet clear what the criteria are for testing,  
31 whether this is targeted or universal, which samples should be tested and who should be  
32 involved in requesting. Discussion with the treating oncologist on a case-by-case basis,

1 preferably in the setting of the CUP MDT is recommended. An update will be published  
2 once there is greater clarity on implementation.

3 The use of liquid biopsy to detect tumour-derived components such as circulating tumour  
4 cells or circulating tumour DNA in blood or other biological fluids is also of interest as this  
5 could help in unveiling druggable alterations using a non-invasive approach.<sup>44</sup> A further  
6 therapeutic area being evaluated is the use of checkpoint inhibitors, such as  
7 pembrolizumab, which have been shown to be of value in several cancer types, but CUP  
8 with deficient mismatch repair appears to be uncommon.<sup>6,45,46</sup>

9 Most oncologists remain keen to explore and support optimisation of existing  
10 histopathological and IHC avenues to designate tumour type.<sup>16</sup>

11 *[Level of evidence – GPP.]*

## 12 **1.5 Use of CUP dataset, worksheet and proforma in practice**

13 Clinical practice varies between hospitals, but this document introduces a standardisation  
14 of the pathological approach to the diagnosis of CUP. Completion of the CUP proforma is  
15 only required for confirmed CUP. The CUP worksheet is designed to support the  
16 evaluation of provisional CUP. If, during evaluation, it becomes evident that the tumour  
17 can be classified as a specific type or site, for which another dataset exists, that alternative  
18 dataset should be completed, e.g. sarcoma or colorectal carcinoma (see section 5.4).<sup>47</sup>

19 Thus, the dataset for confirmed CUP essentially comprises a list of negative investigations  
20 undertaken to try to identify a primary site. It should be recognised that confirmed CUP is a  
21 relatively rare histological diagnosis when all clinical imaging and pathological parameters  
22 have been fully explored; many ‘provisional’ CUP cases will eventually be considered and  
23 treated as a specific tumour type. Because of this, the authors recommend that 2  
24 consultant-equivalent histopathologists should be involved in the final allocation of the  
25 diagnosis of confirmed CUP.

26 *[Level of evidence – GPP.]*

27 In the UK, biopsies taken for provisional CUP diagnosis are reported mainly in general  
28 pathology departments that will normally include 1 or more histopathologists who  
29 participate in a CUP MDT. Referral to another pathology department may be necessary to  
30 access additional diagnostic techniques that may not be available in all laboratories.  
31 Diagnosis of CUP is especially important in patients of good performance status who are  
32 likely to be better able to tolerate high intensity therapies.

1 *[Level of evidence – GPP.]*

## 2 **1.6 MDT working and standardised reporting**

3 Since the introduction of peer review standards for CUP and the publication of the NICE  
4 guidance on CUP in 2010, hospitals in England and Wales are required to have a  
5 multidisciplinary approach to CUP/MUO diagnosis and a CUP/MUO MDT.<sup>2,3</sup> While some  
6 hospitals have established standalone CUP/MUO MDT meetings, often linked to acute  
7 oncology services, many units have arranged combined MDT meetings with lung, upper  
8 gastrointestinal cancer or hepato-pancreatico-biliary MDTs, for ease of organisation; this in  
9 turn means that the pathologists experienced in CUP often practice in one of these  
10 subspecialties.

11 Most diagnoses of CUP/MUO are reported on biopsy specimens rather than excisions and  
12 can come from a wide range of sites, requiring a different approach to diagnosis when  
13 compared with conventional site-specific datasets. There is a significant challenge in  
14 definitively excluding identifiable tumour types or potential sites of origin, which may be  
15 crucial to therapy in this group of patients who have very poor clinical outcomes in the  
16 majority of cases.<sup>17</sup> However, identification of specific patterns of differentiation or  
17 uncovering a ‘cryptic’ site of origin may enable clinicians to optimise therapy and provide  
18 meaningful prognostic information to patients and their relatives and carers.<sup>48,49</sup> Integration  
19 of results with other pathology tests, particularly serum tumour markers, is often vital in  
20 making the appropriate diagnosis. One third of advanced malignant tumours present with  
21 metastases at the time of diagnosis and the use of improved imaging techniques is crucial  
22 to identifying primary sites in some cases.

23 *[Level of evidence – D.]*

24 Once the diagnosis of provisional CUP has been reached by the pathologist, it is  
25 recommended that the case is discussed in a CUP or CUP-related MDT meeting with the  
26 treating oncologist to ensure that no additional imaging or tumour marker information has  
27 emerged during the diagnostic process in histology.<sup>2,3</sup> Only then should a diagnosis of  
28 confirmed CUP be provided by the pathologist. The MDT is particularly important in the  
29 diagnosis of CUP, as detailed discussion between pathologists, oncologists, radiologists  
30 and oncology nurses is essential to classify these tumours accurately and offer patients  
31 the best care and treatment options.<sup>50</sup>

32 *[Level of evidence – D.]*

1 Standardised cancer reporting and MDT collaborative working help to reduce the risk of  
2 histological misdiagnosis or misinterpretation of histopathology reports, and ensure that  
3 clinicians have all of the relevant pathological information required for appropriate tumour  
4 management and prognosis.<sup>51</sup> There is strong evidence of the value of cancer MDTs in  
5 improving decision making, particularly in complex cases such as CUP. However,  
6 increasing demands have led to calls for improved practices to streamline these meetings,  
7 in order to ensure their efficiency and effectiveness.<sup>52</sup> Collection of standardised cancer-  
8 specific data also provides information for healthcare providers and epidemiologists and  
9 facilitates international benchmarking and research. Information is often retrieved on the  
10 basis of coding and therefore it is important that this is accurate and standardised (see  
11 Appendix A).

12 *[Level of evidence – D.]*

### 13 **1.7 Target users of this guideline**

14 The target primary users of the dataset are trainee and consultant cellular pathologists  
15 and, on their behalf, the suppliers of IT products to laboratories. The secondary users are  
16 surgeons, physicians, oncologists and cancer registries and related organisations.

## 17 **2 Clinical information required on the specimen** 18 **request form**

19 In addition to demographic information about the patient and details of destination of the  
20 report, several items of clinical information including relevant medical history, particularly  
21 previous diagnosis of any malignant disease, family history of malignant disease and  
22 occupational exposure to carcinogens, can help the pathologist in the handling and  
23 reporting of specimens of presumed metastatic tumour. These should be made available  
24 to the pathologist on the specimen request form. It is good practice to include clinical  
25 information obtained in the pathology report.

26 *[Level of evidence – D.]*

27 For all biopsies, the precise anatomical location(s) should be given to help in  
28 interpretation. Knowledge of the distribution of disease mainly drawn from CT, MRI or  
29 other imaging is very helpful and should be available. Serum tumour marker status should  
30 be made available. In practice, these results are often only available after initial reporting

1 of the case and should be integrated into the report when relevant. This often occurs at or  
2 following the MDT meeting at which the patient is discussed in detail.

3 *[Level of evidence – D.]*

4 Details of current and previous therapy can aid morphological interpretation as well as  
5 inform the pathologist.

6 *[Level of evidence – D.]*

### 7 **3 Preparation of specimens before dissection**

8 Specimen types from which a diagnosis of CUP/MUO may be made can be submitted  
9 from almost any anatomic site and range from small biopsies to large resections. In most  
10 cases, patients have evidence of widespread disease at the time of biopsy but in some it  
11 will be an incidental finding or an unexpected diagnosis following resection for a presumed  
12 primary of known origin. Biopsies from lymph node, liver and lung are most frequently  
13 encountered.<sup>53</sup> Other common sites of metastatic disease include brain, bone/bone  
14 marrow, pleura or peritoneum, adrenal gland and skin, but any site may be involved and  
15 biopsied.

16 Definitive diagnosis of CUP/MUO on cytological preparations can be difficult because the  
17 limited material might not allow the full range of ancillary techniques. The likelihood of  
18 CUP/MUO should be communicated to the clinical team managing the patient and a tissue  
19 biopsy requested where appropriate.

20 *[Level of evidence – GPP.]*

#### 21 **3.1 Request forms**

22 Appropriate labelling of the request form and containers must be observed by the  
23 requesting clinical team to avoid delays in the registration ('booking in') of specimens.

#### 24 **3.2 Tissue (biopsy and resection) specimens and fixation**

25 The majority of histological specimens are received in 10% buffered formalin. Adequate  
26 fixation requires five to ten times the volume of formalin compared to the size of the  
27 specimen and the requestor must select a suitable size of container. Adequate fixation is  
28 essential for good preservation of morphology, which facilitates morphological diagnosis,  
29 immunohistochemistry and other ancillary techniques. However, over-fixation can lead to  
30 changes in IHC staining profile and should be avoided. If fresh tissue is available for

1 research or bio-banking, this should be collected according to agreed protocols and under  
2 the guidance of the pathologist. Detailed protocols for research and tissue banking,  
3 including ethical and consent issues, are beyond the scope of this document. As a general  
4 principle, fresh tissue banking protocols should be designed such that diagnosis is not  
5 compromised; if this is likely in a given case, then tissue banking should not occur and the  
6 reasons should be recorded.

7 *[Level of evidence – D.]*

8 Once received in the laboratory, large specimens should be incised promptly by a  
9 pathologist or trained biomedical scientist/advanced practitioner to ensure good formalin  
10 penetration. Small specimens that only require tissue transfer may be submitted directly  
11 for processing by a biomedical scientist.

12 *[Level of evidence – D.]*

### 13 **3.3 Cytology specimens**

14 Cytological specimens are generally direct smears or fluids processed as cell blocks or  
15 cytopins and stained with the Papanicolaou (Pap) stain. Pap-stained liquid-based  
16 cytology (LBC) preparations may also be used and unstained LBC slides or sections of cell  
17 clots or cell blocks prepared from LBC specimens can be used for immunohistochemistry,  
18 in situ hybridisation, polymerase chain reaction or gene expression profiling if required.<sup>54,55</sup>

19 *[Level of evidence – D.]*

## 20 **4 Specimen handling and block selection**

### 21 **4.1 Biopsies**

22 The number of biopsies and the largest dimension of each piece should be recorded. In  
23 cases where there is a likely diagnosis of malignancy, biopsies may be separated into  
24 multiple cassettes to maximise tissue available. To enable optimal handling of scarce  
25 tissue, it is helpful to know in advance that the biopsy is from a provisional CUP case, from  
26 the clinical history provided by the referring clinician or from previous MDT discussions.

27 *[Level of evidence – D.]*

28 Thereafter, alternative approaches can be employed. One approach is to examine a single  
29 microscopic level (so-called 'early H&E') with minimum trimming for initial assessment,  
30 which would guide the subsequent number of IHC blank/spare sections required. An

1 alternative approach is to examine the tissue at 3 microscopic levels while retaining all or  
2 most of the resulting unstained sections on coated slides for later use. Therefore, the  
3 tissue biopsy is not wasted or 'cut through' before all appropriate IHC markers (or other  
4 ancillary tests including molecular studies) can be employed. If only necrotic material is  
5 seen, then deeper levels must be examined until the block is exhausted before reporting  
6 the biopsy as 'non-diagnostic'.

7 *[Level of evidence – GPP.]*

## 8 **4.2 Larger resection specimens**

9 These will be dealt with in accordance with the dissection guidance appropriate to the  
10 organ type, as listed in other cancer datasets. As the diagnosis of MUO/CUP is generally  
11 only known after examination of tissue slides from the resected organ, optimal fixation is  
12 particularly important in these tumours as immunohistochemistry is vital for correct  
13 categorisation.

14 *[Level of evidence – D.]*

# 15 **5 Evaluation of potential CUP specimens by** 16 **morphology and immunohistochemistry (see** 17 **Appendices C–E)**

18 A description of the tumour microscopic appearance is important in the evaluation of any  
19 tumour. Following morphological evaluation of potential CUP, immunohistochemistry is  
20 required to exclude other diagnoses. As the range of IHC markers that may be necessary  
21 runs into the hundreds, a checklist of all IHC antibodies currently available would not be  
22 helpful, although minimum panels exist in current guidelines.<sup>2,4,16,18,22–26,56,57</sup> The dataset  
23 therefore requires the pathologist to declare which techniques they have undertaken  
24 without being prescriptive and serves as a synoptic method of providing information to the  
25 treating oncologist.

26 *[Level of evidence – D.]*

## 27 **5.1 Workup of CUP/MUO specimens**

28 The diagnostic process on a tissue or cell specimen from a patient with metastasis of (at  
29 least initially) unknown origin can be worked through systematically.<sup>8,58</sup> It will already have



1 been established by the pathologist using standard diagnostic criteria that a lesion is  
2 present and that it is a tumour, presumed to be malignant. Thereafter, the first step is to  
3 consider the broad tumour type: carcinoma, germ cell tumour, melanoma, lymphoma or  
4 sarcoma. If the tumour is carcinoma, then the second step is to consider its subtype:  
5 squamous or urothelial, neuroendocrine, solid organ or adenocarcinoma. If the tumour is  
6 adenocarcinoma, then the third step is to consider the possible site of origin of the tumour.  
7 Each step may be accomplished using morphology, with or without IHC.<sup>58</sup> This approach is  
8 summarised as a flowchart in Figure 1 and is reflected in the stepwise structure of the  
9 worksheet accompanying the dataset form (see Appendix E).

10 *[Level of evidence – D.]*

## 11 **5.2 Specific approach to diagnosis: broad tumour type**

### 12 **5.2.1 Broad tumour type: morphological description**

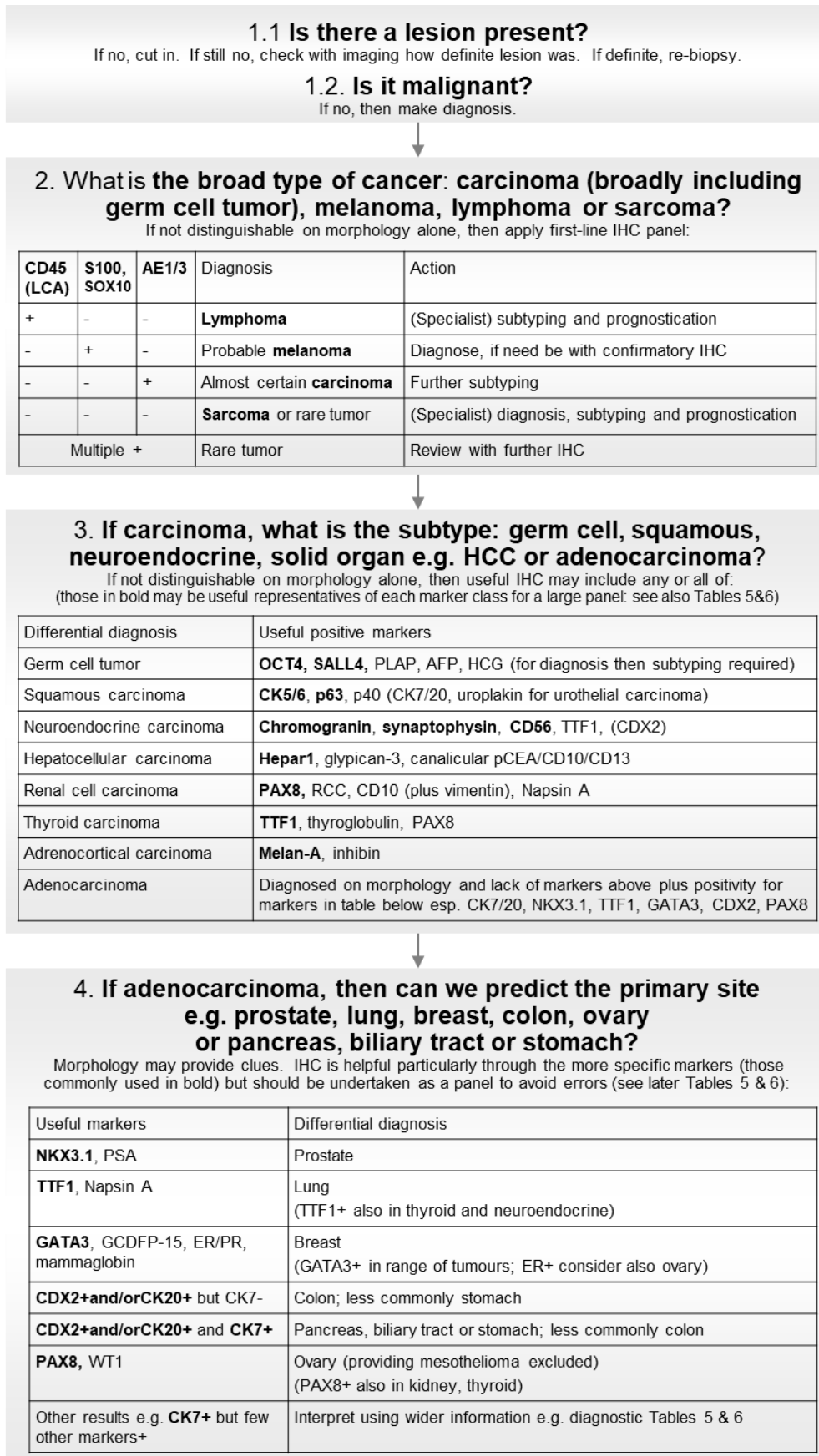
13 First, the likely broad tumour type will be considered: carcinoma (including germ cell  
14 tumour), melanoma, lymphoma or sarcoma. There are at least 4 common morphological  
15 patterns of tumour type encountered in MUO/CUP:<sup>8</sup>

- 16 • epithelioid tumours of cohesive cells lying in sheets or glands, usually in stroma, and  
17 with cells that are often round, columnar or cuboidal
- 18 • sarcomatoid tumours comprise cohesive cells in sheets and cells are often spindle;  
19 some tumours show both patterns and may be called 'biphasic'
- 20 • 'small blue cell' tumours comprise sheets and islands of relatively small, often  
21 cohesive, cells with dark nuclei and often apoptosis
- 22 • undifferentiated and/or pleomorphic tumours lack classic differentiation and may  
23 display bizarre cells.

24 Epithelioid tumours are mostly carcinomas but many melanomas and, rarely, sarcomas  
25 (especially gastrointestinal stromal tumours) and lymphomas show epithelioid morphology.  
26 Sarcomatoid tumours are mostly sarcomas or melanomas; a few carcinomas, especially  
27 breast and renal, and mesotheliomas can show sarcomatoid morphology. Carcinomas,  
28 sarcomas and melanomas (and mesotheliomas) can all show a biphasic pattern. Perhaps  
29 the most common morphologies encountered in MUO/CUP are classic adenocarcinomas  
30 without specific features of primary site and undifferentiated tumours.<sup>8</sup>

31 *[Level of evidence – D.]*

- 1 **Figure 1: Flowchart for the pathological approach to CUP/MUO, based on Oien KA.**  
 2 **Pathological evaluation of unknown primary cancer. *Semin Oncol* 2009;36:8–37**  
 3 **(with permission from Elsevier)<sup>8</sup> and updated from the literature.<sup>4,22–26,57</sup>**



4

1 **5.2.2 Broad tumour type: IHC studies**

2 If the type of tumour cannot be definitely diagnosed on morphology alone, then a first-line  
3 IHC panel can be applied, such as that shown in Table 2.

4 **Table 2: Basic initial IHC panel for broad cancer types. Based on the literature.**<sup>4,8,22-</sup>  
5 <sup>26,57</sup>

Tumour type	Epithelial marker e.g. pan-cytokeratin AE1/3	Melanocytic marker e.g. S100, SOX10	Lymphoid marker e.g. CD45 (LCA)
Carcinoma	Positive	Negative, usually	Negative
Melanoma	Negative, usually	Positive	Negative
Lymphoma	Negative, usually	Negative	Positive
Sarcoma	Negative, usually	Negative in most but positive in nerve sheath tumours, etc.	Negative

6

7 A first-line IHC panel would generally include:

- 8 • an epithelial marker, demonstrated alone or in combination with others e.g. broad-  
9 spectrum anti-cytokeratin reagents such as AE1/3, MNF116, CAM5.2, EMA and  
10 CK7/20
- 11 • melanocytic markers e.g. S100, SOX10, Melan-A and HMB45<sup>25,26</sup>
- 12 • a lymphoid marker e.g. CD45 (LCA).<sup>8,22</sup>

13 *[Level of evidence – C.]*

14 An extended first-line panel (especially for large cell undifferentiated tumours and/or where  
15 initial markers are negative) could also include:

- 16 • multiple broad-spectrum anti-cytokeratins or other epithelial markers, for example  
17 AE1/3 plus MNF116 or CAM5.2, since some carcinomas (especially hepatocellular)  
18 may be negative with AE1/3
- 19 • CD138 for plasmablastic tumours and CD30 and CD246 (ALK) for anaplastic large cell  
20 lymphoma, which are often negative with CD45 (LCA). It should be noted that some  
21 carcinomas may express CD138 and/or CD304
- 22 • antibodies reactive with PLAP, OCT3/4 and SALL4 for germ cell tumours, where  
23 OCT3/4 is now standard for seminoma and embryonal carcinoma and SALL4 is a

1 newer 'pan-germ cell marker' that unlike OCT3/4 is also positive in yolk sac  
 2 tumours.<sup>22,25,59</sup>

3 *[Level of evidence – D.]*

4 Because sarcoma rarely presents as metastatic CUP, sarcoma markers are generally not  
 5 used in a first-line IHC panel unless morphology is suggestive, i.e. a spindle cell tumour (or  
 6 minority of small round blue cell tumours), when vimentin, desmin, smooth muscle actin,  
 7 caldesmon, CD34, CD31, S100 and EMA may be useful markers.<sup>8,22</sup> It should be noted  
 8 that vimentin positivity is relatively non-specific and can be seen in a wide variety of non-  
 9 sarcomatous malignancies.

10 *[Level of evidence – D.]*

11 If the tumour is convincingly negative with the first-line markers for carcinoma, melanoma  
 12 and lymphoma, then the diagnosis of sarcoma may also be considered (see Table 3),  
 13 along with rarer CUP tumours including the CD45 (LCA)-negative haematolymphoid  
 14 tumours, germ cell tumours (which may be CK negative, with the markers described  
 15 above) and poorly differentiated carcinomas (considered later in the carcinoma section).

16 **Table 3: Supplementary IHC markers for use in lymphoma, sarcoma and small**  
 17 **round blue cell tumour.**

<b>Lymphoma*</b>	
CD246 (ALK) and CD30	To exclude anaplastic large cell lymphoma
CD15, CD43, CD68 and myeloperoxidase	To exclude myeloid sarcomas Please see lymphoma dataset for specific information about lymphoma workup <sup>60</sup>
CD138	To exclude plasmablastic tumours
<b>Sarcoma</b>	
Vimentin, alpha-smooth muscle actin, desmin, myoD1, myogenin, S100, CD31, CD34, CD30, bcl2, MNF116, EMA, c-kit and CD99	To exclude sarcoma Some sarcomas will also stain with S100 or focally with epithelial markers Please see sarcoma dataset for specific information about sarcoma workup <sup>47</sup>
<b>Small round blue cell tumour</b>	
Cytokeratins (e.g. antibody CAM5.2) and CD56	To exclude small cell carcinoma
CD45 (LCA)	To exclude lymphomas and leukaemias

Desmin, myoD1 and myogenin	To exclude rhabdomyosarcoma
CD99, FLI1 and Pax5	To exclude Ewing's sarcoma and primitive neuroectodermal tumour
EMA and cytokeratins (e.g. antibody MNF116)	To exclude synovial sarcoma
Chromogranin, synaptophysin, GFAP and S100 protein	To exclude endocrine and neurogenic tumours including olfactory neuroblastoma
<p>*The subtyping of lymphomas should be undertaken within a designated regional Haematological Malignancy Diagnostic Service, in line with the NICE Improving Outcomes Guidance (IOG); once lymphoma is indicated, e.g. by demonstration of CD45 expression, the tissue should be referred to such a service.<sup>61</sup> The further workup at such a centre might include: B-cell markers CD20 and CD79a; a T-cell marker CD2 or CD3; further lymphocyte subset markers, CD4, CD5, CD7, CD8 and CD10; activation marker CD30; CD246 (ALK); B-cell lymphoma proteins bcl-2 and bcl-6; TdT (based on literature).<sup>22</sup> Full guidance is provided in the College's <i>Standards for specialist laboratory integration and Dataset for the histopathological reporting of lymphomas</i>.<sup>60</sup></p>	

1

2 [Level of evidence – D.]

3 **Sarcoma**

4 Sarcomas have a wide range of histological appearances but generally their cells are  
5 cohesive and lie in sheets, with an elongated spindle shape. The College's sarcoma  
6 dataset provides detailed information.<sup>47</sup> As for lymphomas, NICE guidance anticipates that  
7 all suspected soft tissue sarcomas will undergo diagnostic review within a specialist  
8 sarcoma service.<sup>62</sup> In terms of CUP and sarcoma, there are three main diagnostic issues.

9 First, a subset of carcinomas and melanomas may take on a sarcomatoid morphology.  
10 Metastatic sarcomatoid carcinoma or melanoma is much more common in CUP than  
11 metastatic sarcoma. Such tumours need to be treated as carcinoma or melanoma, and  
12 therefore their correct identification is important. Sarcomatoid differentiation is particularly  
13 common in squamous tumours, in carcinomas from the breast and genitourinary system  
14 (especially kidney and bladder), and in germ cell tumours.<sup>63</sup> It is not uncommon in a  
15 presumed CUP biopsy to find a prior history of nephrectomy, mastectomy or even  
16 orchidectomy 10 or more years previously so a full past medical history is vital.

17 [Level of evidence – D.]

1 Second, metastasis of carcinoma, melanoma or lymphoma to soft tissue and first  
2 presenting there, mimicking a primary soft tissue sarcoma, is increasingly common.<sup>64</sup>  
3 Third, we have the relatively rare first presentation of sarcoma as a metastatic deposit.

4 The first and second scenarios above should be dealt with by the first-line IHC panel  
5 already described. Carcinomas will generally be widely positive with the pan-cytokeratin  
6 AE1/3, in the spindled cells as well as any epithelioid cells; this differs from sarcomas in  
7 which cytokeratin staining, if any, is generally limited to epithelioid cells. Melanomas will  
8 generally be widely positive with S100 or SOX10.<sup>4,26</sup> Some sarcomas, particularly of the  
9 peripheral nerve, are also S100 positive but the staining is usually more focal and weaker.  
10 Lymphomas will generally be CD45 (LCA) positive. If there is any doubt, then the second  
11 IHC panel can be undertaken, for sarcoma, carcinoma or both as appropriate.

12 If a sarcoma is suspected or diagnosed, referral to a specialist sarcoma unit is  
13 recommended with discussion in the sarcoma MDT meeting. Sarcoma diagnosis generally  
14 requires expert pathology review and may require molecular confirmation. Full guidance is  
15 provided in the College's *Dataset for the histopathological reporting of soft tissue*  
16 *sarcomas*.<sup>47</sup>

17 *[Level of evidence – D.]*

## 18 **Lymphoma**

19 Lymphoma is often easily identified on the basis of morphology and IHC. The lymphoma  
20 dataset provides detailed information.<sup>60</sup> In the MUO/CUP setting, the most likely  
21 lymphomas to be considered in the differential diagnosis are anaplastic large cell  
22 lymphoma (ALCL) or anaplastic forms of plasma cell neoplasm. Relevant IHC is listed in  
23 Tables 2 and 3. Another challenging diagnosis is tissue-based acute myeloid  
24 leukaemia/granulocytic sarcoma/chloroma. With regard to the CUP diagnostic dilemmas, it  
25 should be noted that haematolymphoid tumours such as ALCL which resemble carcinoma,  
26 can be negative for CD45 (LCA) and may express EMA and/or cytokeratin. ALCL is  
27 positive for CD30, and some but not all cases are positive for CD246 (ALK), which is a  
28 specific marker when present. CD30 is a marker of activated lymphocytes and is  
29 expressed in many lymphoid lineages.<sup>65</sup> CD30 is also expressed in non-lymphoid  
30 malignancies including some carcinomas. Myeloid sarcomas (tissue-based acute myeloid  
31 leukaemias) are usually positive with a range of granulocytic markers including CD15,  
32 CD33, CD43, CD68 and myeloperoxidase.<sup>66</sup>

33 *[Level of evidence – D.]*

1 This discussion has largely excluded Hodgkin lymphoma, which presents rarely as CUP  
2 but may enter the differential diagnosis of lymph node biopsies. The morphology of non-  
3 Hodgkin lymphoma is generally characteristically lymphoid. Diagnostic difficulty is usually  
4 between Hodgkin lymphoma and other types of lymphoma or benign processes, not other  
5 types of cancer. If necessary, IHC for CD30, CD15, MUM1, PAX5 and EBV-LMP can be  
6 helpful in diagnosis.

7 *[Level of evidence – GPP.]*

### 8 **Small round blue cell tumour**

9 In adult CUP, the common differential diagnoses of small round blue cell tumours include  
10 leukaemia/lymphoma, small cell neuroendocrine carcinoma and (basaloid) squamous  
11 carcinoma. Other rarer possibilities include Merkel cell tumour and sarcomas including  
12 desmoplastic small round cell tumours. Relevant IHC is listed in Table 3.<sup>22</sup> Although small  
13 round blue cell tumours may be lymphomas, most low-grade lymphomas are diagnosable  
14 as probable lymphoma on morphology. While the same may be true of high-grade  
15 lymphomas, some may appear epithelioid. Undifferentiated and/or pleomorphic tumours  
16 can arise from any of the broad tumour types.

### 17 **Melanoma**

18 At this step, always consider melanoma, especially if the tumour contains brown granular  
19 pigment. If much pigment is present, consider an alternative (non-DAB, i.e. non-brown)  
20 chromogen for IHC. The relevant IHC is listed in Table 2.

21 *[Level of evidence – D.]*

22 It is worth being aware of more unusual clinical scenarios or metastatic sites that may  
23 suggest specific entities, e.g. germ cell tumours in young males and/or in midline  
24 mediastinal or abdominal tumours.

25 *[Level of evidence – C.]*

## 26 **5.3 Specific approach to diagnosis: carcinoma type**

### 27 **5.3.1 Carcinoma type: morphological description**

28 Once it has been decided that the specimen contains a carcinoma then the next question  
29 is what is the broad carcinoma subtype: squamous tumours, which for our broad purposes  
30 may include basal tumours, plus urothelial carcinomas; adenocarcinomas; carcinomas of  
31 solid organs, which are sometimes grouped with adenocarcinomas, arising from liver,

1 kidney, thyroid and adrenal glands; neuroendocrine tumours/carcinomas, both well  
2 differentiated and poorly differentiated; or germ cell tumours, which are distinct from  
3 carcinomas but which they morphologically may resemble.<sup>8</sup>

4 Squamous carcinomas comprise cohesive cells lying in sheets or islands; the cells are  
5 usually large and often round. Adenocarcinomas comprise cohesive cells lying mainly as  
6 glands, ducts or islands, usually within stroma; the cells are usually columnar or cuboidal.  
7 The solid organ carcinoma pattern comprises cohesive cells in sheets, cords and/or acini,  
8 often without much stroma; the cells are often round. A similar pattern may be seen in  
9 well-differentiated neuroendocrine tumours/carcinomas, with cohesive cells lying in sheets  
10 or islands; its cells are usually round and uniform and the tumour is often highly vascular.  
11 Small blue cell tumours comprise sheets and islands of relatively small, often cohesive,  
12 cells with dark nuclei and often apoptosis. Undifferentiated and/or pleomorphic epithelioid  
13 tumours lack classic differentiation and may display bizarre cells. Some tumours show  
14 more than 1 epithelioid morphological pattern and some may be both epithelioid and  
15 sarcomatoid ('biphasic').

16 These morphologies relate to the carcinoma subtypes as follows. Squamoid morphology is  
17 seen in squamous carcinomas but also in urothelial/transitional carcinomas, some basal  
18 cell carcinomas and some adenocarcinomas. Obviously, more differentiated squamous  
19 tumours may show keratin 'pearls' and intercellular 'prickles'. Adenocarcinomas show their  
20 classic glandular pattern, but similar morphology may be found in some solid organ  
21 carcinomas, germ cell tumours and mesotheliomas. The solid organ morphology is seen in  
22 hepatocellular, renal, thyroid and adrenal carcinomas, as well as in some well-  
23 differentiated neuroendocrine tumours/carcinomas. Solid organ carcinomas may resemble  
24 the corresponding normal organ, e.g. abundant pale 'clear' cytoplasm in renal cancer,  
25 follicular structures and secretions in thyroid carcinoma. The undifferentiated and/or  
26 pleomorphic morphology may be seen with any carcinoma subtype; it is worth considering  
27 and excluding germ cell tumour in particular.

28 *[Level of evidence – D.]*

### 29 **5.3.2 Carcinoma type: IHC studies**

30 If the carcinoma subtype cannot be definitely diagnosed on morphology alone, then IHC  
31 panels may be applied, such as those shown in Tables 4 and 5.<sup>4,8,22–26,57</sup> The markers  
32 used would be tailored to the morphological pattern.



1 For probable adenocarcinomas, classified according to their morphology, proceed to the  
2 next section of considering its likely primary site.<sup>2,4,8,22–26,28,29,57,67</sup>

3 For squamoid tumours, CK5/6, p63 and p40 are usually positive in squamous and  
4 urothelial carcinomas.<sup>8,23,24,59</sup> Urothelial carcinomas are usually also positive with CK7 and  
5 CK20 and urothelial markers e.g. GATA3, uroplakin. Squamous carcinomas are usually  
6 CK20 negative but CK7 staining is variable. CK5/6 and p63 are absent from almost all  
7 solid organ carcinomas and from most adenocarcinomas; exceptions include basaloid  
8 breast carcinoma. CK5/6 may be positive in other tumour types, e.g. mesothelioma. For  
9 the primary site of squamous carcinomas, immunohistochemistry is not specific but  
10 EBVLMP may be positive in nasopharyngeal carcinoma and HPV and p16 may be positive  
11 in oropharyngeal and genitourinary tumours.<sup>67,68</sup>

12 *[Level of evidence – D.]*

13 For possible solid organ (liver, kidney, thyroid and adrenal) carcinomas, many useful IHC  
14 markers relate to organ of origin.<sup>4,8,23–25</sup> Hepatocellular carcinoma is often, but not always,  
15 positive with Hep Par-1; a small proportion of adenocarcinomas (especially so-called  
16 ‘hepatoid’) may also stain with Hep Par-1. Glypican-3 is similarly often positive in  
17 hepatocellular carcinoma. Demonstration of a canalicular rather than luminal pattern of  
18 staining, for example with CD10 and polyclonal CEA, may also help in the diagnosis of  
19 hepatocellular carcinoma. In renal cell carcinoma, PAX8 is generally positive, although it is  
20 also positive in other tumour types including gynaecological and thyroid. Renal cell  
21 carcinoma (RCC) marker is often, but not always, positive in RCC; staining in other tumour  
22 types is rare. Dual luminal CD10 and vimentin staining is considered typical of RCC. Note  
23 that renal cell carcinomas are often also positive with Napsin A. Adrenocortical carcinoma  
24 is usually negative for cytokeratins and positive with Melan-A, synaptophysin and inhibin;  
25 obviously Melan-A is also positive in melanomas. Thyroid carcinomas are usually positive  
26 with TTF1, thyroglobulin and PAX8. Note that TTF1 is also generally positive in lung  
27 adenocarcinomas and in small cell carcinomas from any site. Solid organ (liver, kidney,  
28 thyroid and adrenal) carcinomas may or may not show CK7 positivity, but are usually  
29 negative for CK20 and CK5.

30 *[Level of evidence – C.]*

31

32

1 **Table 4: Expression of CK7 and CK20 in carcinomas and related tumours. Based on**  
 2 **the literature.**<sup>4,8,22–26,57</sup>

	<b>CK7 positive</b>	<b>CK7 negative</b>
<b>CK20 positive</b>	<b>Gastrointestinal adenocarcinomas and urothelial/transitional cell carcinoma</b> Pancreas and biliary tract (one third) Stomach (one quarter) Ovary, mucinous: but many of these likely to be metastatic from gut Urothelial carcinoma (two thirds)	<b>Gastrointestinal adenocarcinomas</b> Colorectum Stomach (one third) Neuroendocrine tumour/carcinoma of Merkel cell type, poorly differentiated
<b>CK20 negative</b>	<b>Many adenocarcinomas</b> Breast Lung adenocarcinoma Ovary, serous and endometrioid Pancreas and biliary tract (two thirds) Stomach (one sixth) Endometrium Salivary tumours Thyroid tumours Urothelial carcinoma (one third) Neuroendocrine, poorly differentiated: small cell carcinoma (one quarter) Malignant mesothelioma (two thirds)	<b>Prostatic and other adenocarcinomas plus solid organ, squamous and most neuroendocrine tumours/carcinomas</b> Prostate Stomach (one sixth) Squamous carcinoma Germ cell tumour Hepatocellular carcinoma Renal clear cell carcinoma Adrenocortical carcinoma Neuroendocrine, poorly differentiated: small cell carcinoma (three quarters) Malignant mesothelioma (one third)

3

4 *[Level of evidence – C.]*

5 For possible well-differentiated neuroendocrine tumours/carcinomas, useful general IHC  
 6 markers include synaptophysin and chromogranin; strong positivity with these markers is  
 7 usually seen only in endocrine tumours/carcinomas.<sup>8,24</sup> Other neuroendocrine markers  
 8 including CD56 and NSE are generally less specific and may stain other tumour types.  
 9 Well-differentiated neuroendocrine tumours/carcinomas may also show staining with  
 10 markers specific to their site of origin, e.g. TTF1 for lung, CDX2 for gastrointestinal and  
 11 SATB2 for lower gastrointestinal.<sup>69</sup> In poorly differentiated endocrine tumours/carcinomas  
 12 (small cell carcinomas), TTF1 staining is not site specific. Many neuroendocrine  
 13 tumours/carcinomas (including undifferentiated small cell carcinoma) will exhibit  
 14 paranuclear dot-like cytokeratin staining.

1 [Level of evidence – D.]

2 For small blue cell tumours in adults, which are positive with epithelial markers on IHC, the  
3 differential diagnosis includes the following: basaloid squamous cancer, which stains  
4 positively with CK5 and p63 whereas undifferentiated small cell carcinoma may stain with  
5 endocrine markers including synaptophysin, chromogranin and CD56, as well as TTF1;  
6 and Merkel cell carcinoma, which typically stains positively with CK20 rather than CK7, in  
7 contrast to other small cell neuroendocrine carcinomas.

8 [Level of evidence – C.]

9 For undifferentiated and/or pleomorphic carcinoma, it is worth considering whether germ  
10 cell tumour is a possibility.<sup>8,24</sup> If so, potential markers include OCT3/4, which is positive in  
11 seminoma and embryonal carcinoma. SALL4 is a newer marker for multiple germ cell  
12 tumours, which unlike OCT3/4, is also positive in yolk sac tumours, as well as PLAP, AFP,  
13 glypican-3 and HCG; other carcinomas would only rarely be positive with these markers  
14 e.g. AFP and glypican-3 in hepatocellular carcinoma.<sup>22,25</sup>

15 [Level of evidence – D.]

16 **Table 5: IHC markers commonly used for subtyping of carcinomas. Based on the**  
17 **literature.**<sup>6,8,9,22–24,53,65</sup>

	<b>Marker often used</b>	<b>Comments on sensitivity and specificity</b>
<b>Adenocarcinoma</b>	<b>CK7, CK20, NKX3.1, TTF1, GATA3, CDX2, PAX8</b> and other adenocarcinoma markers	
<b>Squamous carcinoma</b>	<b>CK5, CK5/6, p40, p63, CK34 beta E12 (CK903)</b>	80–90% sensitive for squamous and basal carcinomas and for urothelial carcinomas (p63); also seen in a minority of adenocarcinomas especially breast (basal phenotype), thus moderately specific
<b>Urothelial carcinoma</b>	p40, p63, CK7, CK20, GATA3, uroplakin	
<b>Neuroendocrine tumour/carcinoma</b>	<b>Chromogranin, CD56, synaptophysin; TTF1</b> in some; paranuclear dot-like cytokeratin staining	TTF1 expressed in most poorly differentiated neuroendocrine carcinomas (small cell) and in some well-differentiated neuroendocrine tumours/carcinomas of lung origin

		(c.f. CDX2 in those of intestinal origin)
<b>Solid carcinoma: renal</b>	<b>PAX8</b> , RCC, luminal membranous CD10 (plus vimentin), Napsin A	RCC 55–86% sensitive
<b>Solid carcinoma: liver</b>	<b>Hep Par-1</b> , canalicular CD10 or pCEA, glypican-3	Hep Par-1: 55–99% sensitive; moderately specific (may stain some adenocarcinomas)
<b>Solid carcinoma: thyroid</b>	<b>TTF1</b> , thyroglobulin, PAX8	
<b>Solid carcinoma: adrenal</b>	<b>Melan-A</b> , inhibin	50–100% sensitive
<b>Germ cell tumour</b>	<b>OCT3/4, SALL4, PLAP, HCG, AFP, glypican-3</b>	OCT4 nearly 100% sensitive and 100% specific for embryonal carcinoma and seminoma; SALL4; PLAP highly sensitive and moderately specific; AFP and glypican 3 in yolk sac tumour; HCG in choriocarcinoma
<b>Mesothelioma</b>	<b>Calretinin, D2-40, CK5, CK7, WT1</b>	BerEP4 and MOC-31 negative

1

2 *[Level of evidence – D.]*

3 If a germ cell tumour has been excluded or is unlikely, then a broad panel to establish  
4 carcinoma subtype may be useful. Again, this can be tailored to the morphological pattern  
5 but a set of markers covering the most common tumours could include CK5, CK7, CK20,  
6 synaptophysin, Hep Par-1, PAX8 and/or TTF1 (Table 5). It is worth also considering and  
7 excluding mesothelioma.<sup>22</sup>

8 *[Level of evidence – D.]*

9 If the carcinoma subtype is found to be a specific solid organ (liver, kidney, thyroid and  
10 adrenal) carcinoma, well-differentiated neuroendocrine tumour/carcinoma, squamous  
11 carcinoma with likely primary site (e.g. head and neck) or urothelial carcinoma, for further  
12 reporting guidance please move on to and complete the relevant tumour-specific dataset.  
13 Relevant common scenarios include the following:

- 14 • metastatic squamous cell carcinoma in cervical lymph nodes is generally managed as  
15 being of head and neck origin, and metastatic squamous cell carcinoma in inguinal  
16 lymph nodes is generally treated as of anal/lower gynaecological tract/urological  
17 origin<sup>9,10</sup>

- 1 • adenocarcinoma with a specific IHC profile is now often managed (and thus classified)  
2 as originating from the relevant site e.g. CK20-positive CDX2-positive metastatic  
3 adenocarcinoma is generally treated as of colorectal origin.

4 *[Level of evidence – D.]*

5 If markers for squamous, solid organ and neuroendocrine tumours/carcinomas and germ  
6 cell tumours are negative, then consider using additional markers if the morphology  
7 remains suggestive of a specific carcinoma subtype. If these remain negative, or if the  
8 morphology is not differentiated, then proceed to the next step of considering primary site  
9 of probable adenocarcinoma.

10 *[Level of evidence – GPP.]*

## 11 **5.4 Specific approach to diagnosis: predicted primary site of** 12 **adenocarcinoma**

### 13 **5.4.1 Primary site of adenocarcinoma: morphological description**

14 If the tumour is an obvious adenocarcinoma, or alternatively if the tumour shows no other  
15 specific carcinoma subtype differentiation on morphology or immunohistochemistry, but is  
16 presumed to be an adenocarcinoma, then the next step is to consider the possible primary  
17 site of the adenocarcinoma.

- 18 • Adenocarcinomas may show morphological features characteristic or suggestive of  
19 primary site. Such features include:
- 20 • glands with columnar epithelium, apoptosis and luminal ‘dirty’ necrosis in colorectal  
21 and some other gastrointestinal adenocarcinomas
  - 22 • papillary epithelium and/or calcispherites in ovarian serous adenocarcinoma
  - 23 • diffuse morphology and ‘signet ring’ cells in gastric and occasionally colorectal and  
24 lobular breast adenocarcinoma.

25 Certain sites of metastasis are more common with particular primary sites, as previously  
26 described.<sup>8</sup> The differential diagnosis of metastatic tumours will include tumours originating  
27 in that organ itself. For lymph nodes, axillary lymph node metastases are commonly from  
28 breast (or melanoma); inguinal lymph node metastases are commonly from prostate,  
29 urological or gynaecological tracts or lung; and cervical lymph node metastases are  
30 commonly squamous and from head and neck, lung or oesophagus. For serous cavities,  
31 peritoneal spread is commonly from ovary or gastrointestinal tract; pleural spread is more

1 commonly from lung or breast as well as other sites; and mesothelioma is worth  
2 considering. Bone metastases are commonly from breast and prostate. Liver, lung and  
3 brain metastases may arise from a wide range of primary sites.<sup>53,70</sup> For adenocarcinoma in  
4 the liver, the differential diagnosis may include primary liver tumours, particularly  
5 cholangiocarcinoma which is increasingly recognised and for which there are newer  
6 treatment options.<sup>20,53,71</sup>

7 *[Level of evidence – D.]*

#### 8 **5.4.2 Primary site of adenocarcinoma: IHC studies**

9 If the primary site of adenocarcinoma cannot be diagnosed on morphology alone, then IHC  
10 panels may be applied, such as those shown in Tables 4–6, and tailored to clinical  
11 scenario and morphology.<sup>4,8,22–26,57</sup>

12 Specific IHC markers include NKX3.1 and PSA for prostate, TTF1 for lung tumours and  
13 CDX2 for gastrointestinal.<sup>25</sup> PSA can be positive in other tumours e.g. salivary gland and  
14 some breast carcinomas. TTF1, depending on the antibody clone, may show cross-  
15 reaction in other tumours, especially colorectal carcinoma, but usually the morphology is  
16 helpful; TTF1 is also expressed in thyroid and in small cell carcinomas from any site.  
17 Napsin A can serve as an additional lung marker, although it is also often present in renal  
18 carcinoma (especially papillary), adrenocortical carcinoma and ovarian clear cell  
19 carcinomas.<sup>24,72</sup> A minority of adenocarcinomas originating in lung may be CK7-positive  
20 but negative with TTF1; in this setting, consider staining with SMARCA4 (SWI/SNF  
21 related, matrix associated, actin dependent regulator of chromatin, subfamily A, member  
22 4) because SMARCA4 nuclear staining is generally lost in TTF1-negative lung  
23 adenocarcinomas.<sup>20</sup> ER is positive in many breast and gynaecological adenocarcinomas.  
24 GCDFFP-15 is positive in many breast carcinomas but GATA3 may be a more sensitive  
25 marker for breast, with the caveat that GATA3 is expressed in a range of tissue and  
26 tumour types, including squamous and urothelial.<sup>4,23,25,73</sup>

27 *[Level of evidence – D.]*

28 PAX8 stains most primary ovarian serous, endometrioid and clear cell adenocarcinomas  
29 as well as most primary renal carcinomas and most thyroid and thymic tumours.<sup>24</sup> WT1 is  
30 positive in many gynaecological (especially primary serous ovarian) carcinomas as well as  
31 in mesothelial tumours including malignant mesothelioma (and Wilms tumour). CA125  
32 (and mesothelin) are often positive in gynaecological adenocarcinomas, but may also be  
33 positive in mesothelial tumours and pancreaticobiliary and lung adenocarcinomas. CK20 is

1 positive in gastrointestinal adenocarcinomas, especially colorectal and other intestinal  
 2 adenocarcinomas; CK20 is also positive in urothelial and Merkel cell carcinomas and in  
 3 well-differentiated neuroendocrine tumours/carcinomas from the gastrointestinal tract.  
 4 CDX2 is positive in gastrointestinal adenocarcinomas, especially colorectal, and in  
 5 gastrointestinal neuroendocrine tumours/carcinomas.<sup>74</sup> It is worth noting that colorectal  
 6 adenocarcinomas with deficiency of mismatch repair deficient (dMMR) show a variable  
 7 immunophenotype, with over 15% showing loss of staining with CK20 and/or CDX2.<sup>26</sup> CK7  
 8 is positive in many adenocarcinomas; almost all breast, lung, ovary and pancreaticobiliary  
 9 adenocarcinomas are CK7 positive. Cholangiocarcinoma (biliary carcinoma) shows a  
 10 phenotype similar to pancreatic (and some upper gastrointestinal) adenocarcinomas.

11 *[Level of evidence – C.]*

12 **Table 6: IHC markers commonly used for prediction of primary site in**  
 13 **adenocarcinomas. (Based on Dennis and colleagues<sup>75</sup> and updated from literature.)**  
 14 4,8,22-26,57

	NKX3.1 or PSA	TTF1 or Napsin A	GATA 3 or GCDFP-15	ER	PAX8 or WT1	CA125	CK7	CDX2 and/or CK20
<b>Prostate</b>	+	-	-	-	-	-	-	-
<b>Lung</b>	-	+	-	-	-	-/+	+	-
<b>Breast</b>	-	-	+/-	+/-	-	-/+	+	-
<b>Ovary serous</b>	-	-	-	+/-	+	+	+	-
<b>Ovary mucinous</b>	-	-	-	-/+	-	-/+	-/+	-/+
<b>Pancreas and biliary</b>	-	-	-	-	-	+/-	+	-/+
<b>Stomach</b>	-	-	-	-	-	-	+/-	-/+
<b>Colon</b>	-	-	-	-	-	-	-/+	+

15  
 16 For dataset purposes, if the adenocarcinoma subtype is found to be a specific  
 17 adenocarcinoma, then please move on to and complete the relevant tumour specific  
 18 dataset. If the tumour remains unclassified or is an adenocarcinoma without an obvious  
 19 primary site, then please complete the CUP dataset.

20 *[Level of evidence – GPP.]*

## 1 **6 Core data items**

### 2 **6.1 Data items**

#### 3 **6.1.1 Site of sample**

4 This is required for all tissue biopsies or cytological preparations and is helpful in clinical  
5 assessment of possible primary sites.

#### 6 **6.1.2 Type of sample**

7 This is required to assess whether further tissue sampling may be helpful in determining  
8 possible primary site.

#### 9 **6.1.3 Morphology**

10 Morphological description of tumour type is a standard requirement for histopathological  
11 reporting.

#### 12 **6.1.4 Immunohistochemistry**

13 A list of IHC techniques undertaken is helpful to the treating clinician (or at pathology  
14 review) to ensure certain diagnoses have been excluded. It is a standard requirement for  
15 histopathological reporting.

#### 16 **6.1.5 Exclude lymphoma**

17 This is included as a prompt to ensure that the diagnosis of a disease with specific  
18 treatment or referral pathway has been considered.

#### 19 **6.1.6 Exclude germ cell tumour**

20 This is included as a prompt to ensure that the diagnosis of a disease with specific  
21 treatment or referral pathway has been considered.

#### 22 **6.1.7 Exclude melanoma**

23 This is included as a prompt to ensure that the diagnosis of a disease with specific  
24 treatment or referral pathway has been considered.

#### 25 **6.1.8 Exclude sarcoma**

26 This is included as a prompt to ensure that the diagnosis of a disease with specific  
27 treatment or referral pathway has been considered.

28

29



1 **6.1.9 Broad morphological diagnosis**

2 This categorisation is helpful to pathologists and oncologists to understand the broad  
3 category of tumour being described.

4 **6.1.10 Discussion at CUP MDT**

5 MDT discussion is valuable in many cases and recording of any discussion is necessary.

6 For squamous cell carcinoma involving neck nodes:

- 7 • TNM staging  
8 • TNM edition  
9 • EBV status  
10 • HPV/p16 status

11 These are core items from the RCPATH head and neck cancer datasets, which, even in the  
12 absence of a confirmed head and neck primary site, have prognostic importance. (For  
13 reference purposes, the RCPATH head and neck cancer datasets are under review: new  
14 versions will be published and available on the RCPATH website in due course.)

15 **6.2 When to complete the CUP dataset**

16 If the diagnosis of provisional CUP is overturned in favour of a definitive diagnosis, the  
17 biopsy will be subject to the requirements of the dataset of the particular tumour type. In an  
18 ideal world, there would be no dataset requirement for CUP as all cases of provisional  
19 CUP would be allocated to a particular primary site. The CUP dataset is therefore different  
20 to other College cancer datasets as it details which techniques have been undertaken in  
21 the failed attempt to determine the primary site. This means that the dataset is normally  
22 completed only after the CUP MDT discussion. Completion of the CUP dataset is not  
23 required if a primary site is identified during workup.

24 **6.3 Descriptions of morphology and immunohistochemistry**

25 These aspects of analysis are crucial in any potential CUP workup and so form the main  
26 content of the dataset.

27 *[Level of evidence – C.]*

28

29

## 1 **6.4 Outcome of discussion in CUP MDT**

2 All confirmed CUP cases should have been discussed in a CUP MDT, or related MDT, and  
3 this should be recorded on the dataset. This ensures that the reporting pathologist has  
4 access to all clinical data before making the diagnosis of confirmed CUP. The range of  
5 additional information included in CUP reports is very wide and should be relevant for the  
6 individual case. No specific guidance is therefore feasible that would be applicable to all  
7 cases.

8 *[Level of evidence – C.]*

## 9 **7 Non-core data items**

### 10 **7.1 Molecular testing (e.g. gene panel or genomic sequencing)**

11 These techniques may be helpful in selected cases. This is a rapidly developing area, and  
12 the reader is referred to local and national guidance (for example the National Genomic  
13 Test Directory in England) for current availability and criteria for test selection.<sup>43</sup>

## 14 **8 Diagnostic coding and staging**

15 There are numerous possible tumour sites and therefore the coding should be assigned as  
16 appropriate to the individual case. Relevant codes are listed in Appendix A.

17 Most staging systems require identification of the primary tumour for allocation of a staging  
18 system, but the *TNM Classification of Malignant Tumours (8th edition)* from the Union for  
19 International Cancer Control includes staging systems for squamous cell CUP involving  
20 cervical lymph nodes; different classifications are applied if the tumour is known to be  
21 HPV/p16 positive or EBV positive (see Appendix B).

## 22 **9 Reporting of small biopsy specimens**

23 We recommend that the pathologist seeks additional biopsy material if they believe that  
24 there is any possibility that this would lead to a specific diagnosis other than confirmed  
25 CUP. The minimum size of biopsy cannot be stipulated, but adequate tissue for the wide  
26 range of immunohistochemistry testing must be made available before a diagnosis of  
27 confirmed CUP is made.

28 *[Level of evidence – GPP.]*

## 1 **10 Reporting of frozen sections**

2 We do not recommend that a diagnosis of CUP is rendered using frozen section as the full  
3 range of ancillary tests required to make a diagnosis of CUP is not available.

4 *[Level of evidence – GPP.]*

## 5 **11 Report content**

6 The report should include the following:

- 7 • the clinical information received with the specimen
- 8 • the site of the biopsy, or cytology sample
- 9 • a macroscopic description including specimen size
- 10 • comment on the presence or absence of tissue, or cells, from the focal lesion
- 11 • where relevant, comment on the presence or absence of background tissue, or cells  
12 (e.g. lymphoid tissue and/or cells as histological confirmation that the specimen is  
13 indeed from a lymph node)
- 14 • a morphological description of the lesion
- 15 • the results of any additional stains carried out, including immunohistochemistry
- 16 • a diagnosis, or a discussion of the differential diagnoses
- 17 • an appropriate SNOMED code.

## 18 **12 Criteria for audit**

19 The following are recommended by the RCPATH as key performance indicators (see [Key](#)  
20 [Performance Indicators – Proposals for Implementation](#), July 2013):

- 21 • proportion of confirmed CUP cases reviewed in the CUP MDT meeting and which  
22 have the process of review recorded
  - 23 – standard: 90% of cases
- 24 • proportion of confirmed CUP cases in which the report content contains the data item  
25 listed in section 10 (report content)
  - 26 – standard: 90% of cases

- 1 • proportion of confirmed CUP cases which are reported within nationally or locally  
2 agreed turnaround times. Owing to the complexity of CUP cases, a provisional report  
3 is often required to meet these targets and definitive diagnosis may take longer  
4 – standard: 90% of cases reported within 10 days OR the locally agreed turnaround  
5 time (see below).

6 RCPATH guidance, *Key assurance indicators for pathology services, November 2019*,  
7 states that local patient pathways, agreed with requesters, shall include anticipated  
8 turnaround times for all relevant laboratory investigations and shall be the subject of  
9 annual audit.<sup>76</sup> In the absence of locally agreed anticipated turnaround times for CUP,  
10 those cited in RCPATH guidance *Key performance indicators – proposals for*  
11 *implementation, July 2013* should be used.<sup>77</sup>

## 12 **13 Acknowledgements**

13 Thanks to all our colleagues with an interest in CUP and to patients with CUP and their  
14 carers, who have driven major improvements in CUP diagnosis and management over  
15 recent decades.

16 Thanks also to our colleague pathologists and oncologists working in CUP and site-  
17 specific MDTs who have kindly reviewed drafts of this dataset for omissions/errors,  
18 especially members of the Working Group for Cancer Services.

## 14 References

1. Cancer of Unknown Primary Foundation. *Cancer of Unknown Primary Foundation – Jo's Friends*. Accessed 27 February 2023. Available at: [www.cupfoundjo.org](http://www.cupfoundjo.org)
2. National Institute for Health and Care Excellence (NICE). *Metastatic malignant disease of unknown primary origin in adults: diagnosis and management*, 2010. Accessed 27 February 2023. Available at: [www.nice.org.uk/Guidance/CG104](http://www.nice.org.uk/Guidance/CG104)
3. NHS England National Peer Review Programme. *Manual for Cancer Services, Cancer of Unknown Primary Measures, Version 1.1*, 2011. Accessed 27 February 2023. Available at: [https://assets.publishing.service.gov.uk/government/uploads/system/uploads/attachment\\_data/file/216117/dh\\_125890.pdf](https://assets.publishing.service.gov.uk/government/uploads/system/uploads/attachment_data/file/216117/dh_125890.pdf)
4. Bellizzi AM. An Algorithmic Immunohistochemical Approach to Define Tumor Type and Assign Site of Origin. *Adv Anat Pathol* 2020;27:114–163.
5. Barwell J, Snape K, Wedderburn S. The new genomic medicine service and implications for patients. *Clin Med Lond* 2019;19:273–277.
6. Laprovitera N, Riefolo M, Ambrosini E, Klec C, Pichler M, Ferracin M. Cancer of unknown primary: Challenges and progress in clinical management. *Cancers Basel* 2021;13.
7. Rassy E, Pavlidis N. The currently declining incidence of cancer of unknown primary. *Cancer Epidemiol* 2019;61:139–141.
8. Oien KA. Pathologic evaluation of unknown primary cancer. *Semin Oncol* 2009;36:8–37.
9. Varadhachary GR, Raber MN. Cancer of unknown primary site. *N Engl J Med* 2014;371:8:757–765.
10. Pavlidis N, Pentheroudakis G. Cancer of unknown primary site. *Lancet* 2012;379:1428–1435.
11. Lee MS, Sanoff HK. Cancer of unknown primary. *BMJ* 2020;7:371.
12. Brewster DH, Lang J, Bhatti LA, Thomson CS, Oien KA. Descriptive epidemiology of cancer of unknown primary site in Scotland, 1961-2010. *Cancer Epidemiol* 2014;38:227–234.

13. Cancer Research UK. *Cancer of unknown primary statistics*. Accessed July 2022. Available at: [www.cancerresearchuk.org/health-professional/cancer-statistics/statistics-by-cancer-type/cancer-of-unknown-primary](http://www.cancerresearchuk.org/health-professional/cancer-statistics/statistics-by-cancer-type/cancer-of-unknown-primary)
14. Jones W, Allardice G, Scott I, Oien K, Brewster D, Morrison DS. Cancers of unknown primary diagnosed during hospitalization: a population-based study. *BMC Cancer* 2017;17:85.
15. Bochtler T, Loffler H, Kramer A. Diagnosis and management of metastatic neoplasms with unknown primary. *Semin Diagn Pathol* 2018;35:199–206.
16. Fizazi K, Greco FA, Pavlidis N, Daugaard G, Oien KA, Pentheroudakis G et al. Cancers of unknown primary site: ESMO Clinical Practice Guidelines for diagnosis, treatment and follow-up. *Ann Oncol* 2015;26:133–138.
17. Nishikawa K, Hironaka S, Inagaki T, Komori A, Otsu S, Tamura S et al. A multicentre retrospective study comparing site-specific treatment with empiric treatment for unfavourable subset of cancer of unknown primary site. *Jpn J Clin Oncol* 2022;52:1416–1422.
18. National Comprehensive Cancer Network. *NCCN Clinical Practice Guidelines in Oncology: Guidelines for Occult Primary, Cancer of Unknown Primary (CUP) V.1.2022-2021*. Accessed May 2023. Available at: [www.nccn.org/guidelines/category\\_1](http://www.nccn.org/guidelines/category_1)
19. Losa F, Fernandez I, Etxaniz O, Gimenez A, Gomila P, Iglesias L et al. SEOM-GECOD clinical guideline for unknown primary cancer (2021). *Clin Transl Oncol* 2022;24:681–692.
20. Kramer A, Bochtler T, Pauli C, Baciarello G, Delorme S, Hemminki K et al. Cancer of unknown primary: ESMO Clinical Practice Guideline for diagnosis, treatment and follow-up. *Ann Oncol* 2023;34:228–246.
21. van der Strate I, Kazemzadeh F, Nagtegaal ID, Robbrecht D, van de Wouw A, Padilla CS et al. International consensus on the initial diagnostic workup of cancer of unknown primary. *Crit Rev Oncol Hematol* 2023;181:103868.
22. Lin F, Liu H. Immunohistochemistry in undifferentiated neoplasm/tumor of uncertain origin. *Arch Pathol Lab Med* 2014;138:1583–1610.
23. Kandalaf PL, Gown AM. Practical applications in immunohistochemistry: Carcinomas of unknown primary site. *Arch Pathol Lab Med* 2016;140:6:508–523.

24. Conner JR, Hornick JL. Metastatic carcinoma of unknown primary: diagnostic approach using immunohistochemistry. *Adv Anat Pathol* 2015;22:149–167.
25. Kei S, Adeyi OA. Practical application of lineage-specific immunohistochemistry markers: Transcription factors (sometimes) behaving badly. *Arch Pathol Lab Med* 2020;144:626–643.
26. Selves J, Long-Mira E, Mathieu MC, Rochaix P, Ilie M. Immunohistochemistry for diagnosis of metastatic carcinomas of unknown primary site. *Cancers (Basel)* 2018;10:108.
27. ImmunoQuery. *Evidence-based decision support system for immunohistochemistry*. Accessed March 2023. Available at: [www.immunoquery.com](http://www.immunoquery.com)
28. Lin F, Chen Z. Standardization of diagnostic immunohistochemistry: literature review and geisinger experience. *Arch Pathol Lab Med* 2014;138:1564–1577.
29. Agwa E, Ma PC. Overview of various techniques/platforms with critical evaluation of each. *Curr Treat Options Oncol* 2013;14:623–633.
30. Greco FA. Molecular diagnosis of the tissue of origin in cancer of unknown primary site: useful in patient management. *Curr Treat Options Oncol* 2013;14:634–642.
31. Varadhachary G. New strategies for carcinoma of unknown primary: the role of tissue-of-origin molecular profiling. *Clin Cancer Res* 2013;19:4027–4033.
32. Oien KA, Dennis JL. Diagnostic work-up of carcinoma of unknown primary: from immunohistochemistry to molecular profiling. *Ann Oncol* 2012;23:71–77.
33. Ross JS, Wang K, Gay L, Otto GA, White E, Iwanik K *et al*. Comprehensive genomic profiling of carcinoma of unknown primary site: New routes to targeted therapies. *JAMA Oncol* 2015;1:40–49.
34. Loffler H, Pfarr N, Kriegsmann M, Endris V, Hielscher T, Lohneis P *et al*. Molecular driver alterations and their clinical relevance in cancer of unknown primary site. *Oncotarget* 2016;12:7:44322–44329.
35. Gatalica Z, Millis SZ, Vranic S, Bender R, Basu GD, Voss A *et al*. Comprehensive tumor profiling identifies numerous biomarkers of drug response in cancers of unknown primary site: analysis of 1806 cases. *Oncotarget* 2014;5:12440–12447.
36. Posner A, Prall OW, Sivakumaran T, Etemadamoghadam D, Thio N, Pattison A *et al*. A comparison of DNA sequencing and gene expression profiling to assist tissue of origin diagnosis in cancer of unknown primary. *J Pathol* 2023;259:81–92.

37. Varadhachary G. Carcinoma of Unknown Primary Site: The Poster Child for Personalized Medicine? *JAMA Oncol* 2015;1:19–21.
38. Meleth S, Whitehead N, Evans TS, Lux L. Technology assessment on genetic testing or molecular pathology testing of cancers with unknown primary site to determine origin. Agency for Healthcare Research and Quality, 2013.
39. Kato S, Gumas S, Adashek JJ, Okamura R, Lee S, Sicklick JK *et al.* Multi-omic analysis in carcinoma of unknown primary (CUP): therapeutic impact of knowing the unknown. *Mol Oncol* 2022;22.
40. Mohrmann L, Werner M, Oles M, Mock A, Uhrig S, Jahn A *et al.* Comprehensive genomic and epigenomic analysis in cancer of unknown primary guides molecularly-informed therapies despite heterogeneity. *Nat Commun* 2022;13:4485.
41. Lombardo R, Tosi F, Nocerino A, Bencardino A, Gambi V, Ricotta R *et al.* The quest for improving treatment of cancer of unknown primary (CUP) through molecularly-driven treatments: A systematic review. *Front Oncol* 2020;10:533.
42. Teixeira MR, Oliveira J, Borralho P, Fernandes MGO, Almodovar T, Fernandes I *et al.* Portuguese consensus recommendations for next-generation sequencing of lung cancer, rare tumors, and cancers of unknown primary origin in clinical practice. *Acta Med Port* 2022;35:677–690.
43. NHS England. *National genomic test directory for cancer*, 2022. Accessed March 2023. Available at: [www.england.nhs.uk/publication/national-genomic-test-directories](http://www.england.nhs.uk/publication/national-genomic-test-directories)
44. Laprovitera N, Salamon I, Gelsomino F, Porcellini E, Riefolo M, Garonzi M *et al.* Genetic Characterization of Cancer of Unknown Primary Using Liquid Biopsy Approaches. *Front Cell Dev Biol* 2021;9:666156.
45. Bochtler T, Wohlfromm T, Hielscher T, Stichel D, Pouyiourou M, Kramer A *et al.* Prognostic impact of copy number alterations and tumor mutational burden in carcinoma of unknown primary. *Genes Chromosomes Cancer* 2022;61:551–560.
46. Rassy E, Labaki C, Chebel R, Boussios S, Smith-Gagen J, Greco F *et al.* Systematic review of the CUP trials characteristics and perspectives for next-generation studies. *Cancer Treat Rev* 2022;107:102407.
47. RCPATH (Fisher C and Thway K). *Dataset for histopathological reporting of soft tissue sarcomas*, 2022. Accessed May 2023. Available at: [www.rcpath.org/static/369456b0-](http://www.rcpath.org/static/369456b0-)



[f7b4-4631-a0c6d161176f5782/Dataset-for-histopathological-reporting-of-soft-tissue-sarcoma.pdf](https://www.rcpath.org/static/bb9e7568-d41d-4d99-8ca12c8f0b67c8a5/74a60fce-3472-4ef9-8be61ec7d7921976/q087-role-cellular-pathologist-cancer-mdt.pdf)

48. Guccione L, Fisher K, Mileskin L, Tohill R, Bowtell D, Quinn S *et al.* Uncertainty and the unmet informational needs of patients with cancer of unknown primary (CUP): a cross-sectional multi-site study. *Support Care Cancer* 2022;30:8217–8229.
49. Ding Y, Jiang J, Xu J, Chen Y, Zheng Y, Jiang W *et al.* Site-specific therapy in cancers of unknown primary site: a systematic review and meta-analysis. *ESMO Open* 2022;7:2:100407.
50. Stares M, Purshouse K, Knowles G, Haigh R, Irvine J, Gatenby A *et al.* Characterisation and outcomes of patients referred to a regional cancer of unknown primary team: a 10-year analysis. *Br J Cancer* 2021;125:1503–1510.
51. RCPATH (Hunter K, Jamieson L, Wong N, Varma M, Bateman A.) *Best practice recommendations: The role of the cellular pathologist in the cancer multidisciplinary team*, 2022. Accessed May 2023. Available at: [www.rcpath.org/static/bb9e7568-d41d-4d99-8ca12c8f0b67c8a5/74a60fce-3472-4ef9-8be61ec7d7921976/q087-role-cellular-pathologist-cancer-mdt.pdf](http://www.rcpath.org/static/bb9e7568-d41d-4d99-8ca12c8f0b67c8a5/74a60fce-3472-4ef9-8be61ec7d7921976/q087-role-cellular-pathologist-cancer-mdt.pdf)
52. Winters DA, Soukup T, Sevdalis N, Green JSA, Lamb BW. The cancer multidisciplinary team meeting: in need of change? History, challenges and future perspectives. *BJU Int* 2021;128:271–279.
53. RCPATH (Wyatt JH, Hubsher S, Goldin R, Tiniakos D). *Dataset for histopathological reporting of liver resection specimens (including gallbladder) and liver biopsies for primary and metastatic carcinoma*, 2022. Accessed May 2023. Available at: [www.rcpath.org/static/cbae24ce-220c-4d9f-95c5b83dd1f0ad2b/Dataset-for-histopathological-reporting-of-liver-resection-specimens-and-liver-biopsies-for-primary-and-metastatic-carcinoma.pdf](http://www.rcpath.org/static/cbae24ce-220c-4d9f-95c5b83dd1f0ad2b/Dataset-for-histopathological-reporting-of-liver-resection-specimens-and-liver-biopsies-for-primary-and-metastatic-carcinoma.pdf)
54. Monaco SE, Dabbs DJ. Metastatic tumors of unknown origin: Ancillary testing in cytologic specimens. *Surg Pathol Clin* 2014;7:105–129.
55. Jhala N, Arriola A, Pantanowitz L. Serous cavity metastasis: Evaluation of unknown primary. *Cytojournal* 2022;19:16.
56. Losa F, Iglesias L, Pane M, Sanz J, Nieto B, Fuste V *et al.* 2018 consensus statement by the Spanish Society of Pathology and the Spanish Society of Medical

Oncology on the diagnosis and treatment of cancer of unknown primary. *Clin Transl Oncol* 2018;20:1361–1372.

57. Kato S, Alsafar A, Walavalkar V, Hainsworth J, Kurzrock R. Cancer of unknown primary in the molecular era. *Trends Cancer* 2021;7:465–477.
58. Pisacane A, Cascardi E, Berrino E, Polidori A, Sarotto I, Casorzo L *et al.* Real-world histopathological approach to malignancy of undefined primary origin (MUO) to diagnose cancers of unknown primary (CUPs). *Virchows Arch* 2023;482:463:475.
59. Amin MB, Epstein JI, Ulbright TM, Humphrey PA, Egevad L, Montironi R *et al.* Best practices recommendations in the application of immunohistochemistry in urologic pathology: report from the International Society of Urological Pathology consensus conference. *Am J Surg Pathol* 2014;38:1017–1022.
60. The Royal College of Pathologists. *Standards for specialist laboratory integration and Dataset for the histopathological reporting of lymphomas*, 2015. Accessed May 2023. Available at: [www.rcpath.org/static/de0b5b4a-7f77-4fe2-ab56fd618ee69098/G142-LymphomaDataset-Oct15.pdf](http://www.rcpath.org/static/de0b5b4a-7f77-4fe2-ab56fd618ee69098/G142-LymphomaDataset-Oct15.pdf)
61. NICE. *Haematological cancers: improving outcomes*, 2016. Accessed May 2023. Available at: [www.nice.org.uk/guidance/ng47](http://www.nice.org.uk/guidance/ng47)
62. NICE. *Sarcoma, Quality standard (QS78)*, 2015. [www.nice.org.uk/guidance/qs78](http://www.nice.org.uk/guidance/qs78)
63. Wang J, Weiss LM, Hu B, Chu P, Zuppan C, Felix D *et al.* Usefulness of immunohistochemistry in delineating renal spindle cell tumours. A retrospective study of 31 cases. *Histopathology* 2004;44:462–471.
64. Leinung S, Mobius C, Udelnow A, Hauss J, Wurl P. Histopathological outcome of 597 isolated soft tissue tumors suspected of soft tissue sarcoma: a single-center 12-year experience. *Eur J Surg Oncol* 2007;33:508–511.
65. Higgins RA, Blankenship JE, Kinney MC. Application of immunohistochemistry in the diagnosis of non-Hodgkin and Hodgkin lymphoma. *Arch Pathol Lab Med* 2008;132:441–461.
66. Paydas S, Zorludemir S, Ergin M. Granulocytic sarcoma: 32 cases and review of the literature. *Leuk Lymphoma* 2006;47:2527–2541.
67. Chernock RD, Lewis JS. Approach to metastatic carcinoma of unknown primary in the head and neck: squamous cell carcinoma and beyond. *Head Neck Pathol* 2015;9:6–15.

68. Stelow EB, Yaziji H. Immunohistochemistry, carcinomas of unknown primary, and incidence rates. *Semin Diagn Pathol* 2018;35:143–152.
69. Schmitt AM, Blank A, Marinoni I, Komminoth P, Perren A. Histopathology of NET: Current concepts and new developments. *Best Pract Res Clin Endocrinol Metab* 2016;30:33–43.
70. Wang JD, Sebastian C, Walther Z, Suresh T, Lacy J, Zhang X *et al*. An appraisal of immunohistochemical stain use in hepatic metastasis highlights the effectiveness of the individualized, case-based approach. *Arch Pathol Lab Med* 2023;147:185–192.
71. Conway AM, Morris GC, Smith S, Vekeria M, Manoharan P, Mitchell C *et al*. Intrahepatic cholangiocarcinoma hidden within cancer of unknown primary. *Br J Cancer* 2022;127:531–540.
72. Turner BM, Cagle PT, Sainz IM, Fukuoka J, Shen SS, Jagirdar J *et al*. Napsin A, a new marker for lung adenocarcinoma, is complementary and more sensitive and specific than thyroid transcription factor 1 in the differential diagnosis of primary pulmonary carcinoma evaluation of 1674 cases by tissue microarray. *Arch Pathol Lab Med* 2012;136:163–171.
73. Liu H. Application of immunohistochemistry in breast pathology: a review and update. *Arch Pathol Lab Med* 2014;138:1629–1642.
74. Chen ZE, Lin F. Application of immunohistochemistry in gastrointestinal and liver neoplasms: new markers and evolving practice. *Arch Pathol Lab Med* 2015;139:14–23.
75. Dennis JL, Hvidsten TR, Wit EC, Komorowski J, Bell KA, Downie I *et al*. Markers of adenocarcinoma characteristic of the site of origin: development of a diagnostic algorithm. *Clin Cancer Research* 2005;11:3766–3772.
76. The Royal College of Pathologists. *Key assurance indicators for pathology services*, 2019. Accessed May 2023. Available at: [www.rcpath.org/static/62de2970-42aa-4d73-9bf1122a1746331a/G181-Key-assurance-indicators-for-pathology-services.pdf](http://www.rcpath.org/static/62de2970-42aa-4d73-9bf1122a1746331a/G181-Key-assurance-indicators-for-pathology-services.pdf)
77. RCPATH. *Key performance indicators – proposals for implementation*, July 2013. Accessed May 2023. Available at: [www.rcpath.org/static/a428b2af-7ae9-42da-bf9343e184ee05cf/Key-Performance-Indicators-Proposals-for-implementation-Current-version.pdf](http://www.rcpath.org/static/a428b2af-7ae9-42da-bf9343e184ee05cf/Key-Performance-Indicators-Proposals-for-implementation-Current-version.pdf)

78. Brierley JD, Gospodarowicz MK, Wittekind C. *TNM Classification of Malignant Tumours (8th edition)*. Oxford, UK: Wiley-Blackwell, 2016.

## Appendix A SNOMED codes

### Topographical codes (T) and morphological codes (M)

Topographical codes are used in SNOMED 2 and SNOMED 3 to indicate the site of lesions and morphological codes (M) are used to indicate the morphological diagnosis. Common topography and morphology codes are given in the second table below, although the list is not exhaustive.

Tumour site	SNOMED 2/ SNOMED 3 code	SNOMED CT terminology	SNOMED CT code
Liver	T-56000/T-62000	Entire liver (body structure)	181268008
Brain	T-X2000/T-A0100	Entire brain (body structure)	258335003
Lung	T-28000/T-28000	Entire lung (body structure)	181216001
Lymph node (NOS)	T-08000/T-C4000	Entire lymph node (body structure)	181756000
Axillary lymph node	T-08710/T-C4710	Axillary lymph node structure (body structure)	68171009
Cervical lymph node	T-08200/T-C4200	Cervical lymph node structure (body structure)	81105003
Inguinal lymph node	T-08810/T-C4810	Inguinal lymph node structure (body structure)	8928004
Para-aortic lymph node	T-08480/T-C4480	Para-aortic node (body structure)	181761003
Mesenteric lymph node	T-08400/T-C4400	Structure of lymph node of mesentery (body structure)	279795009
Mediastinal lymph node	T-08360/T-C4360	Mediastinal lymph node structure (body structure)	62683002
Bone (NOS)	T-1X500/T-11000	Bone (tissue) structure (body structure)	3138006
Pleura	T-29000/T-29000	Pleural membrane structure (body structure)	3120008
Peritoneum	T-Y4400/T-D4400	Peritoneum (serous membrane) structure (body structure)	15425007

<b>Morphological codes</b>	<b>SNOMED 2/ SNOMED 3 code</b>	<b>SNOMED CT terminology</b>	<b>SNOMED CT code</b>
Metastatic malignant neoplasm, NOS	M-80006	Neoplasm, metastatic (morphologic abnormality)	14799000
Metastatic carcinoma, NOS	M-80106	Carcinoma, metastatic (morphologic abnormality)	79282002
Metastatic adenocarcinoma, NOS	M-81406	Adenocarcinoma, metastatic (morphologic abnormality)	4590003
Metastatic squamous cell carcinoma	M-80706	Squamous cell carcinoma, metastatic (morphologic abnormality)	64204000

## **SNOMED versions**

SNOMED CT, also known as SNOMED International, is a newer SNOMED system, first introduced in 2002 with multiple updates (it is shown in the two right-hand columns) and uses different codes from SNOMED 2 and SNOMED 3 (numerical code only is used for SNOMED CT, rather than T and M codes followed by a number).

Please note that SNOMED 2 and SNOMED 3 are no longer licensed for use.

## **Procedure codes (P)**

Local P codes should be recorded. At present, P codes vary according to the SNOMED system in use in different institutions.

## Appendix B    TNM staging for squamous cell carcinoma of unknown primary involving cervical lymph nodes<sup>78</sup>

### T category

pT0 – No evidence of primary tumour

### N category

	<b>EBV or HPV/p16 negative or unknown</b>	<b>HPV/p16 positive</b>	<b>EBV positive</b>
<b>pN1</b>	Metastasis in a single ipsilateral lymph node, 3 cm or less in greatest dimension without extranodal extension	Unilateral metastasis, in cervical lymph node(s), all 6 cm or less in greatest dimension	Unilateral metastasis, in cervical lymph node(s), and/or unilateral or bilateral metastasis in retropharyngeal lymph nodes, 6 cm or less in greatest dimension, above the caudal border of cricoid cartilage
<b>pN2</b>		Contralateral or bilateral metastasis in cervical lymph node(s), all 6 cm or less in greatest dimension	Bilateral metastasis in cervical lymph node(s), 6 cm or less in greatest dimension, above the caudal border of cricoid cartilage
<b>pN2a</b>	Metastasis in a single ipsilateral lymph node, more than 3 cm but not more than 6 cm in greatest dimension without extranodal extension		
<b>pN2b</b>	Metastasis in multiple ipsilateral lymph nodes, none more than 6 cm in greatest dimension, without extranodal extension		
<b>pN2c</b>	Metastasis in bilateral or contralateral lymph nodes, none more than 6 cm in greatest		

	dimension, without extranodal extension		
<b>pN3</b>		Metastasis in cervical lymph node(s) greater than 6 cm in dimension	Metastasis in cervical lymph node(s) greater than 6 cm in dimension and/or extension below the caudal border of cricoid cartilage
<b>pN3a</b>	Metastasis in a lymph node more than 6 cm in greatest dimension without extranodal extension		
<b>pN3b</b>	Metastasis in a single or multiple lymph nodes with clinical extranodal extension		

### **M category**

M0 – No distant metastases

M1 – Distant metastasis



## Appendix C Reporting proforma for cancer of unknown primary

Surname..... Forenames..... Date of birth..... Sex.....  
Hospital..... Hospital no.....NHS/CHI no.....  
Date of receipt..... Date of reporting..... Report no.....  
Pathologist..... Surgeon.....

### Site of sample\* – tick box

Liver  Lung  Brain  Lymph node  Skin  (specify site .....)  
Bone  (specify site.....) Other  (specify site .....)

### Type of sample\* – tick all boxes which apply

Small biopsy e.g. needle core  Small excision biopsy  Effusion cytology   
FNA

Specimen laterality (where applicable) Left  Right

### Morphology – tick box

Epithelioid  Sarcomatoid or spindle  Small round blue cell   
Undifferentiated/pleomorphic   
Other  (specify.....)

### Immunohistochemistry – list markers employed

Positive.....  
Equivocal.....  
Negative.....

### Have you excluded

Lymphoma? Yes  /No  Germ cell tumour? Yes  /No   
Melanoma? Yes  /No  Sarcoma? Yes  /No

### Broad morphological diagnosis\*

Malignant neoplasm, NOS  Carcinoma, NOS  Squamous cell carcinoma

Adenocarcinoma, NOS       Neuroendocrine tumour/carcinoma

Has the case been discussed at CUP MDT: Yes  /No

Date of discussion at CUP MDT.....

**TNM staging if squamous cell carcinoma with lymph node metastases involving cervical lymph nodes\***

**TNM edition**

EBV positive: Yes  / No  / Not Known

HPV/p16 positive: Yes  / No  / Not Known

pT..... pN..... pM.....

Comment:.....

Pathologist ..... Date...../...../.....

SNOMED codes\* T..... M.....

\*Data items that are currently part of the Cancer Outcomes and Services Dataset v7.

## Appendix D Reporting proforma for cancer of unknown primary in list format

Element name	Values	Implementation comments	COSD v9
Site of sample	Single selection value list: <ul style="list-style-type: none"> <li>• Liver</li> <li>• Lung</li> <li>• Brain</li> <li>• Lymph node</li> <li>• Skin</li> <li>• Bone</li> <li>• Other</li> </ul>		
Site of sample, specify	Free text	Only applicable if 'Site of sample, Skin', 'Site of sample, Bone' or 'Site of sample, Other' is selected.	
Type of sample	Multiple selection value list: <ul style="list-style-type: none"> <li>• Small biopsy e.g. needle core</li> <li>• Small excision biopsy</li> <li>• Effusion cytology</li> <li>• FNA</li> <li>• Specimen laterality</li> <li>• Other</li> </ul>	Only applicable if 'Specimen laterality, Other' is selected.	pCR0760 <ul style="list-style-type: none"> <li>• Small biopsy e.g. needle core = BU</li> <li>• Small excision biopsy = EX</li> <li>• Effusion cytology – CY</li> <li>• FNA = CY</li> <li>• Other = 99</li> </ul>
Type of sample, specify	Free text	Only applicable if 'Type of sample, Other' is selected.	
Laterality (where applicable)	Single selection value list: <ul style="list-style-type: none"> <li>• Left</li> <li>• Right</li> </ul>	Not applicable if no value selected.	
Morphology	Single selection value list: <ul style="list-style-type: none"> <li>• Epithelioid</li> </ul>		

	<ul style="list-style-type: none"> <li>• Sarcomatoid or spindle</li> <li>• Small round blue cell</li> <li>• Undifferentiated/pleomorphic</li> <li>• Other</li> </ul>		
Morphology, specify	Free text	Only applicable if 'Morphology, Other' is selected.	
Immunohistochemistry, positive	Free text		
Immunohistochemistry, equivocal	Free text		
Immunohistochemistry, negative	Free text		
Lymphoma excluded	Single selection value list: <ul style="list-style-type: none"> <li>• Yes</li> <li>• No</li> </ul>		
Germ cell tumour excluded	Single selection value list: <ul style="list-style-type: none"> <li>• Yes</li> <li>• No</li> </ul>		
Melanoma excluded	Single selection value list: <ul style="list-style-type: none"> <li>• Yes</li> <li>• No</li> </ul>		
Sarcoma excluded	Single selection value list: <ul style="list-style-type: none"> <li>• Yes</li> <li>• No</li> </ul>		
Broad morphological diagnosis	Single selection value list: <ul style="list-style-type: none"> <li>• Malignant neoplasm, NOS</li> <li>• Carcinoma, NOS</li> <li>• Squamous cell carcinoma</li> <li>• Adenocarcinoma, NOS</li> </ul>		

	<ul style="list-style-type: none"> <li>Neuroendocrine tumour/carcinoma</li> </ul>		
Confirmation of discussion at CUP MDT	Single selection value list: <ul style="list-style-type: none"> <li>Yes</li> <li>No</li> </ul>		
Date of discussion at CUP MDT	Date		
TNM edition	Single selection value list: <ul style="list-style-type: none"> <li>UICC 8</li> <li>Not applicable</li> </ul>		pCR6980 UICC 8 = 1
EBV positive	Single selection value list: <ul style="list-style-type: none"> <li>Yes</li> <li>No</li> <li>Not known</li> </ul>		
HPV/p16 positive	Single selection value list: <ul style="list-style-type: none"> <li>Yes</li> <li>No</li> <li>Not known</li> </ul>		
pT	Single selection value list: <ul style="list-style-type: none"> <li>Not applicable</li> <li>pT0</li> </ul>		pCR0910
pN	Single selection value list: <ul style="list-style-type: none"> <li>Not applicable</li> <li>pN1</li> <li>pN2</li> <li>pN2a</li> <li>pN2b</li> <li>pN2c</li> <li>pN3</li> <li>pN3a</li> <li>pN3b</li> </ul>		pCR0920
pM	Single selection value list: <ul style="list-style-type: none"> <li>pM1</li> <li>Not applicable</li> </ul>		pCR0930
Comment	Free text		

SNOMED Topography code	May have multiple codes. Look up from SNOMED tables.		pCR6410
SNOMED Morphology code	May have multiple codes. Look up from SNOMED tables.		pCR6420

# Appendix E Histopathology worksheet for metastatic carcinoma of uncertain primary site

Surname..... Forenames..... Date of birth..... Sex.....  
 Hospital..... Hospital no.....  
 NHS/CHI no.....  
 Date of receipt..... Date of reporting..... Report no.....

## Carcinoma subtype: immunohistochemistry

Panel	Specific immunohistochemical markers used	Positive	Negative	Equivocal
Adenocarcinoma				
Squamous carcinoma				
Urothelial carcinoma				
Neuroendocrine tumour/ carcinoma				
Solid carcinoma: renal				
Solid carcinoma: liver				
Solid carcinoma: thyroid				
Solid carcinoma: adrenal				
Germ cell tumour				
Mesothelioma				

Result for CK7..... Result for CK20.....

Any other relevant IHC markers employed:.....  
 .....

**Diagnosis (specific carcinoma subtype):**.....

## Adenocarcinoma subtyping: morphology

Morphological pattern	Present? (tick more than one if necessary)
Poorly differentiated carcinoma	
Adenocarcinoma NOS	
Papillary adenocarcinoma	
Signet ring cell/diffuse adenocarcinoma	
Other specific morphology (describe)	

## Adenocarcinoma subtyping: immunohistochemistry

Panel	Specific immunohistochemical markers used	Positive	Negative	Equivocal
Prostate				
Lung				
Breast				
Ovary and other gynaecological				
Colorectum				
Gastro-oesophageal				
Pancreatico-biliary				
Other (specify)				

**Adenocarcinoma subtype diagnosis:** .....

Any further comments especially for assessment of poorly differentiated malignancy:

.....



## Appendix F Summary table – Explanation of grades of evidence

(modified from Palmer K *et al. BMJ* 2008; 337:1832)

Grade (level) of evidence	Nature of evidence
Grade A	<p>At least one high-quality meta-analysis, systematic review of randomised controlled trials or a randomised controlled trial with a very low risk of bias and directly attributable to the target population</p> <p>or</p> <p>A body of evidence demonstrating consistency of results and comprising mainly well-conducted meta-analyses, systematic reviews of randomised controlled trials or randomised controlled trials with a low risk of bias, directly applicable to the target cancer type.</p>
Grade B	<p>A body of evidence demonstrating consistency of results and comprising mainly high-quality systematic reviews of case-control or cohort studies and high-quality case-control or cohort studies with a very low risk of confounding or bias and a high probability that the relation is causal and which are directly applicable to the target population</p> <p>or</p> <p>Extrapolation evidence from studies described in A.</p>
Grade C	<p>A body of evidence demonstrating consistency of results and including well-conducted case-control or cohort studies and high-quality case-control or cohort studies with a low risk of confounding or bias and a moderate probability that the relation is causal and which are directly applicable to the target population</p> <p>or</p> <p>Extrapolation evidence from studies described in B.</p>
Grade D	<p>Non-analytic studies such as case reports, case series or expert opinion</p> <p>or</p> <p>Extrapolation evidence from studies described in C.</p>
Good practice point (GPP)	<p>Recommended best practice based on the clinical experience of the authors of the writing group.</p>

## Appendix G AGREE II guideline monitoring sheet

The cancer datasets of The Royal College of Pathologists comply with the AGREE II standards for good quality clinical guidelines. The sections of this cancer dataset that indicate compliance with each of the AGREE II standards are indicated in the table.

AGREE standard	Section of guideline
<b>Scope and purpose</b>	
1 The overall objective(s) of the guideline is (are) specifically described	Foreword, Introduction
2 The health question(s) covered by the guideline is (are) specifically described	Foreword, Introduction
3 The population (patients, public, etc.) to whom the guideline is meant to apply is specifically described	Foreword
<b>Stakeholder involvement</b>	
4 The guideline development group includes individuals from all the relevant professional groups	Foreword
5 The views and preferences of the target population (patients, public, etc.) have been sought	Foreword
6 The target users of the guideline are clearly defined	Introduction
<b>Rigour of development</b>	
7 Systematic methods were used to search for evidence	Foreword
8 The criteria for selecting the evidence are clearly described	Foreword
9 The strengths and limitations of the body of evidence are clearly described	Foreword
10 The methods for formulating the recommendations are clearly described	Foreword
11 The health benefits, side effects and risks have been considered in formulating the recommendations	Foreword and Introduction
12 There is an explicit link between the recommendations and the supporting evidence	5–7
13 The guideline has been externally reviewed by experts prior to its publication	Foreword
14 A procedure for updating the guideline is provided	Foreword
<b>Clarity of presentation</b>	
15 The recommendations are specific and unambiguous	1–9
16 The different options for management of the condition or health issue are clearly presented	1–9
17 Key recommendations are easily identifiable	1–9
<b>Applicability</b>	
18 The guideline describes facilitators and barriers to its application	Foreword
19 The guideline provides advice and/or tools on how the recommendations can be put into practice	Appendices A–E
20 The potential resource implications of applying the recommendations have been considered	Foreword
21 The guideline presents monitoring and/or auditing criteria	10
<b>Editorial independence</b>	
22 The views of the funding body have not influenced the content of the guideline	Foreword
23 Competing interest of guideline development group members have been recorded and addressed	Foreword