



Tissue pathways for non-neoplastic ophthalmic pathology specimens

June 2020

Authors: Dr Luciane Dreher Irion, Manchester University NHS Foundation Trust
Dr Caroline Thaug, UCL Institute of Ophthalmology and Moorfields Eye Hospital NHS Foundation Trust

Unique document number	G141
Document name	Tissue pathways for non-neoplastic ophthalmic pathology specimens
Version number	3
Produced by	Dr Luciane Dreher Irion is a consultant histopathologist at Manchester University NHS Foundation Trust, member of the National Specialist Ophthalmic Pathology Service (NSOPS) and RCPATH Subspecialty Advisor for ophthalmic pathology. Dr Caroline Thaug is a consultant histopathologist at UCL Institute of Ophthalmology and Moorfields Eye Hospital and a member of NSOPS.
Date active	June 2020
Date for full review	June 2025
Comments	This document replaces the 1st edition of the <i>Tissue pathways for non-neoplastic ophthalmic pathology specimens</i> published in February 2015. In accordance with the College's pre-publications policy, this document was on the Royal College of Pathologists' website for consultation from 5 May to 2 June 2020. Responses and authors' comments are available to view on publication of the final document. Dr Brian Rous Clinical Lead for Guideline Review

The Royal College of Pathologists
6 Alie Street, London E1 8QT
Tel: 020 7451 6700
Fax: 020 7451 6701
Web: www.rcpath.org

Registered charity in England and Wales, no. 261035
© 2020, The Royal College of Pathologists

This work is copyright. You may download, display, print and reproduce this document for your personal, non-commercial use. Requests and inquiries concerning reproduction and rights should be addressed to the Royal College of Pathologists at the above address. First published: 2020.



Contents

Foreword	3
1 Introduction	4
2 Small lid biopsy	7
3 Full thickness lid resection	8
4 Corneal specimens	10
5 Conjunctival biopsies	11
6 Trabecular meshwork	13
7 Iris, ciliary body and choroid.....	14
8 Lens.....	15
9 Vitreous specimens and cytology.....	16
10 Epiretinal membranes	17
11 Enucleations	18
12 Eviscerations	20
13 Orbital and lacrimal gland biopsies	21
14 Orbital exenteration.....	22
15 Impression cytology	23
16 Lacrimal sac biopsies/excision	24
17 Criteria for audit	25
18 References	26
Appendix A Summary table – explanation of grades of evidence.....	28
Appendix B AGREE II guideline monitoring sheet	29



NICE has accredited the process used by the Royal College of Pathologists to produce its tissue pathways. Accreditation is valid for five years from 25 July 2017. More information on accreditation can be viewed at www.nice.org.uk/accreditation.

For full details on our accreditation visit: www.nice.org.uk/accreditation.

Foreword

The tissue pathways published by the Royal College of Pathologists (RCPATH) are guidelines that enable pathologists to deal with routine surgical specimens in a consistent manner and to a high standard. This ensures that accurate diagnostic and prognostic information is available to clinicians for optimal patient care and ensures appropriate management for specific clinical circumstances. This guideline has been developed to cover most common circumstances. However, we recognise that guidelines cannot anticipate every pathological specimen type and clinical scenario. Occasional variation from the practice recommended in this guideline may therefore be required to report a specimen in a way that maximises benefit to the patient.

The guidelines themselves constitute the tools for implementation and dissemination of good practice.

The following stakeholders were contacted to consult on this document:

- British Association for Ophthalmic Pathology (BAOP)
- National Specialist Ophthalmic Pathology Service (NSOPS).

No major organisational changes or cost implications have been identified that would hinder the implementation of the tissue pathway.

The information used to develop this tissue pathway was collected from electronic searches of the medical literature, previous recommendations of the RCPATH and local guidelines held by the NSOPS laboratories in the UK. Published evidence was evaluated using modified SIGN guidance (see Appendix A). Consensus of evidence in the tissue pathways was achieved by expert review. Gaps in the evidence were identified by College members via feedback received from consultation. The sections of this tissue pathway that indicate compliance with each of the AGREE II standards are indicated in Appendix B.

A formal revision cycle for all tissue pathways takes place on a five-yearly basis. However, each year, the College will ask the authors of the tissue pathways, in conjunction with the relevant subspecialty adviser to the College, to consider whether or not the document needs to be updated or revised. A full consultation process will be undertaken if major revisions are required. If minor revisions are required, an abridged consultation process will be undertaken whereby a short note of the proposed changes will be placed on the College website for two weeks for members' attention. If members do not object to the changes, the changes will be incorporated into the pathways and the full revised version (incorporating the changes) will replace the existing version on the publications page of the College website. All changes will be documented in the data control section of the relevant pathway.

The pathway has been reviewed by the Clinical Effectiveness department, Working Group on Cancer Services and Lay Governance Group. It was placed on the College website for consultation with the membership from 5 May to 2 June 2020. All comments received from the Working Group and membership were addressed by the authors to the satisfaction of the Chair of the Working Group and the Clinical Lead for Guideline Review.

This pathway was developed without external funding to the writing group. The College requires the authors of tissue pathways to provide a list of potential conflicts of interest; these are monitored by the Clinical Effectiveness department and are available on request. The authors have declared no conflicts of interest.

1 Introduction

This tissue pathway addresses the handling of non-neoplastic ophthalmic pathology tissue. The aim of this document is to facilitate and standardise the approach to cut-up, block selection, microtomy and selection of special stains for non-neoplastic ophthalmic tissues. Non-neoplastic ophthalmic specimens can originate from the eyelids, ocular surface, ocular coats, cornea, eyeball (evisceration and enucleation), orbit (including lacrimal gland and optic nerve), lacrimal drainage system and temporal artery.

Temporal artery specimens were comprehensively covered in *Tissue pathways for cardiovascular pathology* and are not included in this document.¹

1.1 Target users and health benefits of this guideline

The target primary users of the tissue pathway are consultant cellular pathologists who routinely report ophthalmic pathology, advanced biomedical scientists engaged in cut-up and reporting, and trainee cellular pathologists.

1.2 Staffing and workload

The key issue of who should report ophthalmic pathology specimens was covered in section 2 of *Guidance for the reporting of ophthalmic pathology specimens*.² This document was created by the College in collaboration with the Royal College of Ophthalmologists.

The diagnostic laboratory should have sufficient pathologists, biomedical scientists and clerical staff to cover all of its functions. In general, staffing levels will follow the workload guidelines of the College. Tissue pathways do not provide detailed guidance for common specimen types.

It is suggested that pathologists:

- participate in auditing
- participate in the College's continuing professional development (CPD) scheme, of which ophthalmic pathology CPD should be a part/whole
- have access to specialist ophthalmic referral opinions (e.g. NSOPS laboratories in Liverpool, London, Manchester and Sheffield)
- participate in an appropriate external quality assessment (EQA) scheme, such as the national ophthalmic pathology EQA scheme.

It is recognised that there is significant overlap between ophthalmic pathology and other areas of pathology. For example, eyelid with dermatopathology; lacrimal gland and drainage apparatus with ear, nose and throat pathology; optic nerve, sheath and optic chiasm with neuropathology; and orbital tissues and bony wall of orbit with soft tissue and osteoarticular pathology.²

Pathologists reporting samples from these sites will not invariably be ophthalmic pathologists and will not necessarily participate in the ophthalmic pathology EQA scheme. However, they should have appropriate experience and should participate in an EQA scheme that is relevant to the samples they report.

1.3 Facilities

The laboratory should:

- be equipped to allow the recommended technical procedures to be performed safely

- be enrolled with United Kingdom Accreditation Service (UKAS) accreditation to ISO 15189 standard
- participate in the UK National External Quality Assessment Services (NEQAS) for cellular pathology technique
- participate in the UK NEQAS for immunocytochemistry and in situ hybridisation (when these techniques are used in the diagnostic pathway)
- have access to light microscopy and commonly used special stains
- have access to immunohistochemistry, including immunofluorescence
- have access to a genetics services
- have access to a microbiology and virology services
- have access to digital photographic equipment
- have access to transmission electron microscopy (EM)
- have access to molecular pathology facilities.

Reports should be held on an electronic database that has facilities to search and retrieve specific data items and is indexed according to SNOMED CT or older versions of SNOMED T, M and P codes.

It is noted, however, that SNOMED is now in a practical transition phase, as part of the intended full implementation by the NHS and Public Health England of SNOMED CT. SNOMED ceased to be licensed by the International Health Terminology Standards Development Organisation from 26 April 2017.

It is acknowledged that existing laboratory information systems may not meet this standard; however, the ability to store data in this way should be considered when laboratory systems are replaced or upgraded.

Workload data should be recorded in a format that facilitates the determination of the resources involved and which, if applicable, is suitable for mapping to Healthcare Resource Groups.

1.4 Specimen submission

Request forms must be completed fully to comply with the specimen acceptance policy. The following information must be supplied:

- patient forename and surname
- date of birth
- NHS number
- patient address
- clinician
- hospital location
- date specimen taken
- high-risk status
- specimen type
- brief relevant clinical information.

For fresh specimens (e.g. frozen sections, cytology or direct immunofluorescence [IF]):

- advance notice of the arrival of fresh specimens and sender contact information is required so late/non-arrival of specimens can be investigated and tracked.
- if rapid paraffin processing (e.g. for delayed reconstruction) is provided, this should be arranged by prior discussion between clinician and laboratory. As with frozen sections, when a verbal report is issued, a written record should be made including exact wording, the recipient and time the report was communicated.
- conjunctival specimens for IF may be received in Michel's transport medium or gel transport tubes. Receipt of fresh conjunctival samples for IF may be acceptable by laboratories located close to ophthalmology services, which can provide delivery immediately after a sample is taken.

Please note that frozen sections and IF cannot be performed on high-risk specimens.

For fixation and containers:

- patient identification and specimen details must be completed on each specimen pot submitted. Multiple specimens from the same patient should be placed in different, individually identified containers and noted on request forms.
- most specimens will require fixation in 10% neutral buffered formalin. The volume of fixative (and therefore size of specimen pot) should be appropriate to the size of specimen.
- for minute biopsies (e.g. retina), it may be more appropriate to place the specimen and formalin within a small container (e.g. Eppendorf tube or similar).

Please also refer to the Royal College of Ophthalmologists' guidance on ophthalmic pathology. This comprehensive document informs the users (ophthalmologists) of an ophthalmic pathology service and the specimens to be submitted for assessment.³

1.5 Specimen dissection

Handling of specimens should be appropriate to the risk category indicated and in line with local guidelines and health and safety regulations.

1.6 Decalcification

For further information, please see *Tissue pathways for bone and soft tissue pathology*.⁴

1.7 Research

Ophthalmic samples may be required for research purposes. In such circumstances where the specimen is required both for diagnostic and research purposes, it is advisable for the ophthalmologist to seek advice from the pathologist involved. It is the responsibility of both the ophthalmologist and pathologist to ensure that the handling of the specimen does not significantly compromise diagnosis. Handling and processing of ophthalmic specimens taken exclusively for research purposes should follow appropriate research protocols.

2 Small lid biopsy

The main indications for eyelid and periocular skin biopsies are: non-pigmented lesions (e.g. cyst, papilloma), differential diagnosis of pigmented lesion, suspected epithelial dysplastic/neoplastic processes, inflammatory/granulomatous lesions (e.g. recurrent chalazion, pyogenic granuloma, inflammatory skin condition, infection) and vascular lesions.⁵

2.1 Specimen submission and dissection

- Specimens should be submitted in formalin.
- Skin ellipses or shaves and incisional biopsies of skin can be handled as standard skin specimens.
- If orientation marks are present, the margins of the specimen should be inked to facilitate histological orientation.
- The presence of the lid margin or tarsal conjunctiva should be noted.

2.2 Sectioning

Sections should be cut at three levels. Some laboratories cut a single level and only cut further levels if there is a clinicopathological conflict or if it is not possible to make a diagnosis from a single haematoxylin and eosin (H&E) stained section.

2.3 Routine staining

H&E staining should be used for initial assessment.

2.4 Further investigations

According to clinical indications or pathological findings, supplementary investigations might include:

- special stains for microorganisms (e.g. Gram, Grocott, Periodic acid–Schiff [PAS], Ziehl–Neelsen [ZN], etc.)
- Congo red, Sirius red or immunohistochemistry for amyloid
- immunohistochemistry for differential diagnosis of unexpected malignancy.

2.5 Report content

The report should include:

- clinical information
- biopsy dimensions and macroscopic description
- microscopic findings
- specific findings or interpretation of findings leading to specific or differential diagnosis
- any recommendation for supra-regional referral
- conclusion
- SNOMED codes.

[Level of evidence – D and GPP.]

3 Full-thickness lid resection

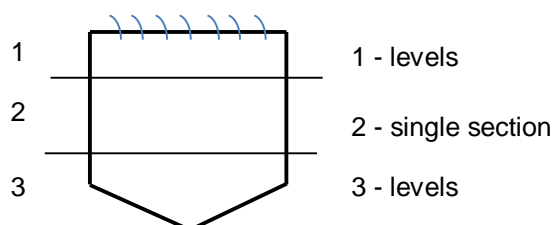
Indication for full-thickness pentagonal/wedge lid resection is predominantly excision of a localised tumour (not covered in this document). However, indication may also include other benign conditions, as mentioned for eyelid skin biopsies, if the lid margin and/or conjunctival aspect is involved.^{5,6}

3.1 Specimen submission and dissection

- Specimens should be received in formalin.
- Correct orientation with identification of cutaneous and conjunctival surfaces is important.
- Dissection protocols may vary among laboratories; however, these should primarily facilitate orientation at embedding and microscopic interpretation. To aid dissection, ink the lateral and medial halves with two different colours. The specimen is then serially sliced parallel to the lid margin (horizontally) in 2–3 mm thick sections. These are embedded on their cut surfaces to allow, whenever required, microscopic measurement of the distance of the lesion to both medial and lateral margins, as these tend to be closest margins in eyelid resections in most surgical protocols. If applicable, margins in the last block (superior margin for upper eyelids or inferior margin for lower eyelids) can be assessed by cutting levels through or re-embedding the tissue turned 180°. Another option for full-thickness lid dissection, depending on the experience of the person assessing the specimen, is to slice in 2–3 mm thick vertical (sagittal) sections. In this case, medial and lateral margins, if applicable, can be assessed by cutting levels through or re-embedding the tissue turned 180°.
- Some laboratories advocate embedding one slice per cassette, while others advocate more than one slice per cassette. This tissue pathway is not prescriptive.
- A diagram or photograph of the specimen indicating the sections taken may be useful for microscopic correlation in complex cases.

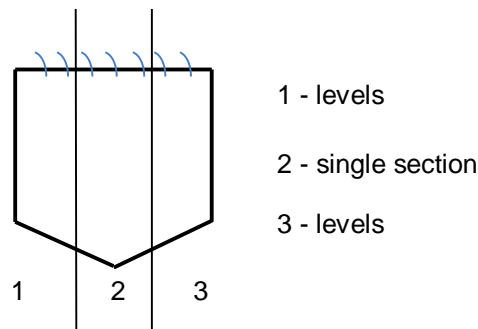
3.2 Sectioning

For specimens sliced horizontally, cut three levels from each outer block (i.e. lid margin and inferior margin for lower eyelid or superior margin for upper eyelid) and a single section from intermediate block, if any. The diagram below is an example of horizontal sectioning on a lower eyelid wedge resection.



Horizontal eyelid sectioning

For specimens sliced vertically, cut three levels from each outer block (i.e. medial and lateral margins) and a single section from each intermediate block, if any. The diagram below is an example of vertical sectioning on a lower eyelid wedge resection.



Vertical eyelid sectioning

It should be noted that some laboratories only cut levels for further clarification of the pathology.

3.3 Routine staining

H&E staining should be used for initial assessment.

3.4 Further investigations

According to clinical indications or pathological findings, supplementary investigations might include:

- special stains for microorganisms (e.g. Gram, Grocott, PAS, ZN)
- elastic van Gieson (EVG)
- Congo red, Sirius red or immunohistochemistry for amyloid
- immunohistochemistry for differential diagnosis of unexpected malignancy.

3.5 Report content

The report should include:

- clinical information
- biopsy dimensions and macroscopic description
- microscopic findings
- interpretation of findings leading to specific or differential diagnosis
- any recommendation for supra-regional referral
- conclusion
- SNOMED codes.

[Level of evidence – C, D and GPP.]

4 Corneal specimens

A wide range of corneal specimens can be submitted for histopathological analysis. These include small/punch biopsies, epithelial scrapings, corneal buttons (anterior/posterior lamellar or penetrating keratoplasties), corneal 'membranes' (endothelial keratoplasty) and donor corneal-scleral specimens.^{5,6}

4.1 Specimen submission and dissection

- Specimens should typically be received in formalin. Please note that fixation in formalin may induce some degree of cloudiness in the specimen.
- In cases of suspected corneal dystrophy or if specimens are required for research purposes, an axial strip can be fixed in glutaraldehyde for EM if indicated.⁷
- Corneal specimens should be handled gently to avoid damage to anterior or posterior surfaces.
- Measure the diameter of the disc/biopsy and describe any variation in overall thickness. In corneal-scleral donor specimens, the width of the attached scleral rim should be measured.
- Macroscopic examination of corneas can be facilitated by using a dissecting microscope against both dark and light backgrounds.
- Corneal discs may contain suture material from previous keratoplasty or local repair. Some specimens may also show peripheral radial marks or a central dot to help orientation for the surgical procedure.
- A description of any of the following should be included:
 - texture of anterior and posterior surfaces
 - any defect, ulceration or perforation including respective location and measurement
 - any opacity, loss of transparency or scars, including distribution, shape, colour and measurements
 - any signs of neovascularisation.
- In most cases, a corneal disc can be bisected through areas of interest and, whenever possible, at right angles to wounds and scars. This can be safely done with the concave posterior surface upwards to minimise any possible artefactual endothelial detachment from Descemet's membrane.
- Both button halves should be embedded on their edges.
- Corneal biopsies can be processed whole and should be embedded on their edges.
- Donor corneal-scleral specimens may or may not include a central defect corresponding to the trephined area. If the cornea or part of it is present, these specimens can be cut in three parallel sections. When only the scleral rim remains, this can be sectioned radially in 4 mm wide pieces to be embedded on their edges.

4.2 Sectioning

Initially three levels should be cut. If pathology is very focal, a more careful stepwise approach may be required and unstained spare sections should be kept. Some laboratories will cut one section and only cut further levels for clarification.

An initial single section is acceptable for scleral rims.

4.3 Routine staining

H&E and PAS staining should be used.

4.4 Further investigations

According to clinical indications or pathological findings, supplementary investigations might include:

- special stains for microorganisms (e.g. Gram, Grocott, Giemsa, ZN, modified ZN; a modified ZN also permits the detection of *Nocardia* and microsporidia)
- immunohistochemistry/polymerase chain reaction (PCR) for herpes simplex virus I and II
- Alcian blue for mucopolysaccharide deposits⁸
- Masson's trichrome for differential diagnosis of granular/keratohyaline deposits⁸
- Congo red, Sirius red or immunohistochemistry for amyloid deposits⁸
- von Kossa for suspected dystrophic calcification
- Perls' for haemosiderin or Fleischer rings
- immunohistochemistry (cytokeratins) for suspected posterior polymorphous dystrophy
- immunohistochemistry (e.g. CK3, CK19, CK7, CK12, CK13) for suspected limbal stem cell deficiency
- transmission EM (in some instances EM may be indicated for confirmation of a rare dystrophy or an unusual microorganism [e.g. microsporidium]).⁷

4.5 Report content

The report should include:

- clinical information
- biopsy dimensions and macroscopic description
- microscopic findings
- interpretation of findings leading to specific or differential diagnosis
- any recommendation for supra-regional referral (expert opinion or further tests [e.g. EM, PCR] if not available locally)
- conclusion
- SNOMED codes.

[Level of evidence – C, D and GPP.]

5 Conjunctival biopsies

The main indications for non-neoplastic conjunctival biopsies are:

- non-pigmented lesions (e.g. pterygium/pingueculum, cyst, dermoid/choristoma)
- inflammatory lesions (infectious or non-infectious), including ocular cicatricial pemphigoid
- differential diagnosis of lymphoid lesions.⁵

Caruncular biopsies can also be performed for pigmented or non-pigmented lesions and suspected neoplasia. Incisional mapping conjunctival biopsies consist of multiple biopsies usually performed to estimate the extent of a melanocytic or epithelial intraepithelial neoplasia.^{5,6}

5.1 Specimen submission and dissection

- Specimens should typically be received in formalin, except those for direct IF, which should be received fresh or in an appropriate transport medium (see section 1.4).
- Conjunctival specimens are usually very thin and as such tend to curl. This can be minimised by laying the biopsies on a piece of sponge or card immediately after being taken to allow them to fix flattened.
- Macroscopic examination should include measurements and a description of any visible abnormality.
- Margins of excisional conjunctival or caruncular biopsies with appropriate clinically indicated orientation should be inked whenever practical.
- Excisional specimens (usually larger than 6 mm in their long axis) should be serially sliced perpendicular to the long axis. Each slice should then be embedded on its cut surface.
- Small biopsies can be processed whole and embedded on their longest edge.
- Samples for direct IF should be embedded whole in freezing mount on their longest axis.^{9,10}

5.2 Sectioning

For processed and paraffin-embedded tissue, cut three to four levels. Some laboratories cut just one section initially, with further levels cut later if required for clarification.

For frozen samples for direct IF, cut one or two sections per slide.

5.3 Routine staining

H&E staining should be used for initial assessment of all sample types. The following antibodies can be used on frozen samples for direct IF: IgA, IgG, IgM, C3c and fibrinogen.

5.4 Further investigations

According to clinical indications or pathological findings, supplementary investigations might include:

- PAS for assessment of basement membranes and goblet cells
- special stains for microorganisms (Gram, PAS, Grocott, ZN)
- EVG
- Congo red, Sirius red or immunohistochemistry for amyloid
- Masson-Fontana
- immunohistochemistry for differential diagnosis of unexpected malignancy.

5.5 Report content

The report should include:

- clinical information
- biopsy dimensions and macroscopic description
- microscopic findings (with correlation with respective location for mapping biopsies)
- interpretation of findings leading to specific or differential diagnosis
- any recommendation for supra-regional referral (for expert opinion or further tests [e.g. cytogenetics, direct IF] if not available locally)
- conclusion
- SNOMED codes.

[Level of evidence – D and GPP.]

6 Trabecular meshwork

6.1 Specimen submission and dissection

Trabecular meshwork samples are usually submitted for histopathological analysis for research purposes. The following instructions are suggested:

- fix in formalin
- macroscopic examination may require magnification. Most samples contain scleral tissue only. If present, the outflow system is usually pigmented. Any attached ciliary muscle may aid orientation.
- the specimen can be bisected perpendicularly to the trabecular meshwork.⁶

6.2 Sectioning

Cut ten serial sections mounted on five slides.⁶

6.3 Routine staining

Stain three out of five slides with H&E. Keep two slides unstained ready for further investigation with special stains. Research cases typically follow respective protocol.⁶

6.4 Further investigations

Further investigations might include:

- special stains if suspected extracellular material (Masson Trichrome, EVG, Alcian blue, PAS)
- transmission EM.⁶

6.5 Report content

The report should include:

- clinical information
- biopsy dimensions and macroscopic description

- microscopic findings
- interpretation of findings
- any recommendation for supra-regional referral
- conclusion
- SNOMED codes.

[Level of evidence – C and D.]

7 Iris, ciliary body and choroid^{5,11}

7.1 Specimen submission and dissection

The main indications for a non-neoplastic iris, ciliary body or choroidal/retino-choroidal biopsy are cysts, glaucoma-associated anterior chamber syndromes (essential iris atrophy and iridocorneal endothelial syndrome) and infectious and non-infectious inflammatory pathologies.

The biopsies should generally be fixed in formalin. However, if there is a suspected viral aetiology (e.g. viral retino-choroiditis), a small piece needs to be fixed in glutaraldehyde for transmission EM. For any suspected infectious case, clinicians must send material for microbiology (culture, PCR/molecular testing) before fixing the specimen.

These biopsies are quite small and should be placed into sterile Eppendorf tubes containing formalin in theatre rather than standard formalin pots.

After a description has been taken, the biopsies should be wrapped carefully in paper and placed in a nylon tissue bag, biopsy wrap or cell-safe capsule, to minimise risk of loss during processing.^{5,11}

7.2 Sectioning

Serial sections or close levels with many spares in between are recommended to ensure focal pathology is not missed.^{5,11}

7.3 Routine staining

H&E staining should be used.

7.4 Further investigations

Further investigations might include:

- Gram (bacteria)
- PAS and Grocott (fungi and parasites; macrophages containing liquefied lens material-phacogenic uveitis; vacuolated iris pigment epithelium and thickened ciliary body basement membrane in diabetes; exfoliation material)
- Congo red, Sirius red or immunohistochemistry (amyloid)
- modified ZN (mycobacteria and *Nocardia*)
- Warthin-Starry (spirochetes)
- Perls' (haemorrhage)

- immunohistochemistry for viruses (herpes virus family)
- PCR on paraffin sections (for infectious agent speciation)
- transmission EM (for infectious agents mainly).^{5,11}

7.5 Report content

The report should include:

- clinical information
- biopsy dimensions and macroscopic description
- microscopic findings
- interpretation of findings
- any recommendation for supra-regional referral
- conclusion
- SNOMED code.

[Level of evidence – C and D.]

8 Lens

8.1 Specimen submission and dissection

The natural lens is rarely submitted, but may be for congenital, traumatic, metabolic or infectious aetiologies, or suspected heavy metal deposition. Natural lens fragments should be fixed in formalin ± glutaraldehyde if transmission EM is required. The lens may be received as fragments in a bag, containing balanced salt solution, post-phacoemulsification. Fixative can be poured into the bag to fix the fragments.

Intraocular lenses (IOL) may be submitted when there have been issues with mechanical trauma, inflammation, infection, wrong power or decentration. IOL should be submitted in formalin and their make should be identified (clinical notes or IOL catalogue). Note the integrity of the optics and haptics, and the colour and distribution of any opacification.¹²⁻¹⁴

8.2 Sectioning

For natural lens tissue, cut three levels. Some laboratories cut only one level initially.¹²⁻¹⁴

8.3 Routine staining

For natural lens tissue, H&E and PAS should be used. IOL can be stained whole with H&E. IOL can be whole mounted on a glass slide with a well using aqueous medium and coverslipped. This technique allows cellular material to be assessed clearly.¹²⁻¹⁴

8.4 Further investigations

Further investigations might include:

- Gram, PAS, Grocott, ZN and Wade-Fite if infection is suspected. The whole mounted IOL can be removed, decolourised of H&E and re-stained.
- PAS for lens-induced uveitis (macrophages with eosinophilic liquified lens contents), membranes surrounding IOL and exfoliation syndrome

- Alizarin red or von Kossa for mineralisation of IOL
- Perls' for siderosis lentis
- copper stains for chalcosis lentis
- transmission EM (especially for Alport's syndrome)
- scanning EM (for IOL).

8.5 Report content

The report should include:

- clinical information
- biopsy dimensions and macroscopic description
- microscopic findings
- interpretation of findings
- any recommendation for supra-regional referral
- conclusion
- SNOMED codes.

[Level of evidence – D.]

9 Vitreous specimens and cytology

9.1 Specimen submission and dissection

It is not necessary to submit vitrectomy material for histological or cytological examination if the clinical indication for surgery is removal of opacities (e.g. vitreous haemorrhage) or in the course of retinal detachment surgery. If the clinical presentation is unusual, non-neoplastic samples might occasionally be submitted for assessment of pathologies, including haemorrhage, amyloid, asteroid hyalosis and inflammation (whether infectious or non-infectious).

A vitreous biopsy is most commonly obtained as a tap (when it may be submitted in a syringe) or as a vitrectomy specimen (when it may be submitted in a cassette or bag, or decanted into a pot). Vitreous taps are often received in a capped syringe or a universal tube. Depending on local agreement, they may be submitted fixed or unfixed. If the latter, fixative can be added in the laboratory. Diagnostic vitrectomy specimens are often received in a vitrectomy bag or cassette, or decanted into a pot. They may be received fixed or unfixed. If the latter, fixative can be added in the laboratory. If infection is suspected, ophthalmologists should be advised to send material for appropriate microbiological investigations before fixation.

Anterior chamber (aqueous) aspirates might occasionally be submitted for evaluation of haemorrhage or inflammation. Anterior chamber aspirates are very small in volume and are often submitted in a syringe.

Fixation methods will depend on local cytology protocols and requirements, for example ancillary investigations. The volume of the fluid should be recorded and any tissue fragments noted. Fragments can be removed, fixed in formalin and processed to paraffin wax.¹⁵

9.2 Sectioning

There are several methods for preparing specimens. The two most common are cytopspins and cell blocks. Cytopspins are prepared onto glass slides and cell blocks are processed to paraffin wax. As the material is usually limited, serial sections and spares should be cut.¹⁵

9.3 Routine staining

H&E or Giemsa should be used (depending on method of preparation).¹⁵

9.4 Further investigations

According to clinical indications or morphological findings, supplementary investigations might include:

- Congo red for amyloid (the National Amyloidosis Centre, Royal Free Hospital, can undertake subtyping)
- special stains for pigment (Perls', Masson-Fontana)
- special stains for microorganisms (Gram, PAS, silver stains, [modified] ZN, Warthin-Starry)
- specific immunohistochemistry, PCR or transmission EM for certain infectious organisms.¹⁵

9.5 Report content

The report should include:

- clinical information
- specimen volume and presence of fragments
- microscopic findings
- interpretation of findings
- any recommendation for supra-regional referral (especially for further investigations that are not available locally)
- conclusion
- SNOMED codes.

[Level of evidence – D.]

10 Epiretinal membranes

10.1 Specimen submission and dissection

It is not usually necessary to submit epiretinal membranes for histological examination. On the occasions when a specimen is submitted, it is likely to be extremely small. The specimen should be submitted in formalin in an appropriately sized receptacle. An Eppendorf or similarly sized tube allows the specimen to be easily seen. The specimen may be stained blue during the biopsy procedure. If not, a small drop of Alcian blue or similar dye may be added to aid visualisation. Identify and measure the specimen (it may be fragmented). Specimen wrap paper will help to ensure the specimen remains in the cassette. If the specimen is not identified within the receptacle including its lid, the formalin can be spun down and handled as cytology.⁵

10.2 Sectioning

Cut serial sections with spares.⁵

10.3 Routine staining

H&E and PAS should be used.⁵

10.4 Further investigations

Depending on the clinical question, immunohistochemistry may be used to highlight constituent cells, including: CK7 (for retinal pigment epithelium [RPE]), CD34 (for new vessels), CD68 (macrophages and RPE), glial fibrillary acidic protein and smooth muscle actin.⁵

10.5 Report content

The report should include:

- clinical information
- specimen dimensions
- microscopic findings
- interpretation of findings
- conclusion
- SNOMED codes.

[Level of evidence – D and GPP.]

11 Eucleations

11.1 Specimen submission and dissection

Please note this protocol does not cover paediatric suspected non-accidental injury cases. Specimens should be fixed in formalin for at least 24 hours prior to dissection. The specimen should not be opened or injected with formalin in an attempt to improve fixation.

The following process should be followed:

- orientate the eye: on inspecting the posterior aspect of the globe, the optic nerve lies medially to the inferior oblique muscle insertion. The superior oblique muscle tendinous insertion lies superiorly. It may not be possible to orientate a traumatised or phthisical (shrunken and scarred) globe.
- measure the globe in three dimensions: anteroposterior, horizontal and vertical. Typical measurements of each are approximately 22–24 mm. There may be focal or generalised distortion or discolouration, as well as features of previous surgery (e.g. filtering blebs) or trauma.
- measure the cornea horizontally (typically 12 mm) and vertically (typically 11 mm). Note any opacities.
- note the pupil shape (round, oval, irregular) and size. The view may be obscured by corneal opacity or blood in the anterior chamber.

- note the length of the optic nerve. If length allows, sample the cut end so a transverse section can be assessed. Inking of the (remaining) cut end helps to identify it during microtomy.
- sample the vortex veins, in case of unsuspected intraocular malignancy.
- transilluminate through the cornea/pupil to identify potential intraocular masses. This step helps to inform decisions about how to slice the globe.
- if no focal pathology is identified on transillumination, the eye can be opened horizontally so macular histology can be assessed. Otherwise, vertical or oblique cuts can be made to produce the calottes (caps).
- take the calottes by making two parallel anteroposterior slices, one on either side of the cornea and optic nerve. A skin graft or similar blade is useful to achieve a smooth cut. The non-calotte portion is the 'main block' or 'PO block'.
- the main block of an enucleation specimen should include cornea, pupil, optic nerve and representative pathology.
- examine the interior of the eye. Note any shallowing of the anterior chamber, masses, haemorrhage or retinal detachment. A crystalline lens may be present, or an IOL.
- the main block will probably require a deep or large cassette and mould. The calottes may be processed if they show macroscopic pathology.^{6,16-18}

11.2 Sectioning

The main block may require three to five levels before the pupil and optic nerve are reached. Sufficient levels should be cut in the main block (and calottes, if processed) to demonstrate the findings specific to the case.^{6,16-18}

11.3 Routine staining

H&E and PAS should be used. The latter is especially useful to demonstrate Descemet's membrane, lens capsule, the retinal inner limiting membrane and Bruch's membrane, especially if the structures are distorted.^{6,16-18}

11.4 Further investigations

Further investigations will depend on clinical context and microscopic findings. They might include:

- special stains for microorganisms (Gram, Grocott, [modified] ZN)
- Perls' for iron if there is current or old haemorrhage
- immunohistochemistry for reactive proliferations or suspected tumours
- CD68 may be helpful to define granulomas if sympathetic endophthalmitis is suspected.^{6,16-18}

11.5 Report content

The report should include:

- clinical information
- globe, cornea and optic nerve macroscopic dimensions
- microscopic findings

- interpretation of findings (neoplasia or sympathetic endophthalmitis are of particular concern)
- any recommendation for supra-regional referral (especially for further investigations that are not available locally)
- conclusion
- SNOMED codes.

[Level of evidence – C, D and GPP.]

12 Eviscerations

12.1 Specimen submission and dissection

The specimen usually includes cornea with a rim of sclera as well as the intraocular contents. The specimen may be heavily calcified.

The following process should be followed:

- fix in formalin for at least 24 hours.
- measure any corneoscleral button. Note obvious pathology such as opacity, perforation, scars or sutures. Slice into three or four pieces to allow for embedding on edge.
- measure the intraocular contents. They may be submitted as a sac or as piecemeal haemorrhagic and membranous fragments. Slice any sac. Note the constituents, e.g. retina, vitreous, crystalline lens or IOL and uveal tissue. There may be oil post-vitrectomy.
- all tissue should be submitted. It may be easier to place the cornea in its own cassette.
- process any IOL. It can be cut without damage to the microtomy blade.^{5,16}

12.2 Sectioning

Depending on the clinical information, a single section or three levels may be cut initially.^{5,16}

12.3 Routine staining

H&E and PAS should be used.^{5,16}

12.4 Further investigations

Further investigations will depend on clinical information and findings on initial microscopy. They might include:

- special stains for microorganisms (Gram, Grocott, ZN, etc.)
- Perls' for old haemorrhage
- immunohistochemistry for unexpected tumour. CD68 may help to identify granulomatous inflammation if sympathetic endophthalmitis is suspected.^{5,16}

12.5 Report content

The report should include:

- clinical information
- specimen dimensions
- microscopic findings
- interpretation of findings (specific mention should be made of any tumour or sympathetic endophthalmitis)
- conclusion
- SNOMED codes.

[Level of evidence – D and GPP.]

13 Orbital and lacrimal gland biopsies^{6,17}

13.1 Specimen submission and dissection

Non-neoplastic orbital biopsies are often received for investigation of inflammatory disease. Dermoid cysts may also occur.

The following process should be followed:

- fix in formalin at least overnight or for longer if the specimen is large.
- measure the specimen in three dimensions. Piecemeal specimens may be measured in aggregate.
- provide a description, which may include texture, colour and any cyst contents.
- a discrete specimen may be inked if there is the possibility of neoplasia. Slice if required.^{6,17}

13.2 Sectioning

Depending on clinical information and specimen size, a single section or three levels may be taken. If the specimen is very small, spare unstained sections may be kept.^{6,17}

13.3 Routine staining

H&E should be used.

13.4 Further investigations

Further investigations will depend on clinical information and microscopic appearance. They might include:

- special stains for microorganisms (Gram, ZN, PAS, Grocott, etc.)
- Congo red for amyloid
- immunohistochemistry for suspected IgG4-related disease or myositis.

13.5 Report content

The report should include:

- clinical information
- specimen dimensions
- microscopic findings
- interpretation of findings
- any recommendation for supra-regional referral (e.g. for further assessment of amyloid)
- conclusion
- SNOMED codes.

[Level of evidence – D and GPP.]

14 Orbital exenteration

14.1 Specimen submission and dissection

Non-neoplastic orbital exenterations are usually performed for intractable symptoms such as chronic inflammation and/or fibrosis, or occasionally for infections. An exenteration includes the globe (if present) as well as orbital soft tissue and eyelids. A lid-sparing exenteration will leave eyelid tissue (usually skin) behind to aid reconstructive surgery. Some exenterations include the orbital bone.

The following process should be followed:

- fix in an adequate volume of formalin: this is likely to be more than for other ophthalmic specimens. 48 hours should be sufficient.
- orientate the specimen: the caruncle and puncta lie medially. The upper lid is longer than the lower lid, and it usually has a horizontal skin crease and longer lashes. The cut end of the optic nerve should be visible posteriorly, although it may be hidden within the orbital fat.
- measure the specimen in three dimensions: anteroposterior, horizontal and vertical.
- note the amount of lid skin and optic nerve.
- check for the presence of the globe and note any obvious abnormalities (e.g. rupture, adhesions).
- note any obvious soft tissue abnormalities, e.g. masses or fibrosis
- if bone is included in the specimen, consider removing it and processing it separately, after decalcification.
- paint the external surface. Different colours, for example for the superior and inferior surfaces, will aid microscopic orientation.
- the specimen is typically breadsliced sagittally from medial to lateral (or vice versa). The middle blocks will contain the globe. The lacrimal gland will be present in a more lateral block superiorly, with the lacrimal sac (if included) in a more medial block inferiorly.
- note the appearance of the cut surface, e.g. scarring, haemorrhage, abscess and any globe disruption or intraocular abnormalities.
- if available, large blocks should be used so the slices can be processed and sectioned whole.^{6,17}

14.2 Sectioning

Ensure that full faces are achieved.^{6,17}

14.3 Routine staining

H&E and PAS should be used. PAS is useful for evaluation of the globe.

14.4 Further investigations

These will depend on clinical information and findings on initial microscopy, and might include:

- special stains for microorganisms (Gram, PAS, Grocott, ZN, etc.)
- Congo red for amyloid
- immunohistochemistry for suspected tumours or possible IgG4-related disease.^{6,17}

14.5 Report content

The report should include:

- clinical information
- specimen dimensions
- microscopic findings
- interpretation of findings
- any recommendation for supra-regional referral (e.g. for further assessment of amyloid)
- conclusion
- SNOMED codes.

[Level of evidence – D and GPP.]

15 Impression cytology

15.1 Specimen submission

Impression cytology specimens may be submitted as an investigation for suspected limbal stem cell deficiency. Sampling is generally by means of a commercially available disc/membrane received attached to a plastic ring. The specimen should be fixed in formalin overnight.¹⁹

15.2 Sectioning

No sectioning is required. The disc is removed from its plastic ring and mounted whole (*en face*) onto the glass slide.¹⁹

15.3 Routine staining

Dual immunohistochemistry for corneal cells (CK3 and CK12) and conjunctival cells (CK13 and CK19) can be performed on a single disc. PAS stain can be used if immunohistochemistry is not available, or if two discs are submitted.¹⁹

15.4 Report content

The report should include:

- clinical information
- microscopic findings (cellularity, cell size, presence of goblet cells and immunohistochemical pattern)
- interpretation of findings (specifically, whether the appearance supports conjunctivalisation or not)
- conclusion
- SNOMED codes.

[Level of evidence – D.]

16 Lacrimal sac biopsies/excision

16.1 Specimen submission and dissection

The specimen may be lacrimal sac contents (e.g. a dacryolith), a biopsy of the sac wall or a lacrimal sac excision (i.e. dacryocystectomy). The specimen should be fixed in formalin for 24 hours and measured, in aggregate if piecemeal. Wall biopsies and dacryoliths do not usually require slicing. A sac can be breadsliced to reveal the lumen.⁶

16.2 Sectioning

A single section or three levels may be taken.⁶

16.3 Routine staining

H&E should be used.

16.4 Further investigations

This might include special stains for microorganisms (Gram, Grocott, PAS, etc.).⁶

16.5 Report content

The report should include:

- clinical information
- specimen dimensions
- microscopic findings
- interpretation of findings
- conclusion
- SNOMED codes.

[Level of evidence – D.]

17 Criteria for audit

As recommended by the RCPATH as key performance indicators (see *Key Performance Indicators – Proposals for implementation*, July 2013, www.rcpath.org/profession/quality-improvement/kpis-for-laboratory-services.html):

- histopathology cases must be reported, confirmed and authorised within seven and ten calendar days of the procedure.
 - standard: 80% of cases should be reported within seven calendar days and 90% reported within ten calendar days.

18 References

1. Suvarna K, Rassl DM, Neil D. *Tissue pathways for cardiovascular pathology*. London, UK: The Royal College of Pathologists, 2018. Available at: www.rcpath.org/profession/guidelines/cancer-datasets-and-tissue-pathways.html
2. The Royal College of Pathologists and The Royal College of Ophthalmologists. *Guidance for the reporting of ophthalmic pathology specimens*. London, UK: The Royal College of Pathologists, 2015. Available at: www.rcpath.org/uploads/assets/adc5e0d7-16d5-4b8e-9e90db6961f2a540/Guidance-for-the-reporting-of-ophthalmic-pathology-specimens.pdf
3. The Royal College of Ophthalmologists. *Ophthalmic Service Guidance: Ophthalmic Pathology*. London, UK: The Royal College of Ophthalmologists, 2016. Available at: www.rcophth.ac.uk/wp-content/uploads/2016/07/Ocular-Pathology-July-2016.pdf
4. Mangham DC, Freemont AJ. *Tissue pathways for bone and soft tissue pathology*. London, UK: The Royal College of Pathologists, 2016. Available at: www.rcpath.org/profession/guidelines/cancer-datasets-and-tissue-pathways.html
5. Ford AL, Mudhar HS, Farr R, Parsons MA. The ophthalmic pathology cut-up – Part 2. *Curr Diagn Pathol* 2005;11:340–348.
6. Roberts F, Thum CK. *Lee's Ophthalmic Histopathology*. London, UK: Springer Science & Business Media, 2014.
7. Vemuganti GK, Rathi VM, Murthy SI. Histological landmarks in corneal dystrophy: Pathology of corneal dystrophies. In: Lisch W, Seitz B (eds). *Corneal Dystrophies*. Basel, Switzerland: Karger, 2011;48:24–50.
8. Weiss JS, Moller HU, Aldave AJ, Seitz B, Bredrup C, Kivela T *et al*. IC3D classification of corneal dystrophies – edition 2. *Cornea* 2015;34:117–159.
9. Leonard JN, Hobday CM, Haffenden GP, Griffiths CE, Powles AV, Wright P *et al*. Immunofluorescent studies in ocular cicatricial pemphigoid. *Br J Dermatol* 1988;118:209–217.
10. Power WJ, Neves RA, Rodriguez A, Dutt JE, Foster CS. Increasing the diagnostic yield of conjunctival biopsy in patients with suspected ocular cicatricial pemphigoid. *Ophthalmology* 1995;102:1158–1163.
11. Eagle R Jr. Specimen handling in the ophthalmic pathology laboratory. *Ophthalmol Clin North Am* 1995;8:1–15.
12. Champion R, McDonnell PJ, Green WR. Intraocular lenses. Histopathologic characteristics of a large series of autopsy eyes. *Surv Ophthalmol* 1985;30:1–32.
13. Champion R, Green WR. Intraocular lenses: a histopathologic study of eyes, ocular tissues, and intraocular lenses obtained surgically. *Ophthalmology* 1985;92:1628–1645.
14. Carlson AN, Stewart WC, Tso PC. Intraocular lens complications requiring removal or exchange. *Surv Ophthalmol* 1998;42:417–440.
15. Coupland SE. Analysis of intraocular biopsies. *Dev Ophthalmol* 2012;49:96–116.
16. Azari AA, Syed NA, Albert DM. Examining and processing eye specimens. *Methods Mol Biol* 2014;1180:377–396.

17. Ford AL, Mudhar HS, Farr R, Parsons MA. The ophthalmic pathology cut-up – Part 1: The enucleation and exenteration specimen. *Curr Diagn Pathol* 2005;11:284–290.
18. Eagle RC. *Eye pathology: an atlas and text*. Philadelphia, PA, USA: Lippincott Williams & Wilkins, 2011.
19. Calonge M, Diebold Y, Saez V, Enriquez de Salamanca A, Garcia-Vazquez C, Corrales RM *et al*. Impression cytology of the ocular surface: a review. *Exp Eye Res* 2004;78:457–472.

Appendix A **Summary table – explanation of grades of evidence**
(modified from Palmer K *et al. BMJ* 2008;337:1832)

Grade (level) of evidence	Nature of evidence
Grade A	<p>At least one high-quality meta-analysis, systematic review of randomised controlled trials or a randomised controlled trial with a very low risk of bias and directly attributable to the target cancer type</p> <p>or</p> <p>A body of evidence demonstrating consistency of results and comprising mainly well-conducted meta-analyses, systematic reviews of randomised controlled trials or randomised controlled trials with a low risk of bias, directly applicable to the target cancer type.</p>
Grade B	<p>A body of evidence demonstrating consistency of results and comprising mainly high-quality systematic reviews of case-control or cohort studies and high-quality case-control or cohort studies with a very low risk of confounding or bias and a high probability that the relation is causal and which are directly applicable to the target cancer type</p> <p>or</p> <p>Extrapolation evidence from studies described in A.</p>
Grade C	<p>A body of evidence demonstrating consistency of results and including well-conducted case-control or cohort studies and high-quality case-control or cohort studies with a low risk of confounding or bias and a moderate probability that the relation is causal and which are directly applicable to the target cancer type</p> <p>or</p> <p>Extrapolation evidence from studies described in B.</p>
Grade D	<p>Non-analytic studies such as case reports, case series or expert opinion</p> <p>or</p> <p>Extrapolation evidence from studies described in C.</p>
Good practice point (GPP)	<p>Recommended best practice based on the clinical experience of the authors of the writing group.</p>

Appendix B AGREE II guideline monitoring sheet

The tissue pathways of the Royal College of Pathologists comply with the AGREE II standards for good quality clinical guidelines. The sections of this tissue pathway that indicate compliance with each of the AGREE II standards are indicated in the table.

AGREE standard	Section of guideline
Scope and purpose	
1 The overall objective(s) of the guideline is (are) specifically described	Introduction
2 The health question(s) covered by the guideline is (are) specifically described	Introduction
3 The population (patients, public, etc.) to whom the guideline is meant to apply is specifically described	Foreword
Stakeholder involvement	
4 The guideline development group includes individuals from all the relevant professional groups	Foreword
5 The views and preferences of the target population (patients, public, etc.) have been sought	Foreword
6 The target users of the guideline are clearly defined	1
Rigour of development	
7 Systematic methods were used to search for evidence	Foreword
8 The criteria for selecting the evidence are clearly described	Foreword
9 The strengths and limitations of the body of evidence are clearly described	Foreword
10 The methods for formulating the recommendations are clearly described	Foreword
11 The health benefits, side effects and risks have been considered in formulating the recommendations	Foreword and Introduction
12 There is an explicit link between the recommendations and the supporting evidence	2–16
13 The guideline has been externally reviewed by experts prior to its publication	Foreword
14 A procedure for updating the guideline is provided	Foreword
Clarity of presentation	
15 The recommendations are specific and unambiguous	2–16
16 The different options for management of the condition or health issue are clearly presented	2–16
17 Key recommendations are easily identifiable	2–16
Applicability	
18 The guideline describes facilitators and barriers to its application	Foreword
19 The guideline provides advice and/or tools on how the recommendations can be put into practice	2–16
20 The potential resource implications of applying the recommendations have been considered	Foreword
21 The guideline presents monitoring and/or auditing criteria	17
Editorial independence	
22 The views of the funding body have not influenced the content of the guideline	Foreword
23 Competing interest of guideline development group members have been recorded and addressed	Foreword